



**PATIENT**

Tiddles Williams

**SPECIES**

Feline

**BREED**

DSH

**SEX**

NM

**AGE**

8Y

**WEIGHT**

11.8 lbs.

**INTERPRETED BY**

R. McKenzie Daniel,  
DVM, DABVP  
(Canine and Feline)

**IMAGING PERFORMED BY**

Dr. Rivera

**HOSPITAL NAME**

DPC VH

**REFERRING VET**

Dr. Rivera

**INVOICE**

14670

**DATE**

8/24/22

**PRESENTING CLINICAL SIGNS**

Reason for Visit: exam + follow up from ER History: Patient was presented at AVCC for urinary issues that have been going on for months with lethargy. Performed x-rays, UA and BW. Assessment: "stranguria secondary to cystic calculi". O declined sx at AVCC, wishes to have sx done here. Currently, P is not doing well per O. He is very lethargic (gabapentin?), laying in places he normally wouldn't (behind boxes and in wet shower). O says P is constantly in his box, urination patterns described as "2 little drops" then going in/out of box. New behavior is that P is kicking litter around. Has been having lower urinary signs on and off for months X-rays from advanced - single small bladder stone Labwork: SDMA 15 (suspect prerenal) otherwise unremarkable. UA: USG 1.055, TNTC RBC's, increased WBC's no bacteria  
Abnormal PE/Chem/CBC/UA Results: 8/23/22 labs - SDMA/Pre-anesthetic chem - elevated SDMA 24 ug/dl /BUN 57 mg/dl /Creat 3.6 mg/dl- r/o urinary obstruction and dehydration T4 WNL 0.9  
8/24/22 - SDMA 26 ug/dl /BUN 59 mg/dl /Creat 3.4 mg/dl

**ULTRASONOGRAPHIC EXAMINATION OF THE URINARY SYSTEM**

The urinary bladder was subnormal in size owing to a lack of urine distention. Sonographic evaluation of the urinary bladder walls was limited owing to lack of urine distention, yet subjective generalized thickened urinary bladder walls were present. The ventral urinary bladder wall measured 0.60 cm in width. Maintained homogeneous urinary bladder mural echogenicity was noted. A solitary cystic calculus measuring approximately 0.75 cm in diameter was present in the urinary bladder lumen, along with suspected pinpoint, dependent mineral. No overt evidence of neoplastic criteria was noted. The urethra exhibited overtly normal structure and tone to a depth of 2.0 cm.

Normal size and margination were present in the kidneys. A normal 1:3 cortex / medulla ratio and normal corticomedullary definition were maintained. The echogenicity of the cortex was similar to or slightly less than normal liver parenchyma while the medulla echogenicity was hypoechoic to the cortex with no evidence of pyelectasia or hydronephrosis. The left kidney measured 4.3 cm in length. The right kidney measured 4.1 cm in length.

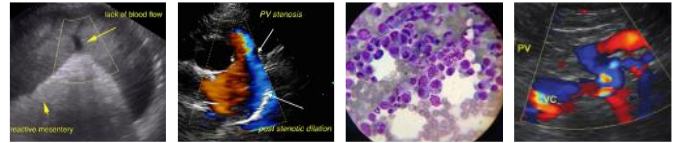
**ULTRASONOGRAPHIC FINDINGS**

- Cystic calculus and concurrent luminal mineral with likely chronic cystitis
- Normal bilateral kidneys

**INTERPRETATION OF THE FINDINGS & FURTHER RECOMMENDATIONS**

Cystostomy with removal of the cystic calculus, urinary bladder flush, +/- urinary bladder mural biopsies for histopathology and tissue C/S with concurrent urine C/S on a sterile urine sample is recommended. No overt evidence of structural renal pathology or left or right ureter obstruction was noted.

Stabilization of renal parameters with pre-operative IV fluids and reassessment of the degree of azotemia prior to surgery, could be considered.



**PATIENT**

Tiddles Williams

**SPECIES**

Feline

**BREED**

DSH

**SEX**

NM

**AGE**

8Y

**WEIGHT**

11.8 lbs.

**INTERPRETED BY**

R. McKenzie Daniel,  
DVM, DABVP  
(Canine and Feline)

**IMAGING PERFORMED BY**

Dr. Rivera

**HOSPITAL NAME**

DPC VH

**REFERRING VET**

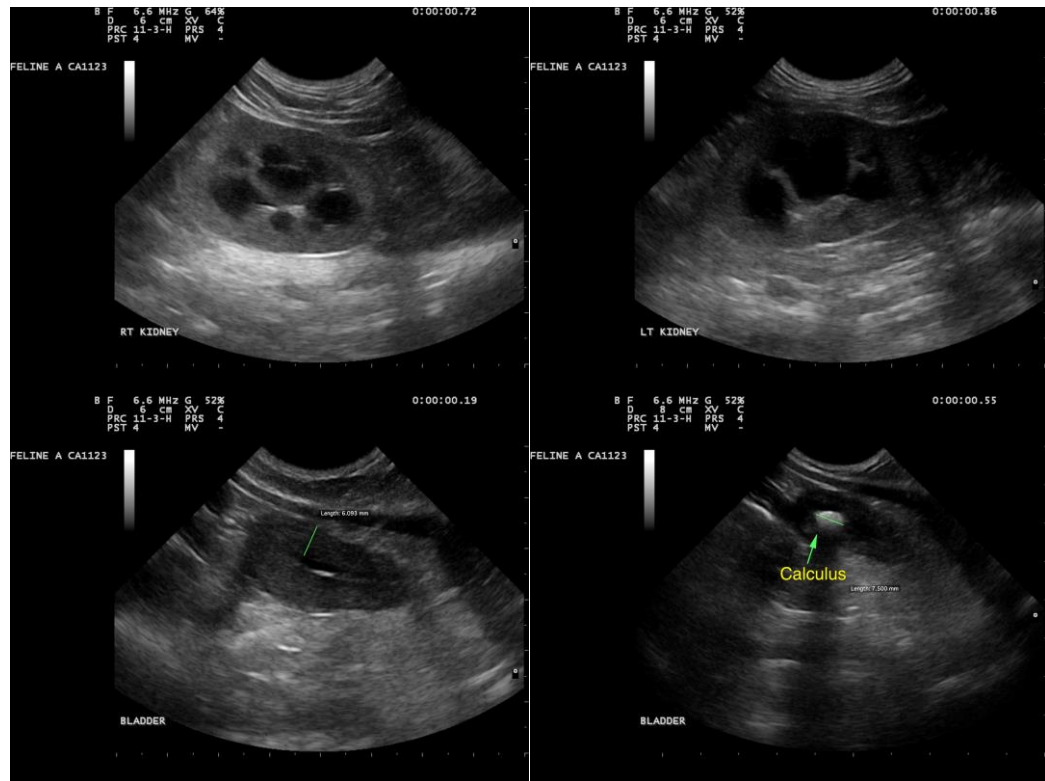
Dr. Rivera

**INVOICE**

14670

**DATE**

8/24/22



**The information and recommendations provided are based on the images presented by the referring veterinarian/sonographer. No evaluation can be communicated regarding pathology that was not visible in the image/video clips provided.**

Thank you for this referral. If the clinical or image interpretation does not parallel your findings or if I can be of any further assistance please contact me.

**R. McKenzie Daniel, DVM, DABVP (Canine / Feline Practice)**  
info@SonoPath.com