

**PATIENT**

Marcus Harmon

**SPECIES**

Canine

**BREED**

Lab Mix

**SEX**

NM

**AGE**

13 years

**WEIGHT**

75 lbs.

**INTERPRETED BY**R. McKenzie Daniel,  
DVM, DABVP  
(Canine and Feline)**IMAGING  
PERFORMED BY**

Sarah Pender, CVT

**HOSPITAL NAME**

SVS Imaging QC

**REFERRING VET**

Dr. Grace Zhang

**INVOICE**

14692

**DATE**

8/24/22

**PRESENTING CLINICAL SIGNS**

8/10/22 presenting for blood at end of urine stream. Acting normally.

Abnormal PE/Chem/CBC/UA Results: Urinalysis: pH9; USG 1.033; large amount of leukocytes and blood, moderate protein; on dry mount slide, epithelial cells, cocci &amp; struvite crystals present.

Nonpainful on abdominal palpation. Being boarded the next day, so Owner wanted to have checked out and sent to boarding with medications if needed. Dispensed Clavamox 562.5mg BID for 5 days.

On 8/22/22: Owner came back, picked Marcus up from boarding and noticed seemed to have urgent urination &amp; blood tinged urine. Assuming boarding facility gave Clavamox as instructed and no issues while boarded.

**ULTRASONOGRAPHIC EXAMINATION OF THE ABDOMEN****Urinary System**

The urinary bladder was normal in size and tone containing anechoic urine with moderate nondependent particulate to pinpoint hyperechoic mildly congealed sediment, as well as mild dependent hyperechoic sand. The urinary bladder walls were sonographically unremarkable without evidence of inflammatory or neoplastic criteria. No macro calculi or urinary bladder masses were noted. The visualized urethra was sonographically normal to a depth of 4.0 cm.

The residual prostate was normal in size, symmetry, and echogenicity measuring 1.1 cm in diameter. No evidence of residual prostatomegaly or parenchymal mineralization was noted.

The area of the aortic trifurcation was free of pathology.

Normal size and margination were present in the kidneys. A normal 1:3 cortex / medulla ratio was maintained. The medulla and cortices were uniform in texture with some increased echogenicity and mild loss of corticomedullary symmetry and definition expected for the age of the patient. No evidence of pyelectasia or pyelonephritis was present. The left kidney measured 6.8 cm in length. The right kidney measured 6.8 cm in length.

**Adrenal Glands**

The left adrenal gland was uniform in size and contour with a uniformly hypoechoic parenchyma. The left adrenal gland measured 2.6 cm length x 0.78 cm width at the caudal pole. The right adrenal gland was uniform in size and contour with a uniformly hypoechoic parenchyma. The right adrenal gland measured 2.3 cm length x 0.66 cm width at the caudal pole.

**Spleen**

The spleen exhibited primarily finely textured parenchyma which was hyperechoic to the liver and renal cortical parenchyma. Mild generalized parenchyma heterogeneity was present without evidence of nodular changes. The capsule was smooth and regular without apparent expansion. The splenic vasculature at the hilus was normal in volume with no evidence of congestion or thrombosis. The parenchymal heterogeneity is likely consistent with benign changes such as extramedullary hematopoiesis or age-related remodeling with minor potential for inflammatory or neoplastic disease.

**Liver/ Gallbladder**

The liver was subjectively normal in size, structure, and contour. The liver parenchyma was mildly nonuniform and hypoechoic to the spleen with a moderate coarse echotexture and subjective mild to

**PATIENT**

Marcus Harmon

**SPECIES**

Canine

**BREED**

Lab Mix

**SEX**

NM

**AGE**

13 years

**WEIGHT**

75 lbs.

**INTERPRETED BY**R. McKenzie Daniel,  
DVM, DABVP  
(Canine and Feline)**IMAGING  
PERFORMED BY**

Sarah Pender, CVT

**HOSPITAL NAME**

SVS Imaging QC

**REFERRING VET**

Dr. Grace Zhang

**INVOICE**

14692

**DATE**

8/24/22

benign parenchymal remodeling. The hepatic and portal vasculature were normal in appearance without signs of congestion. A solitary thinly walled cyst containing anechoic fluid was present in the ventral hepatic parenchyma. The gallbladder was non-distended in size containing mild dependent to nondependent, nonorganized hyperechoic gallbladder debris. The cystic and common bile ducts were normal.

***Gastrointestinal***

The stomach presented intact wall layering with a normal wall layer ratio. The lumen of the stomach contained mild variably echogenic ingesta likely consistent with recent meal ingestion without signs of ileus, obstruction or foreign material.

The small intestine presented intact wall layering with 1:3 muscularis/mucosa ratio. The lumen of the small intestine was empty with no signs of ileus, obstruction, or foreign material.

Normal visible colon wall layers were present with apparent formed feces in lumen.

***Pancreas***

The parenchyma of the left limb, body, and right limb of the pancreas presented isoechoic to the adjacent omental fat. A normal curvilinear capsule contour of the pancreas was present. The visible pancreatic duct was normal. No signs of active inflammation or neoplastic disease were evident.

***Free Abdomen***

No overt lymphadenopathy or peritoneal effusion was present.

**ULTRASONOGRAPHIC FINDINGS*****Primary Findings***

- Moderate nondependent to congealed urinary bladder sediment with mild dependent sand
- Sonographically unremarkable residual prostate and visible proximal urethra
- Mild chronic renal changes - no evidence of pyelonephritis

***Secondary Findings***

- Hepatic parenchymal remodeling with solitary benign intraparenchymal cyst
- Mild gallbladder debris (non-mucocele)

**INTERPRETATION OF THE FINDINGS & FURTHER RECOMMENDATIONS**

Urine culture and sensitivity on a sterile urine sample is recommended. If off antibiotics for 7 days. No obvious evidence of upper / lower urinary tract or prostatic neoplastic criteria was noted. If positive urine C/S, appropriate antibiotic therapy based on C/S results would be recommended.

Potential for low-grade cystitis in conjunction with the urinary bladder sediment / sand is possible. Pending recheck urine C/S, empirical therapy for low-grade cystitis, which may include a potential urinary diet, would be reasonable.



**PATIENT**

Marcus Harmon

**SPECIES**

Canine

**BREED**

Lab Mix

**SEX**

NM

**AGE**

13 years

**WEIGHT**

75 lbs.

**INTERPRETED BY**

R. McKenzie Daniel, DVM, DABVP (Canine and Feline)

**IMAGING PERFORMED BY**

Sarah Pender, CVT

**HOSPITAL NAME**

SVS Imaging QC

**REFERRING VET**

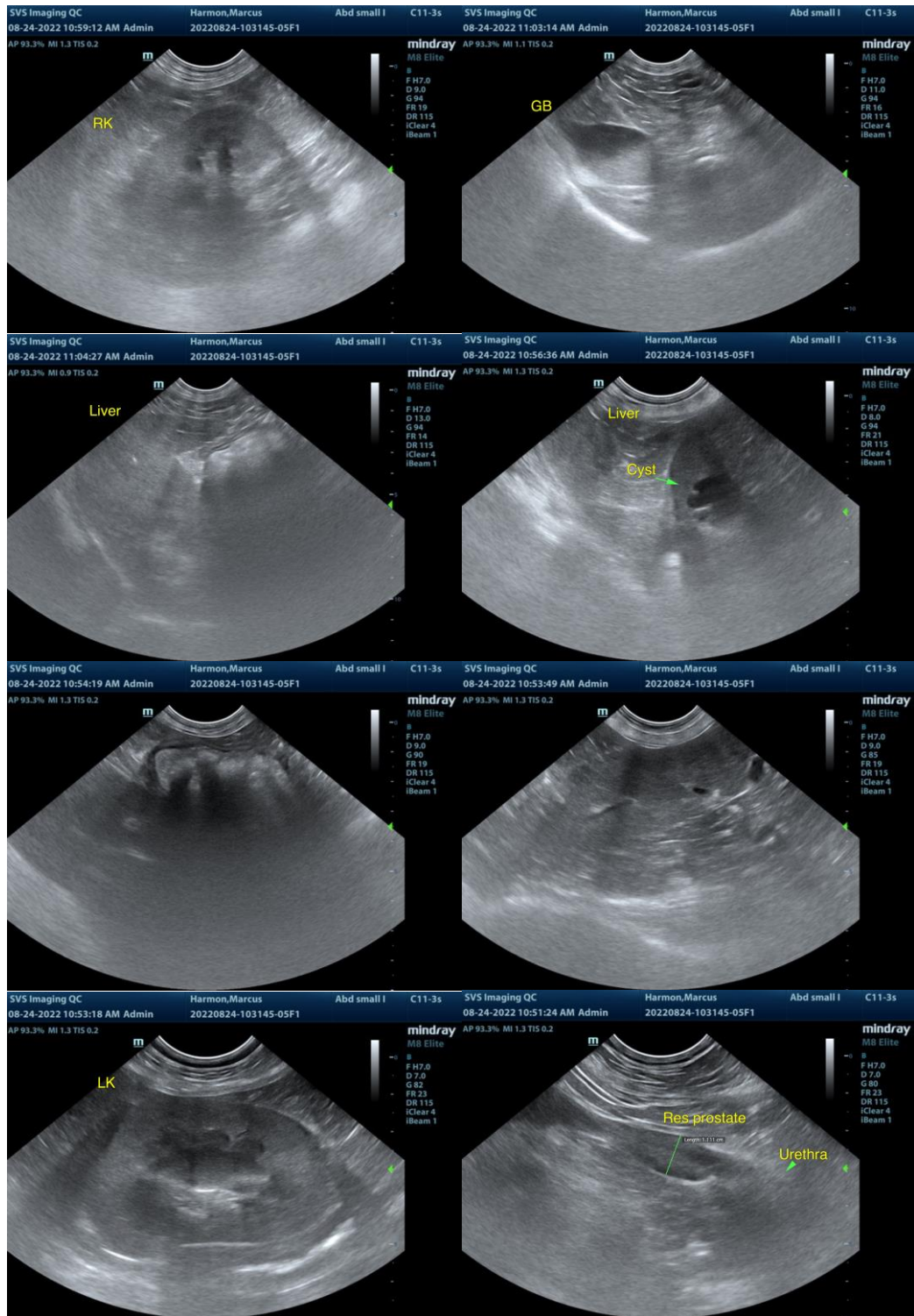
Dr. Grace Zhang

**INVOICE**

14692

**DATE**

8/24/22





**PATIENT**

Marcus Harmon

**SPECIES**

Canine

**BREED**

Lab Mix

**SEX**

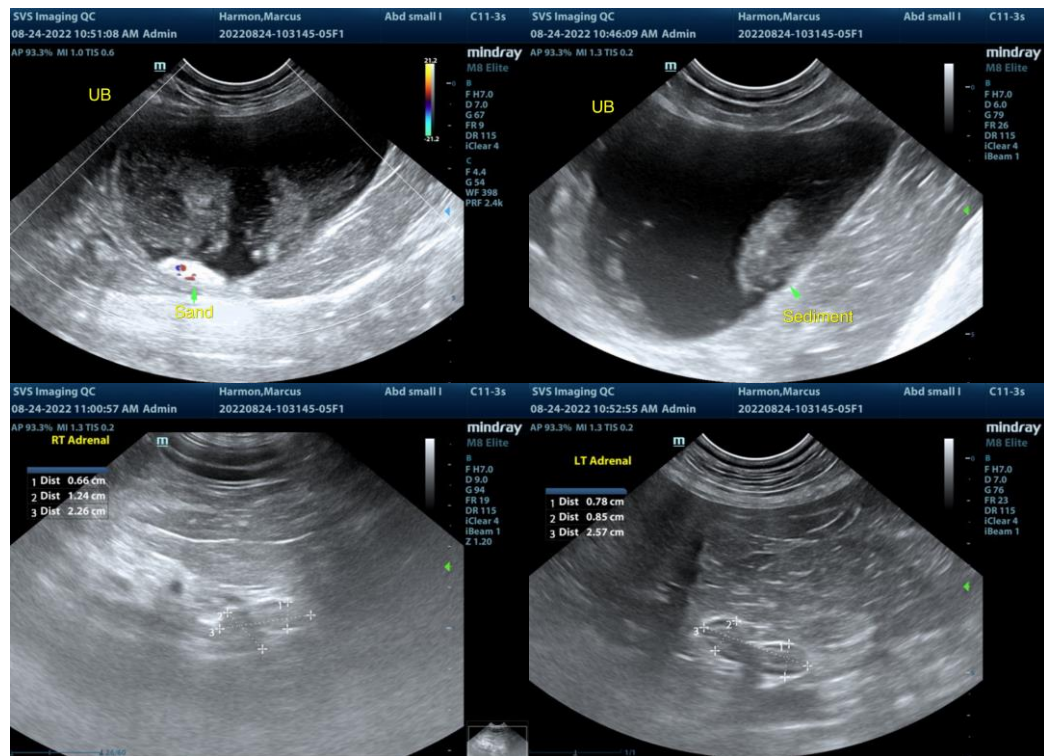
NM

**AGE**

13 years

**WEIGHT**

75 lbs.



**INTERPRETED BY**

R. McKenzie Daniel,  
DVM, DABVP  
(Canine and Feline)

**IMAGING PERFORMED BY**

Sarah Pender, CVT

**HOSPITAL NAME**

SVS Imaging QC

**REFERRING VET**

Dr. Grace Zhang

**INVOICE**

14692

**DATE**

8/24/22

**The information and recommendations provided are based on the images presented by the referring veterinarian/sonographer. No evaluation can be communicated regarding pathology that was not visible in the image/video clips provided.**

Thank you for this referral. If the clinical or image interpretation does not parallel your findings or if I can be of any further assistance please contact me.

**R. McKenzie Daniel, DVM, DABVP (Canine / Feline Practice)**  
**info@SonoPath.com**