



PATIENT

Roy Amir

SPECIES

Canine

BREED

Poodle Mix

SEX

M/N

AGE

1 year

WEIGHT

3.5 kg

INTERPRETED BY

R. McKenzie Daniel,
DVM, DABVP
(Canine and Feline)

**IMAGING
PERFORMED BY**

Dave Stasiuk RDMS,
RDCS

HOSPITAL NAME

Glamorgan AC

REFERRING VET

Glamorgan AC

INVOICE

14878

DATE

8/22/23

PRESENTING CLINICAL SIGNS

Mildly elevated pre and post prandial bile acids. Elevated ALT.

ULTRASONOGRAPHIC EXAMINATION OF THE ABDOMEN

Urinary System

The urinary bladder, trigone, cystourethral junction, and visible pelvic urethra to a depth of 2.0 cm exhibited normal thickness and tone. Anechoic urine was present in the lumen with no uroliths or sediment. No evidence of mineral or calculi was noted. The ureteral papillae were normal. The ureters were not visible which is normal. No evidence of inflammatory or neoplastic changes was noted.

The residual prostate was free of pathology.

No evidence of pathology in the area of the aortic trifurcation.

Normal size and margination were present in the kidneys. A normal 1:3 cortex / medulla ratio was maintained. Nonspecific increased to hyperechoic medullary echogenicity was present primarily around the outer medulla just inside the corticomedullary border. Potential pinpoint areas of medullary mineral were noted. No evidence of pyelectasia was noted. The left kidney measured 3.2 cm in length. The right kidney measured 3.4 cm in length.

Adrenal Glands

The left adrenal gland was uniform in size and contour with a uniformly hypoechoic parenchyma. The left adrenal gland measured 0.35 cm width at the caudal pole and 0.31 cm width at the cranial pole. No overt pathology was noted in the area of the right adrenal gland.

Spleen

The spleen exhibited a finely textured and homogenous parenchyma which was hyperechoic to the liver and renal cortical parenchyma. The capsule was smooth and regular without apparent expansion. The splenic vasculature at the hilus was normal in volume with no evidence of congestion or thrombosis. Acute to chronic inflammatory, neoplastic, or benign parenchyma changes were not noted.

Liver/ Gallbladder

The liver was subjectively normal in size, structure, and contour. The liver parenchyma was uniform and hypoechoic to the spleen with a mild coarse echotexture. The hepatic and portal vasculature were normal in appearance without signs of congestion. The gallbladder was non-distended in size with thin walls and primarily anechoic luminal content. The cystic and common bile ducts were normal.

Gastrointestinal

The stomach presented intact wall layering with a normal wall layer ratio. The lumen of the stomach was empty with no signs of ileus, obstruction, or foreign material.

The small intestine presented intact wall layering with 1:3 muscularis/mucosa ratio. The lumen of the small intestine was empty with no signs of ileus, obstruction, or foreign material.

Normal visible colon wall layers were present with apparent formed feces in lumen.



PATIENT

Roy Amir

SPECIES

Canine

BREED

Poodle Mix

SEX

M/N

AGE

1 year

WEIGHT

3.5 kg

INTERPRETED BY

R. McKenzie Daniel,
DVM, DABVP
(Canine and Feline)

IMAGING PERFORMED BY

Dave Stasiuk RDMS,
RDCS

HOSPITAL NAME

Glamorgan AC

REFERRING VET

Glamorgan AC

INVOICE

14878

DATE

8/22/23

Pancreas

The parenchyma of the left limb, body, and right limb of the pancreas presented isoechoic to the adjacent omental fat. A normal curvilinear capsule contour of the pancreas was present. The visible pancreatic duct was normal. No signs of active inflammation or neoplastic disease were evident.

Free Abdomen

No overt lymphadenopathy or peritoneal effusion was present.

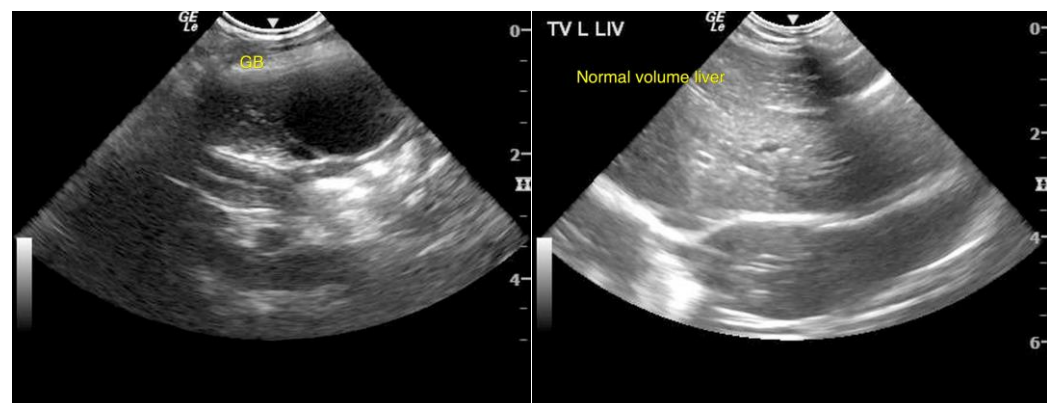
ULTRASONOGRAPHIC FINDINGS

- Normal volume liver
- Sonographically normal gallbladder
- Normal bilateral kidney size exhibiting nonspecific increased to hyperechoic outer medullary echogenicity

INTERPRETATION OF THE FINDINGS & FURTHER RECOMMENDATIONS

There was no overt evidence of intrahepatic or extrahepatic macroscopic shunt, given normal to adequate hepatic vascular volume. Primary parenchymal disease i.e., low-grade hepatitis with potential for portal hypoplasia / microvascular dysplasia considered most likely. Screening hepatic FNA cytology, assuming normal clotting status could be considered primarily to assess for inflammatory cell type. Hepatic core surgical biopsy is likely required for a definitive diagnosis. Some or all of the following protocol may be considered empirically.

Royal Canin Hepatic Support diet or Hills L/D, Metronidazole (7.5 mg/kg PO bid) over the next 14 days, **Lactulose** (Oral: 3.1-3.7 g/5 ml lactulose in a syrup base) long term to target 2-3 soft stools/day, with a **high-quality protein supplement** of minor amount of **yogurt** or **cheddar cheese**. Monitor bile acids, with attention paid to dropping albumin, BUN or cholesterol. SAME and nutraceuticals as needed. **Ursodiol** (10-15 mg/kg p.o. q24h) can be considered as hepatoprotectant and to enhance bile flow. **Zinc** serum level keep between 200—500 ug/dl. If deficient then Tx zinc acetate 1-3 mg/kg/day. Gastrointestinal protectants are recommended if the patient is anorexic.





PATIENT

Roy Amir

SPECIES

Canine

BREED

Poodle Mix

SEX

M/N

AGE

1 year

WEIGHT

3.5 kg

INTERPRETED BY

R. McKenzie Daniel,
DVM, DABVP
(Canine and Feline)

IMAGING PERFORMED BY

Dave Stasiuk RDMS,
RDCS

HOSPITAL NAME

Glamorgan AC

REFERRING VET

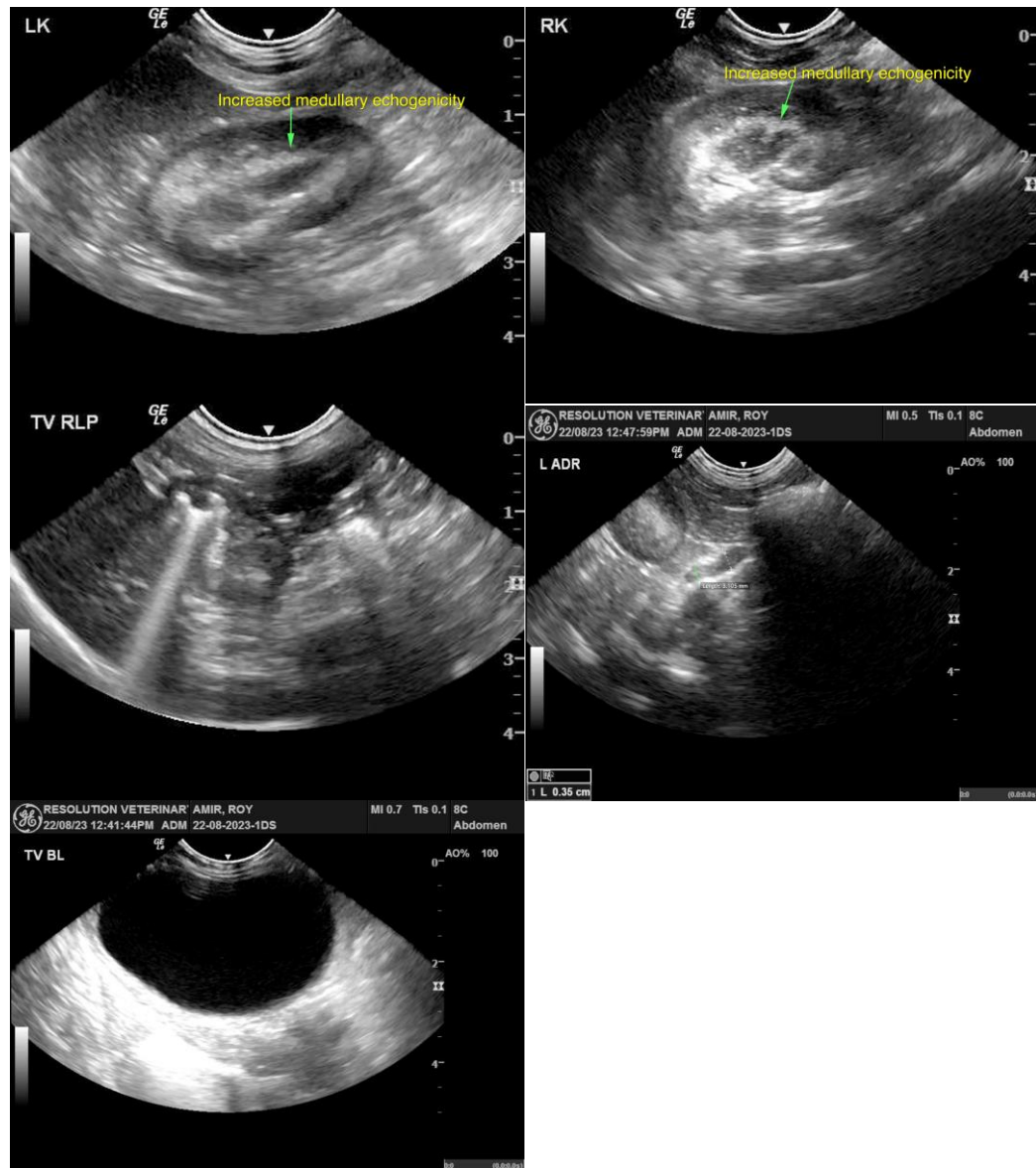
Glamorgan AC

INVOICE

14878

DATE

8/22/23



The information and recommendations provided are based on the images presented by the referring veterinarian/sonographer. No evaluation can be communicated regarding pathology that was not visible in the image/video clips provided.

Thank you for this referral. If the clinical or image interpretation does not parallel your findings or if I can be of any further assistance, please contact me.

R. McKenzie Daniel, DVM, DABVP (Canine/Feline Practice)
info@sonopath.com