



PATIENT	PRESENTING CLINICAL SIGNS
Slate Pandya	History: PU/PD. Bloodwork consistent with cushings dx adrenal dependent. BP: systolic 196 on 8/3/22. Began enalapril at 10mg BID and systolic BP today was 165. Plan to begin vetoryl today
SPECIES	Abnormal PE/Chem/CBC/UA Results: USG: 1.010. LDDST: pre: 3.5, 4hr 4.8, 8hr 5.7.
Canine	ULTRASONOGRAPHIC EXAMINATION OF THE ABDOMEN
BREED	Urinary System
Border Collie Mix	The urinary bladder, trigone, cystourethral junction, and visible pelvic urethra exhibited normal thickness and tone. Anechoic urine was present in the lumen with no uroliths or sediment. The ureteral papillae were normal. The ureters were not visible which is normal. No evidence of inflammatory or neoplastic changes were noted.
SEX	Adrenal Glands
MN	Both adrenal glands were mildly prominent in size exhibiting asymmetrical contour and non-homogeneous non-mineralized parenchyma. No adrenal tumors were noted. The left adrenal gland measured 1.0 cm width at the caudal pole and 3.3 cm length. The right adrenal gland measured 1.2 cm width at the caudal pole and 3.7 cm length.
AGE	Spleen
10.5yr	The spleen exhibited a finely textured and homogenous parenchyma which was hyperechoic to the liver and renal cortical parenchyma. The capsule was smooth and regular without apparent expansion. The splenic vasculature at the hilus was normal in volume with no evidence of congestion or thrombosis. Acute to chronic inflammatory, neoplastic, or benign parenchyma changes were not noted.
WEIGHT	Liver
45lb	The liver presented enlarged in size. The parenchyma of the liver was subjectively normal in echogenicity compared to the spleen and renal cortices. The liver parenchyma was uniform with a mildly coarse echotexture. The capsule of the liver was symmetrically rounded to mildly swollen in margination. The hepatic and portal vasculature were normal in appearance without signs of congestion. The gallbladder was non-distended in size with primarily anechoic luminal content and minor non-organized hyperechoic luminal debris. The cystic and common bile ducts were normal.
INTERPRETED BY	Gastrointestinal
R. McKenzie Daniel, DVM, DABVP (Canine and Feline)	The stomach presented intact wall layering with a normal wall layer ratio. The lumen of the stomach was empty with no signs of ileus, obstruction or foreign material.
IMAGING PERFORMED BY	The small intestine presented intact wall layering with 1:3 muscularis/mucosa ratio. The lumen of the small intestine was empty with no signs of ileus, obstruction or foreign material.
A. Rodriguez	Normal visible colon wall layers were present with apparent formed feces in lumen.
HOSPITAL NAME	
Foxfield Veterinary Services	
REFERRING VET	
A. Rodriguez	
INVOICE	
11438ag	
DATE	
08/22/2022	



PATIENT

Pancreas

Slate Pandya

The parenchyma of the left limb, body and right limb of the pancreas presented isoechoic to the adjacent omental fat. A normal curvilinear capsule contour of the pancreas was present. The visible pancreatic duct was normal. No signs of active inflammation or neoplastic disease was evident.

SPECIES

Canine

Free Abdomen

No overt lymphadenopathy or peritoneal effusion was present.

BREED

Border Collie Mix

ULTRASONOGRAPHIC FINDINGS

- Bilateral prominent adrenal glands
- Vacuolar hepatopathy pattern
- Bilateral age-related renal changes

SEX

MN

INTERPRETATION OF THE FINDINGS & FURTHER RECOMMENDATIONS

The bilateral kidneys are consistent with pituitary dependent hyperadrenocorticism without evidence of neoplastic criteria. Veteryl therapy and continued monitoring of systemic BP with assessment of clinical response would be reasonable. A urine C/S is suggested to rule out underlying UTI as patients with Cushing's are more prone to urinary infection.

AGE

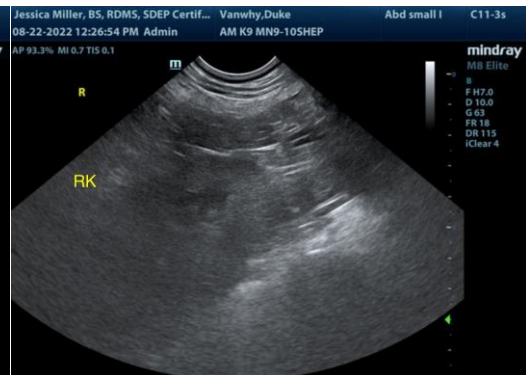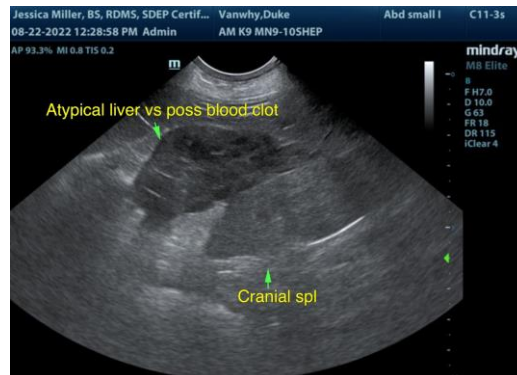10.5yr

WEIGHT

45lb

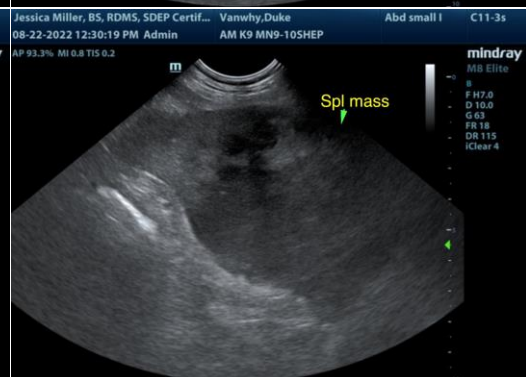
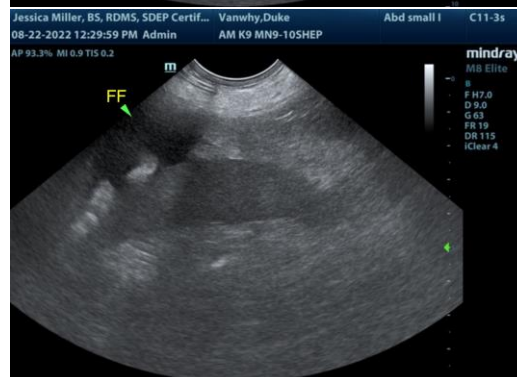INTERPRETED BY

R. McKenzie Daniel,
DVM, DABVP
(Canine and Feline)



IMAGING PERFORMED BY

A. Rodriguez



HOSPITAL NAME

Foxfield Veterinary
Services

REFERRING VET

A. Rodriguez

INVOICE

11438ag

DATE

08/22/2022



PATIENT

Slate Pandya

SPECIES

Canine

BREED

Border Collie Mix

SEX

MN

AGE

10.5yr

WEIGHT

45lb

INTERPRETED BY

R. McKenzie Daniel,
DVM, DABVP
(Canine and Feline)

IMAGING PERFORMED BY

A. Rodriguez

HOSPITAL NAME

Foxfield Veterinary
Services

REFERRING VET

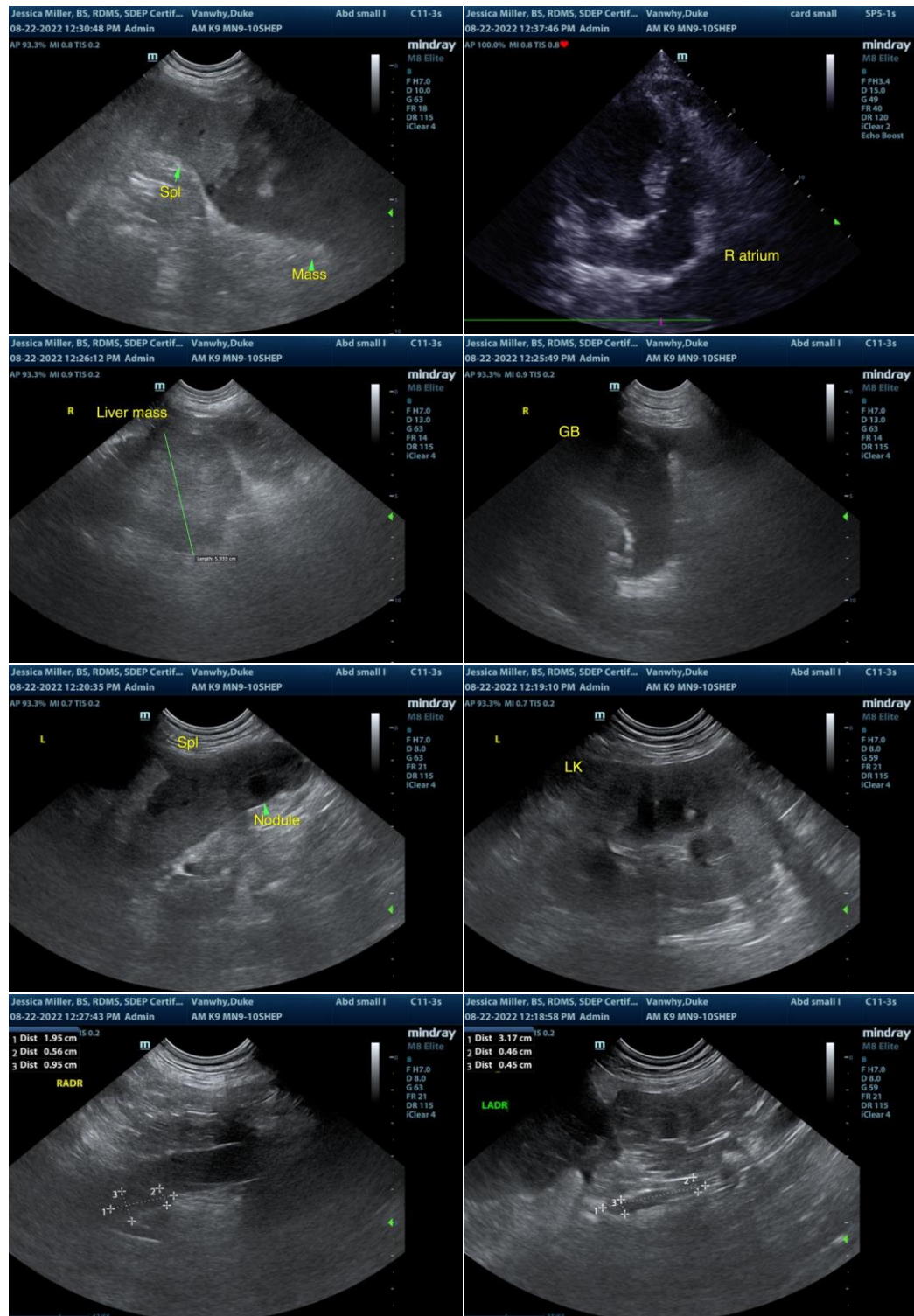
A. Rodriguez

INVOICE

11438ag

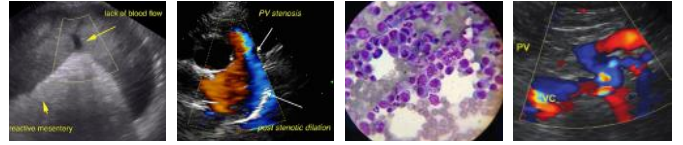
DATE

08/22/2022



The information and recommendations provided are based on the images presented by the referring veterinarian/sonographer. No evaluation can be communicated regarding pathology that was not visible in the image/video clips provided.

Thank you for this referral. If the clinical or image interpretation does not parallel your findings or if I



PATIENT

can be of any further assistance please contact me.

Slate Pandya

R. McKenzie Daniel, DVM, DABVP (Canine / Feline Practice)

info@SonoPath.com

SPECIES

Canine

BREED

Border Collie Mix

SEX

MN

AGE

10.5yr

WEIGHT

45lb

INTERPRETED BY

R. McKenzie Daniel,
DVM, DABVP
(Canine and Feline)

**IMAGING
PERFORMED BY**

A. Rodriguez

HOSPITAL NAME

Foxfield Veterinary
Services

REFERRING VET

A. Rodriguez

INVOICE

11438ag

DATE

08/22/2022