
PATIENT PRESENTING CLINICAL SIGNS

Hank Zahn History: Coughing for 5 to 7 days, worse at night. Decreased exercise tolerance. Urinating and defecating normally. HR 132 at a time when he was relaxed. Arrhythmia/irregular heartbeats heard. Only meds currently are Metacam.

SPECIES

Canine

Abnormal PE/Chem/CBC/UA Results: SDMA 18(0-14). Creatinine 135(27-124). Specific Gravity 1.042

BREED

Saint Bernard

ULTRASONOGRAPHIC EXAMINATION OF THE HEART
SEX

MN

AGE

10yr

WEIGHT

156lb

CANINE CARDIAC PARAMETERS	MR VMAX (m/s)	TR VMAX (m/s)	LA/AO (Boon method)	LA/AO (Heart Base; Swe)	FS (%)	EF (%)	EPSS (cm)
NORMAL PARAMETER	4.5-5.5	<2.7	1.3	<1.3	28-40	40-100	<0.6
PATIENT		2.2		1.6	16.2	33.7	1.2
CANINE CARDIAC PARAMETERS	HR (BPM)	AV VMAX (m/s)	PV MAX (m/s)	BODY WEIGHT (kg)	LA 2D short axis Base view (cm)	LVIDd Avg; 2D and m-mode short axis (cm)	LVIDs Avg; 2D and m-mode short axis (cm)
NORMAL PARAMETER	50-100	0.7-1.7	0.7-1.6				
PATIENT	NM	NM	1.1		6.7	6.4	

INTERPRETED BY

 R. McKenzie Daniel,
 DVM, DABVP
 (Canine and Feline)

IMAGING PERFORMED BY

Crystal Hill

HOSPITAL NAME

 Smithville Animal
 Hospital

REFERRING VET

Dr. DeHaan

INVOICE

11463ag

DATE

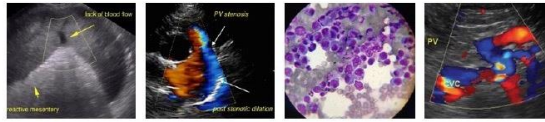
08/22/2022

Cardiac Presentation

Moderate ventricular dilation with diminished systolic function, increased EPSS and LV sphericity was present. Subjective mild decreased LV wall thickness was noted. Mild LA enlargement was present. The mitral valve appears to exhibit minor thickening with no prolapse or chordae tendineae rupture. Mild centralized to eccentric mitral regurgitation was present. The tricuspid valve appears overtly normal. No evidence of RA or ventricular dilation was noted. Mild tricuspid regurgitation was observed. The aortic valve appears overtly normal with normal systolic laminal LVOT flow. No obvious AI was noted. Normal pulmonic valve with normal RVOT velocity. No obvious pulmonic insufficiency was noted. No pericardial or pleural effusion, no obvious cardiac tumors. Consistent tachyarrhythmia was present.

ULTRASONOGRAPHIC FINDINGS

- Tachyarrhythmia
- LA enlargement
- LV enlargement with subnormal myocardial contractility/LV dysfunction
- MR/TR



PATIENT

Hank Zahn

SPECIES

Canine

BREED

Saint Bernard

SEX

MN

AGE

10yr

WEIGHT

156lb

INTERPRETED BY

R. McKenzie Daniel,
DVM, DABVP
(Canine and Feline)

IMAGING PERFORMED BY

Crystal Hill

HOSPITAL NAME

Smithville Animal
Hospital

REFERRING VET

Dr. DeHaan

INVOICE

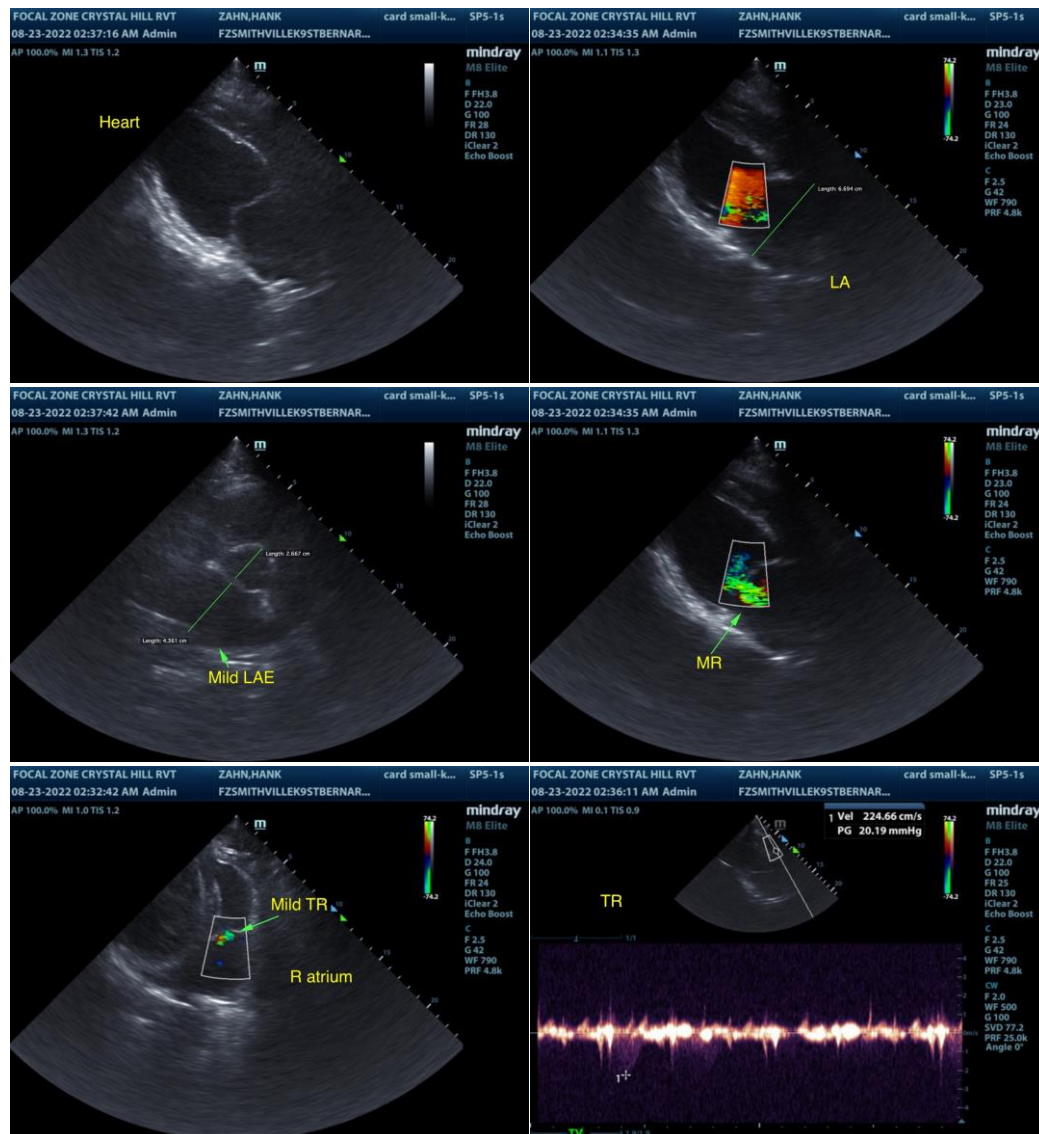
11463ag

DATE

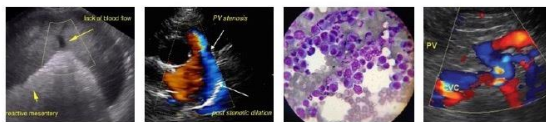
08/22/2022

INTERPRETATION OF THE FINDINGS & FURTHER RECOMMENDATIONS

This study reveals primarily left sided cardiomyopathy with consistent tachyarrhythmia as well as mitral and tricuspid valve insufficiency. The insufficiency was not overtly consistent with clinical pulmonary hypertension. This may be primary in nature i.e. DCM like cardiomyopathy or secondary to clinical issues like taurine deficiency, hypothyroidism, myocarditis or infiltrative disease. Diet history to rule out grain free diet, thyroid status and/or troponin level could be considered. An ECG strongly recommended for further assessment of the arrhythmia. The tachycardia may predispose to eventual right sided congestion. Pimobendan 0.3 mg/kg PO BID +/- diuretic therapy if evidence of pulmonary edema or increased resting RR is recommended. Taurine supplementation recommended if clinically indicated. A referral to a cardiologist is warranted for further assessment. A guarded overall prognosis is indicated.



The information and recommendations provided are based on the images presented by the referring veterinarian/sonographer. No evaluation can be communicated regarding pathology that was not



PATIENT visible in the image/video clips provided.

Hank Zahn Thank you for this referral. If the clinical or image interpretation does not parallel your findings or if I can be of any further assistance please contact me.

SPECIES R. McKenzie Daniel, DVM, DABVP (Canine / Feline Practice)

Canine info@SonoPath.com

BREED

Saint Bernard

SEX

MN

AGE

10yr

WEIGHT

156lb

INTERPRETED BY

R. McKenzie Daniel,
DVM, DABVP
(Canine and Feline)

**IMAGING
PERFORMED BY**

Crystal Hill

HOSPITAL NAME

Smithville Animal
Hospital

REFERRING VET

Dr. DeHaan

INVOICE

11463ag

DATE

08/22/2022