



PATIENT PRESENTING CLINICAL SIGNS

Duchess Shiels History: PU/PD, loose stool/diarrhea, episodic decreased appetite

SPECIES

Canine

BREED

Husky Mix

SEX

FS

AGE

2008

WEIGHT

83

INTERPRETED BY

R. McKenzie Daniel,
DVM, DABVP
(Canine and Feline)

IMAGING PERFORMED BY

Rebekah Jakum, CVT
ARDMS/RVT

HOSPITAL NAME

Lehigh Valley AH Allen

REFERRING VET

Dr. Meyer

INVOICE

11452ag

DATE

08/22/2022

ULTRASONOGRAPHIC EXAMINATION OF THE ABDOMEN

Urinary System

The urinary bladder, trigone, cystourethral junction, and visible pelvic urethra to a depth of 3 cm exhibited normal thickness and tone. Anechoic urine was present in the lumen with no uroliths or sediment. The ureteral papillae were normal. The ureters were not visible which is normal. No evidence of inflammatory or neoplastic changes were noted.

Normal size and margination was present in the kidneys. A normal 1:3 cortex / medulla ratio was maintained. The medulla and cortices were uniform in texture with some increased echogenicity and mild loss of corticomedullary symmetry and definition expected for the age of the patient. No evidence of pelvic dilation was present. The left kidney measured 6.5 cm in length. The right kidney measured 6.6 cm in length.

The area of the aortic trifurcation was free of pathology.

Adrenal Glands

The left adrenal gland was uniform in size and contour with a uniformly hypoechoic parenchyma. The left adrenal gland measured 0.64 cm width at the caudal pole and 3.2 cm length. The right adrenal gland was uniform in size and contour with a uniformly hypoechoic parenchyma. The right adrenal gland measured 1.1 cm width at the caudal pole and 3.1 cm length.

Spleen

The spleen exhibited a finely textured and homogenous parenchyma which was hyperechoic to the liver and renal cortical parenchyma. The capsule was smooth and regular without apparent expansion. The splenic vasculature at the hilus was normal in volume with no evidence of congestion or thrombosis. Acute to chronic inflammatory, neoplastic, or benign parenchyma changes were not noted.

Liver

The liver was subjectively normal in size, structure, and contour. The liver parenchyma was mildly nonuniform and hypoechoic to the spleen with a moderate coarse echotexture and subjective mild to benign parenchymal remodeling. The hepatic and portal vasculature were normal in appearance without signs of congestion.

The gallbladder was non-distended in size with thin walls and primarily anechoic luminal content with mild hypoechoic debris. The cystic and common bile ducts were normal.

Gastrointestinal

The stomach presented intact wall layering with a normal wall layer ratio. The lumen of the stomach was empty with no signs of ileus, obstruction or foreign material.

The small intestine presented intact wall layering with 1:3 muscularis/mucosa ratio. The lumen of the small intestine was empty with no signs of ileus, obstruction or foreign material.



PATIENT Normal visible colon wall layers were present with apparent formed feces in lumen.

Duchess Shiels **Pancreas**

The parenchyma of the left limb, body and right limb of the pancreas presented isoechoic to the adjacent omental fat. A normal curvilinear capsule contour of the pancreas was present. The visible pancreatic duct was normal. No signs of active inflammation or neoplastic disease was evident.

SPECIES

Canine

Free Abdomen

BREED

No overt lymphadenopathy or peritoneal effusion was present.

Husky Mix

ULTRASONOGRAPHIC FINDINGS

SEX

- Mild chronic renal changes
- Mild hepatic parenchyma remodeling-benign hepatopathy
- Mild gallbladder debris-(non-mucocele)

FS

AGE

INTERPRETATION OF THE FINDINGS & FURTHER RECOMMENDATIONS

2008

Largely a geriatric abdomen without evidence of overt visceral pathology. A resting cortisol level to rule out occult Addison's disease is recommended. Further assessment of the PU/PD and GI signs may include leptospirosis titer/PCR, a GI panel to include PLI/TLI/Cobalamin/Folate and further renal staging to include urine C/S and protein: creatinine ratio on sterile urine sample. Hepatic functionality appears to be normal given normal ALB, GLU, BUN and CHOL levels.

WEIGHT

83

INTERPRETED BY

R. McKenzie Daniel,
DVM, DABVP
(Canine and Feline)

Empirically, a limited antigen or hydrolyzed diet trial with potential long term dietary therapy, prophylactic deworming (Panacur 50 mg/kg SID x 5 consecutive days with repeat protocol in 3 weeks even if fecal testing is negative), high colony count probiotic (Provable or Visbiome), antibiotic trial and as needed gastrointestinal support with assessment of clinical response may prove beneficial.

IMAGING PERFORMED BY

Rebekah Jakum, CVT
ARDMS/RVT

HOSPITAL NAME

Lehigh Valley AH Allen

REFERRING VET

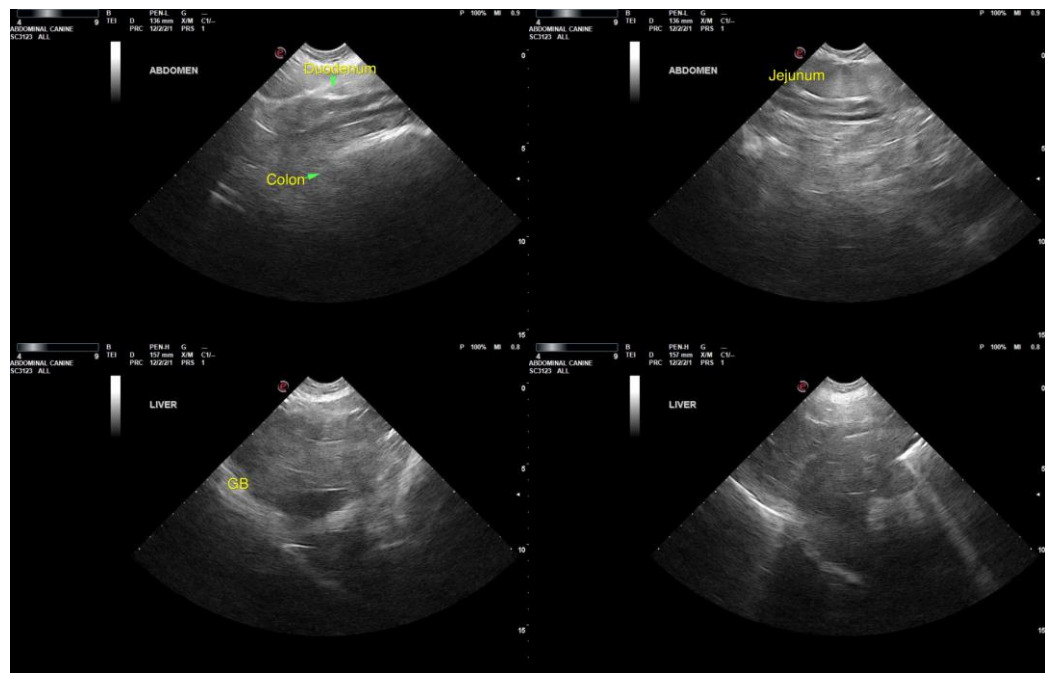
Dr. Meyer

INVOICE

11452ag

DATE

08/22/2022





PATIENT

Duchess Shiels

SPECIES

Canine

BREED

Husky Mix

SEX

FS

AGE

2008

WEIGHT

83

INTERPRETED BY

R. McKenzie Daniel,
DVM, DABVP
(Canine and Feline)

IMAGING PERFORMED BY

Rebekah Jakum, CVT
ARDMS/RVT

HOSPITAL NAME

Lehigh Valley AH Allen

REFERRING VET

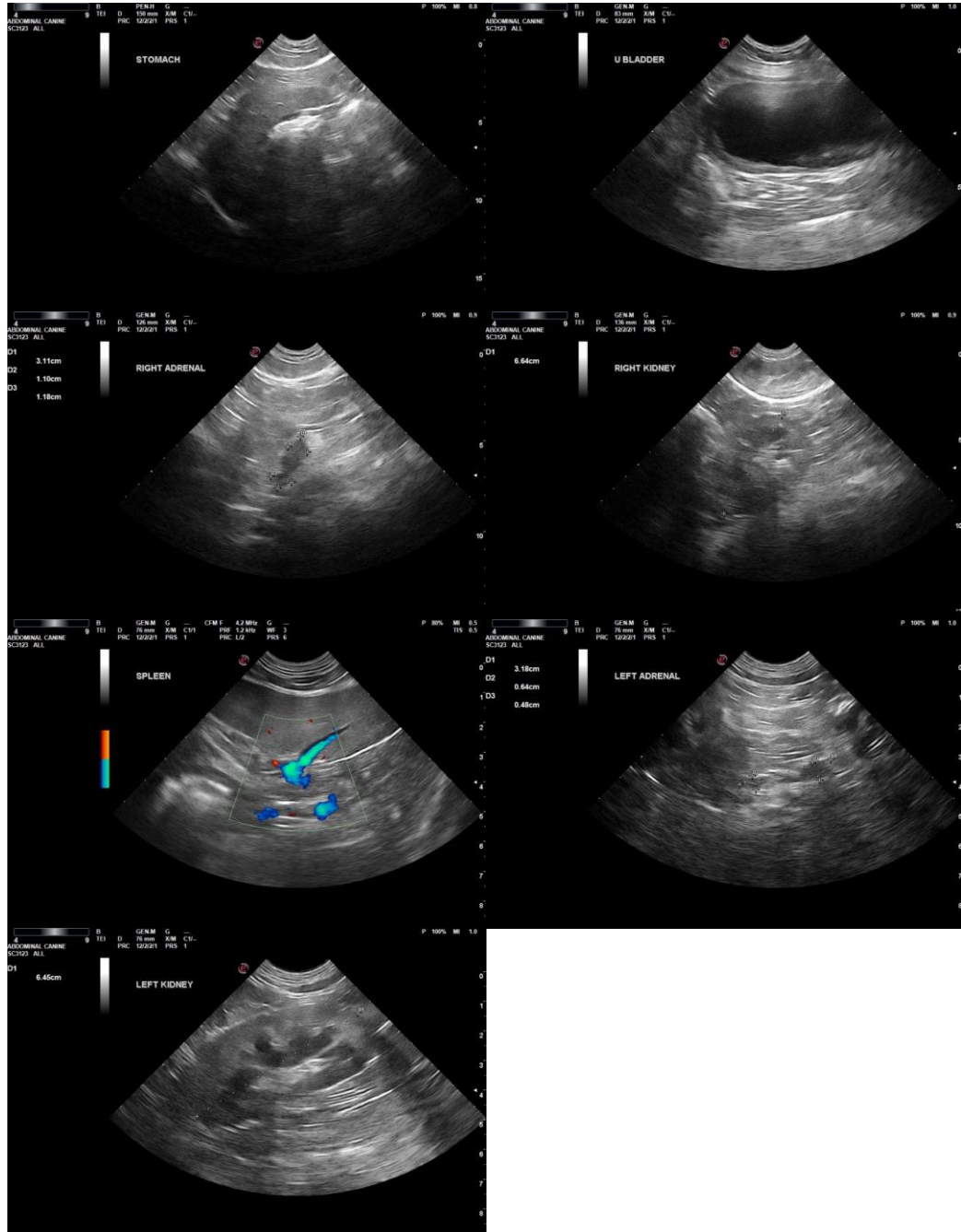
Dr. Meyer

INVOICE

11452ag

DATE

08/22/2022



The information and recommendations provided are based on the images presented by the referring veterinarian/sonographer. No evaluation can be communicated regarding pathology that was not visible in the image/video clips provided.

Thank you for this referral. If the clinical or image interpretation does not parallel your findings or if I can be of any further assistance, please contact me.

R. McKenzie Daniel, DVM, DABVP (Canine/Feline Practice)
mac.daniel@sonopath.com



PATIENT

Duchess Shiels

SPECIES

Canine

BREED

Husky Mix

SEX

FS

AGE

2008

WEIGHT

83

INTERPRETED BY

R. McKenzie Daniel,
DVM, DABVP
(Canine and Feline)

**IMAGING
PERFORMED BY**

Rebekah Jakum, CVT
ARDMS/RVT

HOSPITAL NAME

Lehigh Valley AH Allen

REFERRING VET

Dr. Meyer

INVOICE

11452ag

DATE

08/22/2022