



PATIENT

Ruby Fleming

SPECIES

Canine

BREED

Chihuahua

SEX

FS

AGE

7

WEIGHT

6.83

INTERPRETED BY

R. McKenzie Daniel,
DVM, DABVP
(Canine and Feline)

IMAGING PERFORMED BY

Melissa Wilberger

HOSPITAL NAME

Wilvet South

REFERRING VET

Banfield Pet Hospital

INVOICE

14661ag

DATE

08/20/2023

PRESENTING CLINICAL SIGNS

Last night the owner picked Ruby up and noticed that her abdomen was distended. The owner also states that Ruby has been lethargic and not wanting to eat her kibble for several days.

Abnormal PE/Chem/CBC/UA Results: The free fluid in the peritoneum is nonspecific. A definitive discrete mass involving the abdomen is not readily appreciable radiographically however a mass obscured by the presence of free fluid cannot be ruled out by this assessment and should still be considered. The enlargement of the liver could be associated with a benign/metabolic versus possibly a neoplastic or an infectious hepatopathy. There is no appreciable evidence of definitive mechanical ileus. The mineral opaque calculi within the lumen of the urinary bladder suggest cystitis and a urinary tract infection may be considered. The thorax is subjectively unremarkable on the available images. There is no appreciable evidence of cardiomegaly, congestive heart failure, nodular pulmonary metastatic disease, bronchopneumonia, or overt intrathoracic lymph node enlargement. Mild anemia and mild elevation in liver values. Low platelets confirmed by smear.

ULTRASONOGRAPHIC EXAMINATION OF THE ABDOMEN

Urinary System

The urinary bladder, trigone, cystourethral junction, and visible pelvic urethra exhibited normal tone. Mild nonuniform thickening of the urinary bladder wall was present. Several to multiple small dependent calculi along with dependent to non-dependent mineral and hyperechoic sediment was present.

Normal size and margination were present in the kidneys. A normal 1:3 cortex / medulla ratio was maintained. The medulla and cortices were uniform in texture with some increased echogenicity and mild loss of corticomedullary symmetry and definition expected for the age of the patient. No evidence of pelvic dilation was present. Pinpoint medullary mineral was present bilaterally. The left kidney measured 4.3 cm in length. The right kidney measured 4.4 cm in length.

The area of the iliac trifurcation was free of pathology including no evidence of medial, iliac or sublumbar lymphadenopathy or masses.

Adrenal Glands

The bilateral adrenal glands were overtly normal in size, position and shape. The left adrenal gland measured 0.39 cm width at the caudal pole. The right adrenal gland measured 0.51 cm width at the caudal pole.

Spleen

The spleen exhibited solitary to multiple mildly expansive isoechoic solid nodules with associated splenic capsule distortion. An example of a nodule measured 1.8 cm in diameter. The splenic vasculature at the hilus was normal in volume with no evidence of congestion or thrombosis.

Liver/Gallbladder

The liver exhibited moderate to marked generalized enlargement with areas of capsule asymmetry and generalized mild to moderate non-homogenous parenchyma. Normal vascular volume. The hepatic and portal vasculature were normal in appearance without signs of congestion. The gallbladder was non-



PATIENT

Ruby Fleming

distended in size with prominent hyperechoic walls. Minor gallbladder sediment was present. The cystic and common bile ducts were normal.

Gastrointestinal

SPECIES

Canine

The stomach presented regionally thickened wall layering subjectively in the area of the fundus and gastric body. The lumen of the stomach contained mild retained chyme and lumen gas with no signs of ileus, obstruction or foreign material. The gastric body wall measured up to 0.78 cm.

BREED

Chihuahua

The small intestine presented intact wall layering with 1:3 muscularis/mucosa ratio. The lumen of the small intestine was empty with no signs of ileus, obstruction or foreign material.

Normal visible colon wall layers were present with apparent formed feces in lumen.

SEX

FS

Pancreas

The pancreas was mildly prominent in size with isoechoic to heterogeneous parenchyma compared to adjacent omentum. No signs of active inflammation or neoplasia.

AGE

7

Free Abdomen

No omental masses or overt/significant lymphadenopathy was present.

Mild to moderate volume peritoneal effusion was present.

WEIGHT

6.83

ULTRASONOGRAPHIC FINDINGS

- Enlarged, non-homogeneous liver.
- Mild gallbladder sediment (non-mucocele)
- Mild expansive splenic nodules
- Regional mild thickened stomach, normal small bowel
- Mild prominent nonhomogeneous pancreas
- Peritoneal effusion
- Urinary bladder calculi / sediment

INTERPRETED BY

R. McKenzie Daniel,
DVM, DABVP
(Canine and Feline)

INTERPRETATION OF THE FINDINGS & FURTHER RECOMMENDATIONS

Full CBC / Chemistry panel / UA with urine C/S is recommended to assess hepatic enzymes, albumin levels or for inflammatory criteria. Assuming normal clotting status, hepatosplenic FNA cytology using 25ga needle and effusion analysis, cytology +/- C/S if inflammatory cells is recommended for further assessment. Hepatosplenic neoplasia or multicentric neoplasia is of primary concern, although benign etiologies are possible. Low grade pancreatitis is possible although sonographically pancreatitis does not appear to be a primary clinical player.

IMAGING PERFORMED BY

Melissa Wilberger

HOSPITAL NAME

Wilvet South

REFERRING VET

Banfield Pet Hospital

INVOICE

14661ag

DATE

08/20/2023



PATIENT

Ruby Fleming

SPECIES

Canine

BREED

Chihuahua

SEX

FS

AGE

7

WEIGHT

6.83

INTERPRETED BY

R. McKenzie Daniel,
DVM, DABVP
(Canine and Feline)

IMAGING PERFORMED BY

Melissa Wilberger

HOSPITAL NAME

Wilvet South

REFERRING VET

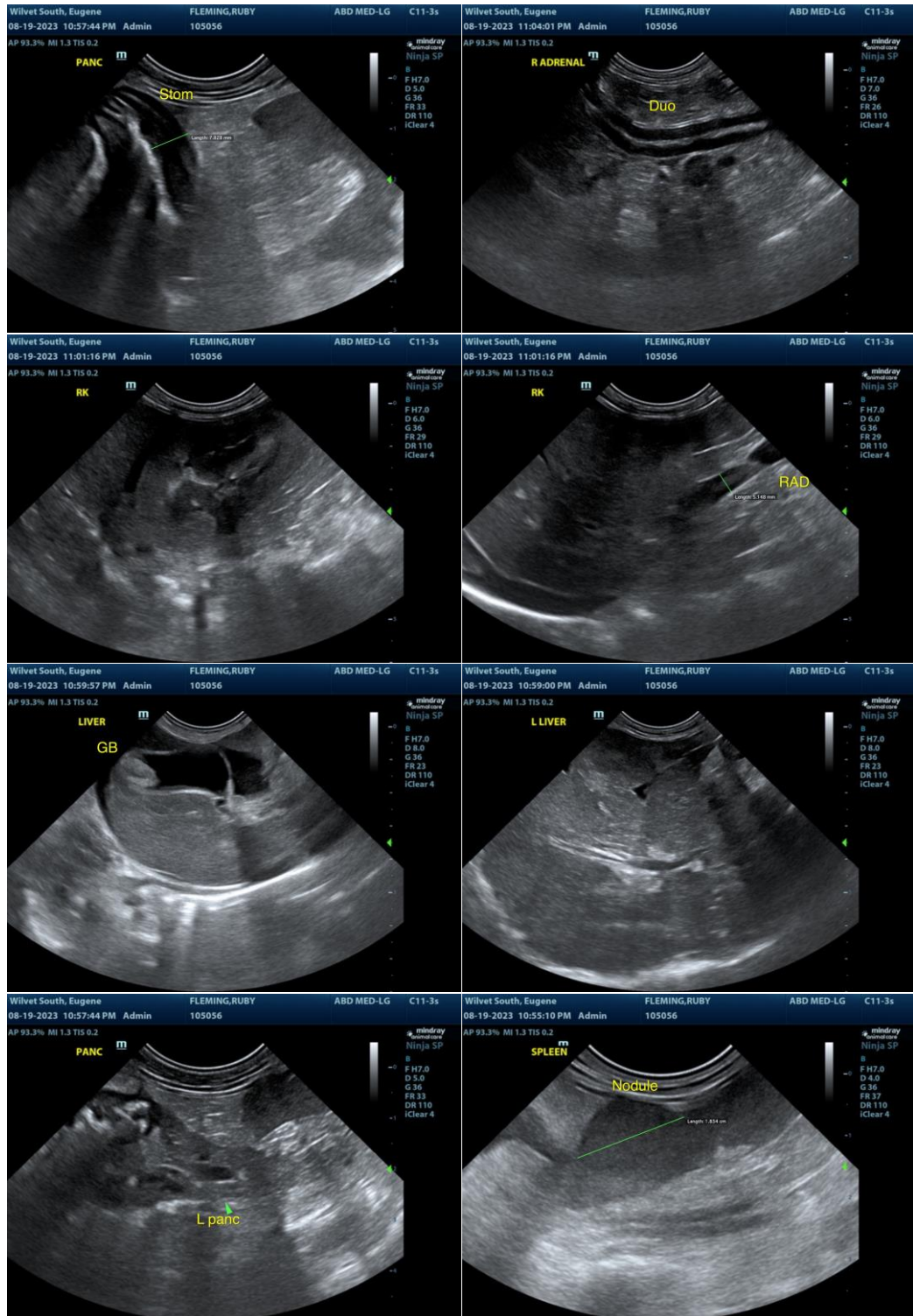
Banfield Pet Hospital

INVOICE

14661ag

DATE

08/20/2023





PATIENT

Ruby Fleming

SPECIES

Canine

BREED

Chihuahua

SEX

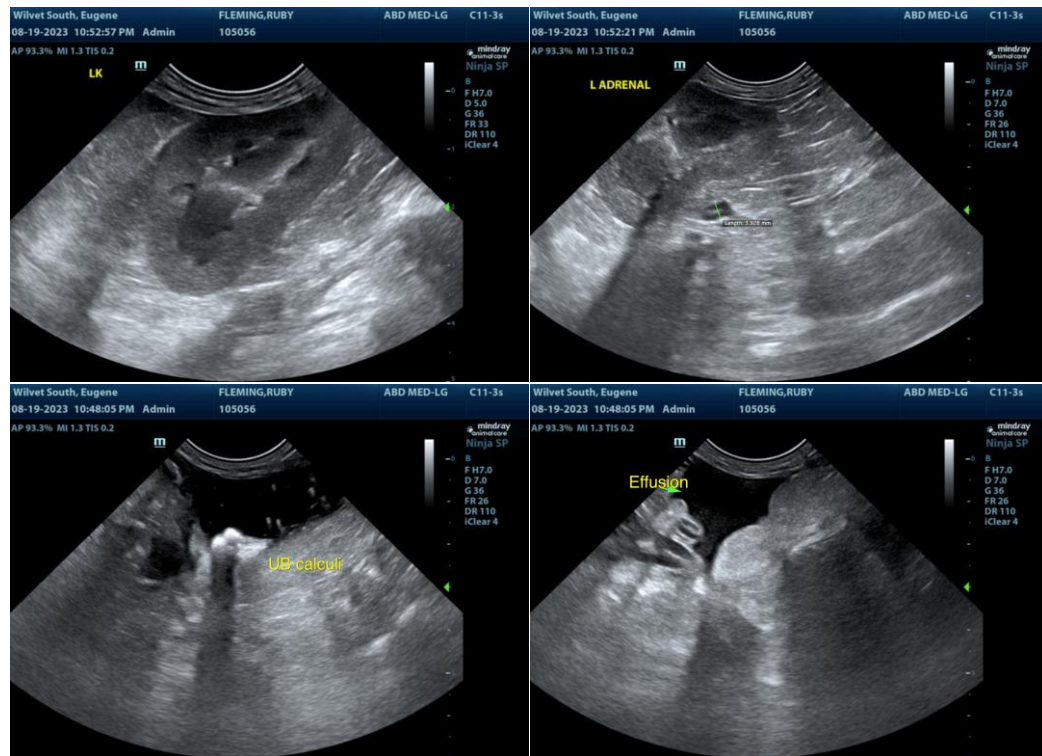
FS

AGE

7

WEIGHT

6.83



INTERPRETED BY

R. McKenzie Daniel,
DVM, DABVP
(Canine and Feline)

IMAGING PERFORMED BY

Melissa Wilberger

HOSPITAL NAME

Wilvet South

REFERRING VET

Banfield Pet Hospital

INVOICE

14661ag

DATE

08/20/2023

The information and recommendations provided are based on the images presented by the referring veterinarian/sonographer. No evaluation can be communicated regarding pathology that was not visible in the image/video clips provided.

Thank you for this referral. If the clinical or image interpretation does not parallel your findings or if I can be of any further assistance, please contact me.

R. McKenzie Daniel, DVM, DABVP (Canine/Feline Practice)
info@sonopath.com