



**PATIENT PRESENTING CLINICAL SIGNS**

Marty Brennan Marty has a slowly-growing mass at bridge of nose. Bx= subcutaneous mast cell tumor. Met check. Chest radiographs WNL. On Benadryl 25 mg, 1/2 tab BID, Famotidine 10 mg, 1/2 tab BID

**SPECIES ULTRASONOGRAPHIC EXAMINATION OF THE ABDOMEN**

Canine **Urinary System**

**BREED** Terrier Mix  
 The urinary bladder, trigone, cystourethral junction, and visible pelvic urethra to a depth of 3 cm exhibited normal thickness and tone. Anechoic urine was present in the lumen with no uroliths or sediment. The ureteral papillae were normal. The ureters were not visible which is normal. No evidence of inflammatory or neoplastic changes were noted.

**SEX** Normal size and margination were present in the kidneys. A normal 1:3 cortex / medulla ratio and normal corticomedullary definition were maintained. The echogenicity of the cortex was similar to or slightly less than normal liver parenchyma while the medulla echogenicity was hypoechoic to the cortex with no evidence of pelvic dilation. The left kidney measured 3.9 cm in length. The right kidney measured 4.2 cm in length.

**AGE** 6yr  
 The area of the iliac trifurcation was free of pathology including no evidence of medial, iliac or sublumbar lymphadenopathy or masses.

**WEIGHT** 14lb  
 The area of the residual prostate appeared normal and free of pathology.

**Adrenal Glands**

The left adrenal gland was uniform in size and contour with a uniformly hypoechoic parenchyma. The left adrenal gland measured 0.45 cm width at the caudal pole and 0.34 cm width at the cranial pole. The right adrenal gland was uniform in size and contour with a uniformly hypoechoic parenchyma. The right adrenal gland measured 0.33 cm width at the caudal pole and 0.41 cm width at the cranial pole.

**INTERPRETED BY**

R. McKenzie Daniel, DVM, DABVP (Canine and Feline)

**Spleen**

The spleen exhibited a finely textured and homogenous parenchyma which was hyperechoic to the liver and renal cortical parenchyma. The capsule was smooth and regular without apparent expansion. The splenic vasculature at the hilus was normal in volume with no evidence of congestion or thrombosis. Acute to chronic inflammatory, neoplastic, or benign parenchyma changes were not noted.

**HOSPITAL NAME**

Airport Animal Hospital

**Liver/Gallbladder**

The liver was subjectively normal in size, structure, and contour. The liver parenchyma was uniform and hypoechoic to the spleen with a mild coarse echotexture. The hepatic and portal vasculature were normal in appearance without signs of congestion. The gallbladder was non-distended in size with thin walls and primarily anechoic luminal content with mild to moderate hyperechoic sediment. The cystic and common bile ducts were normal.

**REFERRING VET**

Asha Gudluru, DVM

**Gastrointestinal**

**INVOICE**

14673ag

The stomach presented intact wall layering with a normal wall layer ratio. The lumen of the stomach appeared to be mildly distended with gas with no signs of ileus, obstruction or foreign material.

**DATE**

08/20/2023

The small intestine presented intact wall layering with 1:3 muscularis/mucosa ratio. The lumen of the small intestine was empty with no signs of ileus, obstruction or foreign material.

Normal visible colon wall layers were present with apparent formed feces in lumen.



**PATIENT**

**Pancreas**

Marty Brennan

The parenchyma of the left limb, body and right limb of the pancreas presented isoechoic to the adjacent omental fat. A normal curvilinear capsule contour of the pancreas was present. The visible pancreatic duct was normal. No signs of active inflammation or neoplastic disease was evident.

**SPECIES**

Canine

**Free Abdomen**

No omental masses, overt lymphadenopathy or peritoneal effusion was present.

**BREED**

Terrier Mix

**ULTRASONOGRAPHIC FINDINGS**

- Sonographically unremarkable abdomen.
- Gallbladder debris (non-mucocele).

**SEX**

MN

**INTERPRETATION OF THE FINDINGS & FURTHER RECOMMENDATIONS**

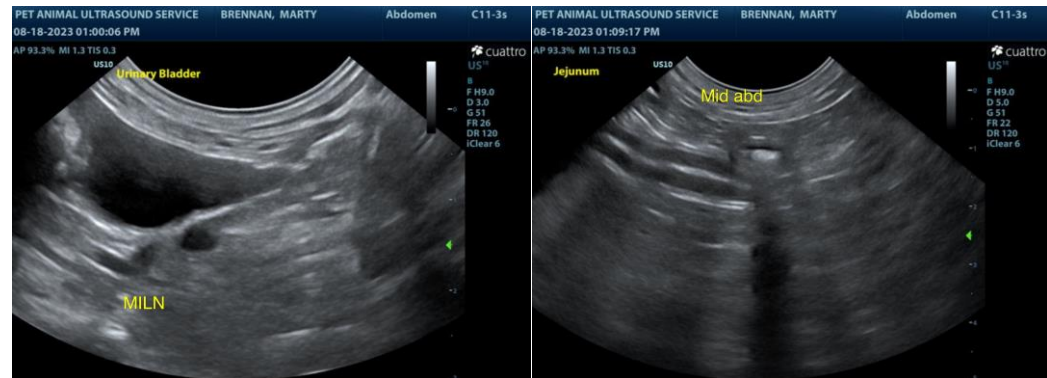
**AGE**

6yr

Overall, there is no overt evidence of significant abdominal visceral pathology as a definitive cause of the patient's clinical signs. No evidence of intra-abdominal neoplastic or metastatic criteria. The gallbladder debris is likely incidental assuming no evidence of hepatic enzyme elevations or cholestasis. Abdominal sonographic monitoring based on oncology recommendations is advised.

**WEIGHT**

14lb

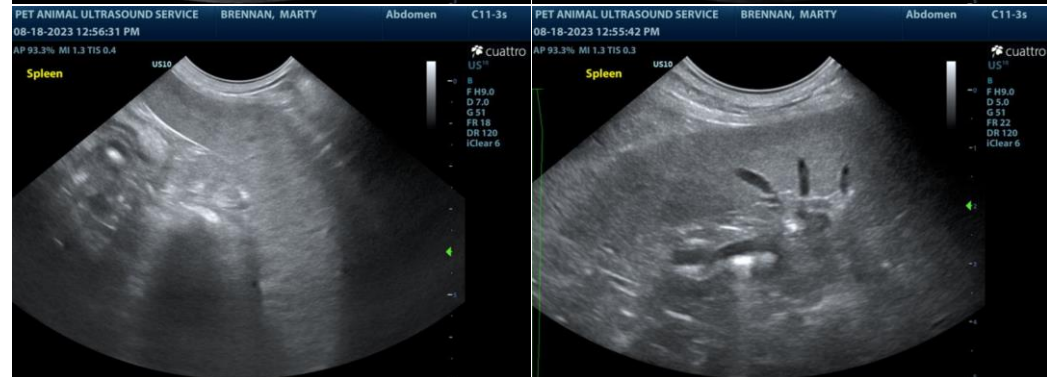

**INTERPRETED BY**

R. McKenzie Daniel, DVM,  
 DABVP (Canine and Feline)

**IMAGING PERFORMED BY**

Pamela Harrigan, RDCS



**HOSPITAL NAME**

Airport Animal Hospital

**REFERRING VET**

Asha Gudluru, DVM

**INVOICE**

14673ag

**DATE**

08/20/2023



**PATIENT**

Marty Brennan

**SPECIES**

Canine

**BREED**

Terrier Mix

**SEX**

MN

**AGE**

6yr

**WEIGHT**

14lb

**INTERPRETED BY**

R. McKenzie Daniel, DVM,  
 DABVP (Canine and Feline)

**IMAGING PERFORMED BY**

Pamela Harrigan, RDCS

**HOSPITAL NAME**

Airport Animal  
 Hospital

**REFERRING VET**

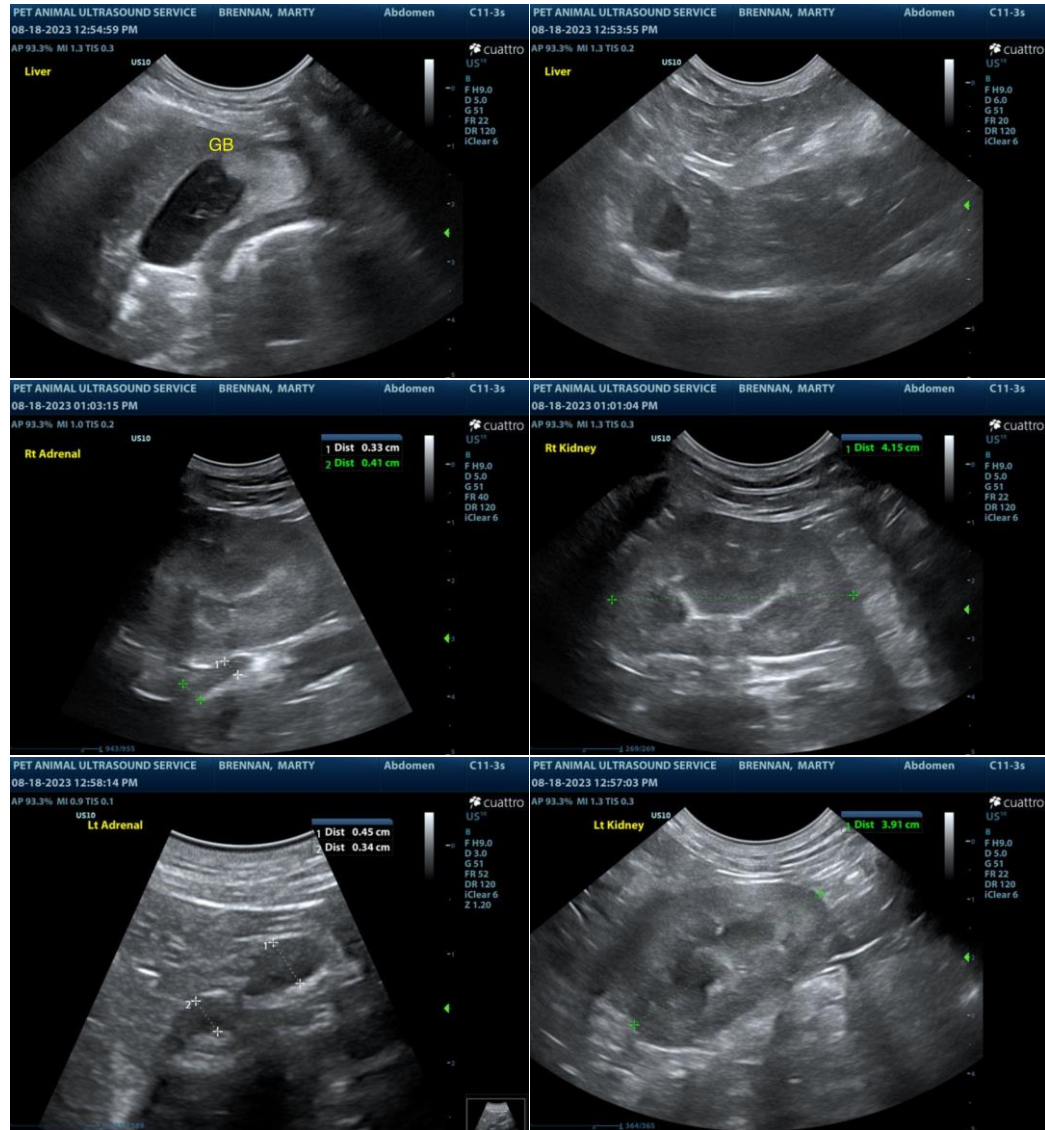
Asha Gudluru, DVM

**INVOICE**

14673ag

**DATE**

08/20/2023



The information and recommendations provided are based on the images presented by the referring veterinarian/sonographer. No evaluation can be communicated regarding pathology that was not visible in the image/video clips provided.

Thank you for this referral. If the clinical or image interpretation does not parallel your findings or if I can be of any further assistance please contact me.

R. McKenzie Daniel, DVM, DABVP (Canine / Feline Practice)

info@SonoPath.com