

**PATIENT**

Jenny Gott

SPECIES

Canine

BREED

Lab

SEX

SF

AGE

14 Years

WEIGHT

80 lbs

INTERPRETED BYR. McKenzie Daniel,
DVM, DABVP
(Canine and Feline)**IMAGING
PERFORMED BY**

Sarah Pender, CVT

HOSPITAL NAME

SVS Imaging QC

REFERRING VET

Dr. Molly Bies

INVOICE

47055

DATE

8-20-21

PRESENTING CLINICAL SIGNS

Presented for having blood in her stool over the weekend, with some loose stool. Appetite fine, no vomiting but was eating grass.

Abnormal PE/Chem/CBC/UA Results: Mild abdominal distension, a couple of areas possibly suspicious for masses (area of liver and/or pylorus and spleen). Blood work showed HCT 39.0% with low MCV and MCH, mild elevation in ALKP (329 U/L), and mildly decreased TT4 (0.9 ug/dL)

ULTRASONOGRAPHIC EXAMINATION OF THE ABDOMEN***Urinary System***

The urinary bladder, trigone, cystourethral junction, and visible pelvic urethra to a depth of 3.0 cm exhibited normal thickness and tone. Anechoic urine was present in the lumen with no uroliths or sediment. The ureteral papillae were normal. The ureters were not visible which is normal. No evidence of inflammatory or neoplastic changes were noted.

No evidence of pathology in the area of the aortic trifurcation.

Normal size and margination was present in the kidneys. A normal 1:3 cortex / medulla ratio was maintained. The medulla and cortices were uniform in texture with some increased echogenicity and mild loss of corticomedullary symmetry and definition expected for the age of the patient. No evidence of pelvic dilation was present. The left kidney measured 8.0 cm in length. The right kidney measured 8.0 cm in length.

Adrenal Glands

The left adrenal gland was uniform in size and contour with a uniformly hypoechoic parenchyma. The left adrenal gland measured 0.82 cm width at the caudal pole and 0.62 cm width at the cranial pole. The right adrenal gland was uniform in size and contour with a uniformly hypoechoic parenchyma. The right adrenal gland measured 0.61 cm width at the caudal pole and 0.75 cm width at the cranial pole.

Spleen

The spleen exhibited primarily finely textured parenchyma which was hyperechoic to the liver and renal cortical parenchyma. Mild generalized parenchyma heterogeneity was present without evidence of nodular changes. The capsule was smooth and regular without apparent expansion. The splenic vasculature at the hilus was normal in volume with no evidence of congestion or thrombosis. The parenchymal heterogeneity is likely consistent with benign changes such as extramedullary hematopoiesis or age related remodeling with minor potential for inflammatory or neoplastic disease. No splenic masses or nodules were noted.

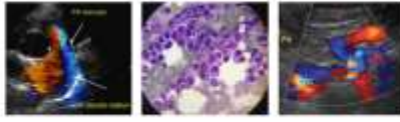Liver / Gallbladder

The liver was subjectively normal in size, structure, and contour. The liver parenchyma was mildly nonuniform and hypoechoic to the spleen with a moderate coarse echotexture and subjective mild to benign parenchymal remodeling. The hepatic and portal vasculature were normal in appearance without signs of congestion.

The gallbladder was non-distended in size with thin walls and primarily anechoic luminal content. The cystic and common bile ducts were normal.

Gastrointestinal

The stomach presented intact wall layering with a normal wall layer ratio. The lumen of the stomach was empty with no signs of ileus, obstruction or foreign material. The pylorus wall width measured 0.60 cm.

**PATIENT**

Jenny Gott

The small intestine presented intact wall layering with 1:3 muscularis/mucosa ratio. The lumen of the small intestine was empty with no signs of ileus, obstruction or foreign material. The jejunum wall width measured 0.35 cm.

SPECIES

Canine

The colon exhibited intact yet subjective minor prominent walls. The colon was non-distended containing subjective semi-formed feces.

Pancreas**BREED**

Lab

The parenchyma of the left limb, body and right limb of the pancreas presented isoechoic to the adjacent omental fat. A normal curvilinear capsule contour of the pancreas was present. The visible pancreatic duct was normal. No signs of active inflammation or neoplastic disease was evident.

Free Abdomen**SEX**

SF

No evidence of intraabdominal masses, lymphadenopathy, or peritoneal effusion were present.

ULTRASONOGRAPHIC FINDINGS**AGE**

14 Years

- Mild colitis.
- Mild vacuolar hepatopathy pattern with mild hepatic parenchymal remodeling.
- Mild age related kidneys.

WEIGHT

80 lbs

INTERPRETATION OF THE FINDINGS & FURTHER RECOMMENDATIONS

Largely geriatric abdomen without evidence of significant visceral pathology. No evidence of intraabdominal neoplasia noted.

INTERPRETED BY

R. McKenzie Daniel,
DVM, DABVP
(Canine and Feline)

Supportive care for mild colitis given the loose stool and hemochezia is recommended. Continued monitoring of the cbc/hematocrit recommended.

IMAGING PERFORMED BY

Sarah Pender, CVT

HOSPITAL NAME

SVS Imaging QC

REFERRING VET

Dr. Molly Bies

INVOICE

47055

DATE

8-20-21

IMAGING PERFORMED BY

svs.com | 800-337-3070



Clinical Sonography & Telectyology

EDUCATIONAL TELECONSULTATION SERVICES™

1-800-838-4288 | info@sonopath.com | SonoPath.com

PATIENT

Jenny Gott

SPECIES

Canine

BREED

Lab

SEX

SF

AGE

14 Years

WEIGHT

80 lbs

INTERPRETED BY

R. McKenzie Daniel,
DVM, DABVP
(Canine and Feline)

IMAGING PERFORMED BY

Sarah Pender, CVT

HOSPITAL NAME

SVS Imaging QC

REFERRING VET

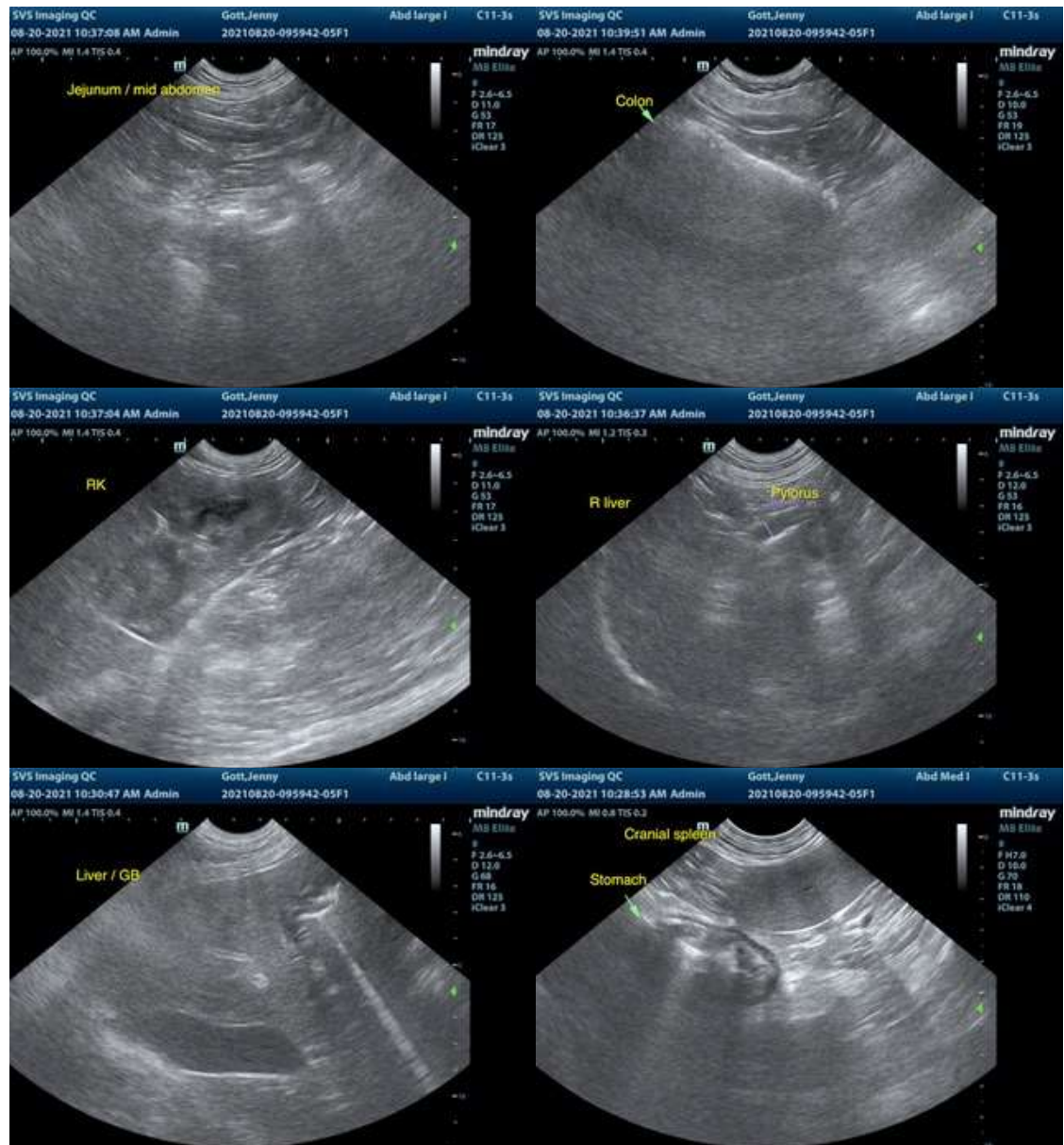
Dr. Molly Bies

INVOICE

47055

DATE

8-20-21





PATIENT

Jenny Gott

SPECIES

Canine

BREED

Lab

SEX

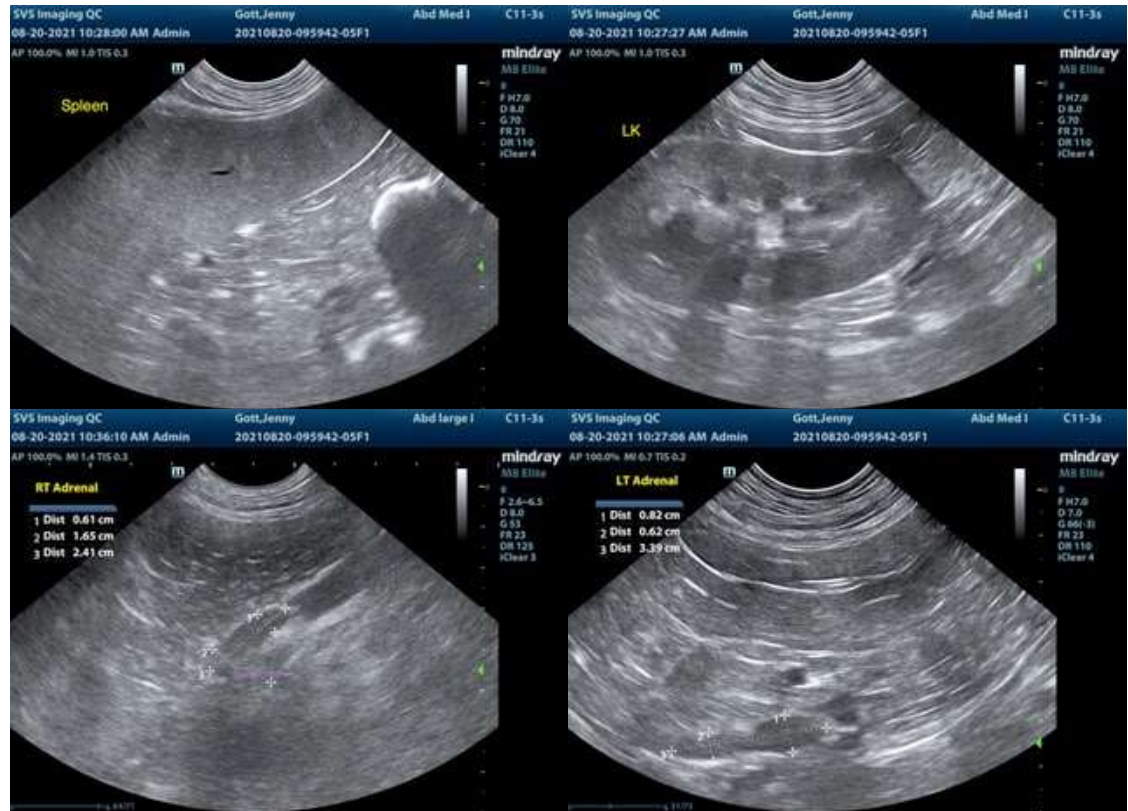SF

AGE

14 Years

WEIGHT

80 lbs



INTERPRETED BY

R. McKenzie Daniel,
DVM, DABVP
(Canine and Feline)

IMAGING PERFORMED BY

Sarah Pender, CVT

HOSPITAL NAME

SVS Imaging QC

REFERRING VET

Dr. Molly Bies

INVOICE

47055

DATE

8-20-21

The information and recommendations provided are based on the images presented by the referring veterinarian. No evaluation can be communicated regarding pathology that was not visible in the image/video clips provided.

Thank you for this referral. If the clinical or image interpretation does not parallel your findings or if I can be of any further assistance please contact me.

R. McKenzie Daniel, DVM, DABVP (Canine / Feline Practice)
info@SonoPath.com