



**PATIENT**

Thomas Cardona

**SPECIES**

Canine

**BREED**

Schnauer Mini

**SEX**

MN

**AGE**

15 years

**WEIGHT**

13.2 lbs.

**INTERPRETED BY**

R. McKenzie Daniel,  
DVM, DABVP  
(Canine and Feline)

**IMAGING PERFORMED BY**

Dr. Kim

**HOSPITAL NAME**

Ridgefield Park AH

**REFERRING VET**

Dr. Kim

**INVOICE**

14478

**DATE**

8/2/22

**PRESENTING CLINICAL SIGNS**

Patient presented to the hospital due to GI signs. He vomited once a few days ago and had diarrhea with some blood spots. He has continued with diarrhea, no blood anymore, however he has been lethargic and did not want to eat anything this morning. Has been losing weight.

**ULTRASONOGRAPHIC EXAMINATION OF THE ABDOMEN**

**Urinary System**

The urinary bladder, trigone, cystourethral junction, and visible pelvic urethra to a depth of 2.0 cm exhibited normal thickness and tone. Anechoic urine was present in the lumen with no uroliths or sediment. The ureteral papillae were normal. The ureters were not visible which is normal. No evidence of inflammatory or neoplastic changes was noted.

The residual prostate was symmetrically normal in size with subtle nonhomogeneous parenchyma and likely consistent with age-related residual prostatic parenchymal changes, measuring 1.2 cm in diameter. No overt evidence of pathology was noted.

The area of the aortic trifurcation was free of pathology.

Normal size and margination were present in the kidneys. A normal 1:3 cortex / medulla ratio was maintained. The medulla and cortices were uniform in texture with some increased echogenicity and mild loss of corticomedullary symmetry and definition expected for the age of the patient. Minor areas of medullary mineralization were present in both kidneys. No evidence of pelvic dilation was present. The left kidney measured 4.3 cm in length. The right kidney measured 4.6 cm in length.

**Adrenal Glands**

The left adrenal gland was uniform in size and contour with a uniformly hypoechoic parenchyma. The left adrenal gland measured 0.57 cm width at the caudal pole and 0.62 cm width at the cranial pole. The right adrenal gland was uniform in size and contour with a uniformly hypoechoic parenchyma. The right adrenal gland measured 0.59 cm width at the caudal pole and 0.62 cm width at the cranial pole.

**Spleen**

The spleen exhibited a finely textured and homogenous parenchyma which was hyperechoic to the liver and renal cortical parenchyma. The capsule was smooth and regular without apparent expansion. The splenic vasculature at the hilus was normal in volume with no evidence of congestion or thrombosis. Acute to chronic inflammatory, neoplastic, or benign parenchyma changes were not noted.

**Liver/ Gallbladder**

The liver was mildly enlarged in size with normal structure and contour. The liver parenchyma was mildly nonuniform and hypoechoic to the spleen with a moderate coarse echotexture and subjective mild to benign parenchymal remodeling. The hepatic and portal vasculature were normal in appearance without signs of congestion. The gallbladder was mildly distended containing moderate, non-dependent to organized mildly hyperechoic gallbladder debris. The gallbladder walls were sonographically normal without evidence of gallbladder or peripheral gallbladder inflammatory criteria.



**PATIENT**

***Gastrointestinal***

Thomas Cardona

The stomach presented intact wall layering with a normal wall layer ratio. The lumen of the stomach was empty with no signs of ileus, obstruction, or foreign material. The gastric body wall width measured 0.35 cm.

**SPECIES**

Canine

The small intestine presented intact yet mildly prominent wall layering exhibiting mild segmental to generalized mucosal speckling. The duodenum wall measured 0.36 cm width. The jejunum wall measured 0.30 cm width.

**BREED**

Schnauer Mini

Normal visible colon wall layers were present. The colon lumen was empty exhibiting subjective intact yet mildly prominent wall layering.

**SEX**

MN

***Pancreas***

**AGE**

15 years

The parenchyma of the pancreas was hyperechoic to adjacent omental fat with diffuse parenchyma remodeling. The capsule of the pancreas was mildly asymmetrical in contour without evidence of peripancreatic inflammation. These changes may suggest chronic inflammation, fibrosis, or saponification if previous history of pancreatitis. No overt signs of pancreatic neoplasia.

**WEIGHT**

13.2 lbs.

***Free Abdomen***

No overt lymphadenopathy or peritoneal effusion was present.

**INTERPRETED BY**

R. McKenzie Daniel,  
DVM, DABVP  
(Canine and Feline)

**ULTRASONOGRAPHIC FINDINGS**

- Intact yet mild prominent small bowel and colon walls exhibiting small bowel mucosal speckling - enterocolitis pattern, potential for inflammatory bowel
- Gallbladder mucocele
- Mild hepatomegaly exhibiting minor parenchymal remodeling - benign
- Mild chronic renal changes with minor medullary mineral
- Chronic pancreatitis pattern

**IMAGING PERFORMED BY**

Dr. Kim

**HOSPITAL NAME**

Ridgefield Park AH

**INTERPRETATION OF THE FINDINGS & FURTHER RECOMMENDATIONS**

Dietary indiscretion / food intolerance, IBD, dysbiosis, occult parasitism, or less likely early Intestinal neoplasia are all potentials. Chronic pancreatitis may potentially be a contributing factor to the patient's gastrointestinal signs. Further assessment may include a GI panel to include PLI/TLI/Cobalamin/Folate.

**REFERRING VET**

Dr. Kim

**INVOICE**

14478

Full CBC / Chemistry panel and urinalysis with hepatic enzyme assessment is recommended if not recently done. Three-view chest radiographs are suggested to rule out occult pathology as a contributing factor for the patient's weight loss.

**DATE**

8/2/22

Empirically, a limited antigen or hydrolyzed diet trial with potential long term dietary therapy, prophylactic deworming (Panacur 50 mg/kg SID x 5 consecutive days with repeat protocol in 3 weeks even if fecal testing is negative), high colony count probiotic (Provable or Visbiome), antibiotic trial and as needed gastrointestinal support with assessment of clinical response may prove beneficial. Intestinal biopsies may be indicated if GI signs continue despite empirical therapy.



## PATIENT

Thomas Cardona

## SPECIES

Canine

## BREED

Schnauer Mini

## SEX

MN

## AGE

15 years

## WEIGHT

13.2 lbs.

## INTERPRETED BY

R. McKenzie Daniel,  
DVM, DABVP  
(Canine and Feline)

## IMAGING PERFORMED BY

Dr. Kim

## HOSPITAL NAME

Ridgefield Park AH

## REFERRING VET

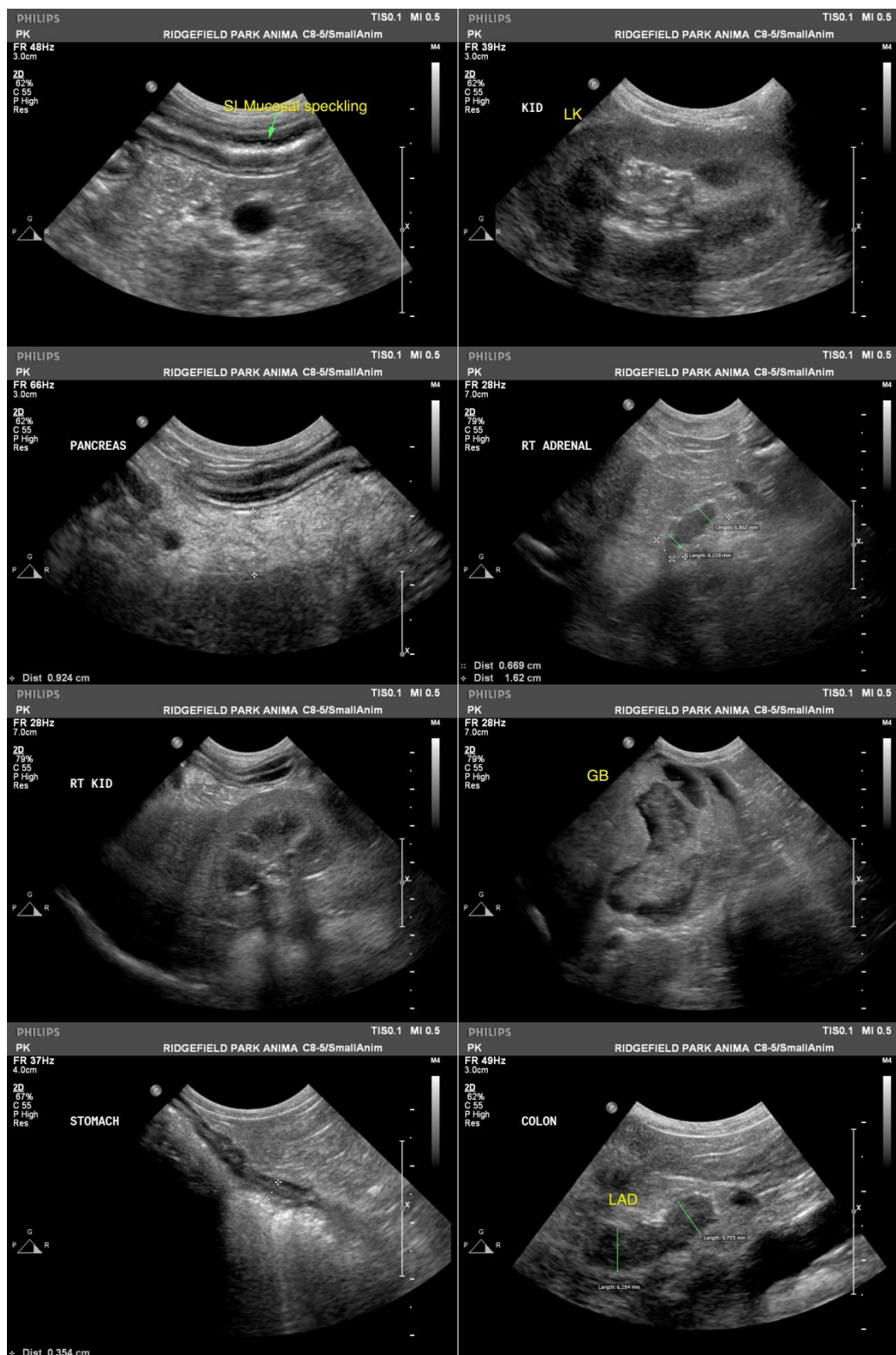
Dr. Kim

## INVOICE

14478

## DATE

8/2/22





**PATIENT**

Thomas Cardona

**SPECIES**

Canine

**BREED**

Schnauer Mini

**SEX**

MN

**AGE**

15 years

**WEIGHT**

13.2 lbs.

**INTERPRETED BY**

R. McKenzie Daniel,  
DVM, DABVP  
(Canine and Feline)

**IMAGING  
PERFORMED BY**

Dr. Kim

**HOSPITAL NAME**

Ridgefield Park AH

**REFERRING VET**

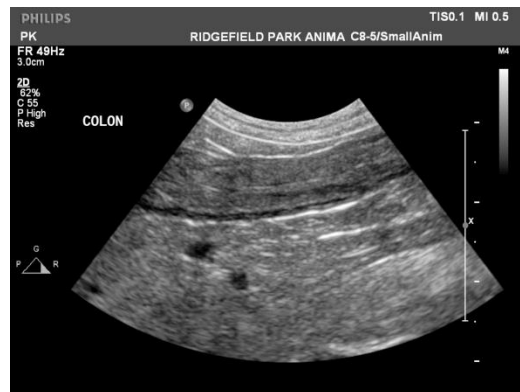Dr. Kim

**INVOICE**

14478

**DATE**

8/2/22



**The information and recommendations provided are based on the images presented by the referring veterinarian/sonographer. No evaluation can be communicated regarding pathology that was not visible in the image/video clips provided.**

Thank you for this referral. If the clinical or image interpretation does not parallel your findings or if I can be of any further assistance please contact me.

**R. McKenzie Daniel, DVM, DABVP (Canine / Feline Practice)**  
**info@SonoPath.com**