



PATIENT

Mason Andrews

SPECIES

Canine

BREED

Cockapoo

SEX

Male Neuter

AGE

11

WEIGHT

11 kg

INTERPRETED BY

R. McKenzie Daniel,
DVM, DABVP
(Canine and Feline)

**IMAGING
PERFORMED BY**

Dr. Belan

HOSPITAL NAME
Healing Traditions
VC

REFERRING VET

Dr. Gerrow

INVOICE

14468

DATE

8/2/22

PRESENTING CLINICAL SIGNS

Licking anus- hard perianal mass on left side detected on exam 3.5 cm in diameter. Concern about possible metastasis.

Abnormal PE/Chem/CBC/UA Results: Chest X-rays pending FNA of perianal mass taken by attending waiting for results.

ULTRASONOGRAPHIC EXAMINATION OF THE ABDOMEN

Urinary System

The urinary bladder, trigone, cystourethral junction, and visible pelvic urethra to a depth of 2.0 cm exhibited normal thickness and tone. Anechoic urine was present in the lumen with no uroliths or sediment. The ureteral papillae were normal. The ureters were not visible which is normal. No evidence of inflammatory or neoplastic changes was noted.

The residual prostate was symmetrically normal in size with uniform parenchyma and slight coarse echotexture measuring 0.75 cm in diameter.

Multiple variably enlarged to variably echogenic medial iliac and sublumbar lymph nodes were present in the area of the iliac trifurcation and sublumbar space. An example of a medial iliac lymph node measured 2.4 cm x 0.82 cm.

Normal size and margination were present in the kidneys. A normal 1:3 cortex / medulla ratio was maintained. The medulla and cortices were uniform in texture with some increased echogenicity and mild loss of corticomedullary symmetry and definition expected for the age of the patient. No evidence of pelvic dilation was present. The left kidney measured 4.7 cm in length. The right kidney measured 5.4 cm in length.

Adrenal Glands

The left adrenal gland was uniform in size and contour with a uniformly hypoechoic parenchyma. The left adrenal gland measured 0.68 cm width at the caudal pole and 0.76 cm width at the cranial pole. The right adrenal gland was uniform in size and contour with a uniformly hypoechoic parenchyma. The right adrenal gland measured 0.50 cm width at the caudal pole and 0.44 cm width at the cranial pole.

Spleen

The spleen exhibited subjective mild enlargement yet maintained symmetrical capsule contour. Generalized mild parenchyma heterogeneity was noted along with normal vascularity. No distinct splenic masses or nodules were noted.

Liver/ Gallbladder

The liver exhibited potential for mild generalized enlargement and maintained symmetrical to mildly rounded hepatic capsule contour. Generalized nonuniform mildly echogenic parenchyma exhibiting intermittent discrete nondisruptive hypoechoic hepatic nodules was noted. An example of a liver nodule measured 1.2 cm in diameter. The gallbladder was non-distended in size with thin walls and primarily anechoic luminal content. The cystic and common bile ducts were normal.



PATIENT

Mason Andrews

SPECIES

Canine

BREED

Cockapoo

SEX

Male Neuter

AGE

11

WEIGHT

11 kg

INTERPRETED BY

R. McKenzie Daniel,
DVM, DABVP
(Canine and Feline)

**IMAGING
PERFORMED BY**

Dr. Belan

HOSPITAL NAME

Healing Traditions
VC

REFERRING VET

Dr. Gerrow

INVOICE

14468

DATE

8/2/22

Gastrointestinal

The stomach presented intact wall layering with a normal wall layer ratio. The lumen of the stomach contained mild nonshadowing ingesta/chyme most consistent with post prandial presentation without signs of ileus, obstruction or foreign material.

The small intestine presented intact wall layering with 1:3 muscularis/mucosa ratio. The lumen of the small intestine was empty with no signs of ileus, obstruction, or foreign material.

Normal visible colon wall layers were present with subjective semi-formed fecal matter.

Pancreas

The parenchyma of the left limb, body, and right limb of the pancreas presented isoechoic to the adjacent omental fat. A normal curvilinear capsule contour of the pancreas was present. The visible pancreatic duct was normal. No signs of active inflammation or neoplastic disease were evident.

Free Abdomen

Intermittent nonhomogeneous mildly enlarged concurrent mesenteric lymph nodes were present with an example measuring 1.6 cm in diameter.

ULTRASONOGRAPHIC FINDINGS

- Multiple variably enlarged to echogenic medial iliac / sublumbar lymphadenopathy
- Concurrent intermittent nonhomogeneous mesenteric lymphadenopathy
- Mild chronic renal changes
- Subjective mild splenomegaly exhibiting generalized mild heterogeneous parenchyma
- Nonuniformly echogenic to discretely nodular liver

INTERPRETATION OF THE FINDINGS & FURTHER RECOMMENDATIONS

Although sampling is required for further assessment, given the presence of the perianal mass and pending cytology, the medial iliac and sublumbar lymphadenopathy is strongly concerning for metastatic lymphadenopathy, while potential for lymphoid hyperplasia or lymphadenitis is possible. Concurrent metastatic mesenteric lymphadenopathy cannot be excluded.

The hepatosplenic changes may indicate benign etiologies, although the possibility of concurrent hepatic or hepatosplenic metastasis could be possible. Further assessment may include ultrasound-guided FNA of an enlarged medial iliac lymph node, as well as screening hepatosplenic FNA for further staging. Oncology consult pending perianal mass cytology, if neoplastic process is confirmed, is recommended.



PATIENT

Mason Andrews

SPECIES

Canine

BREED

Cockapoo

SEX

Male Neuter

AGE

11

WEIGHT

11 kg

INTERPRETED BY

R. McKenzie Daniel,
DVM, DABVP
(Canine and Feline)

IMAGING PERFORMED BY

Dr. Belan

HOSPITAL NAME

Healing Traditions
VC

REFERRING VET

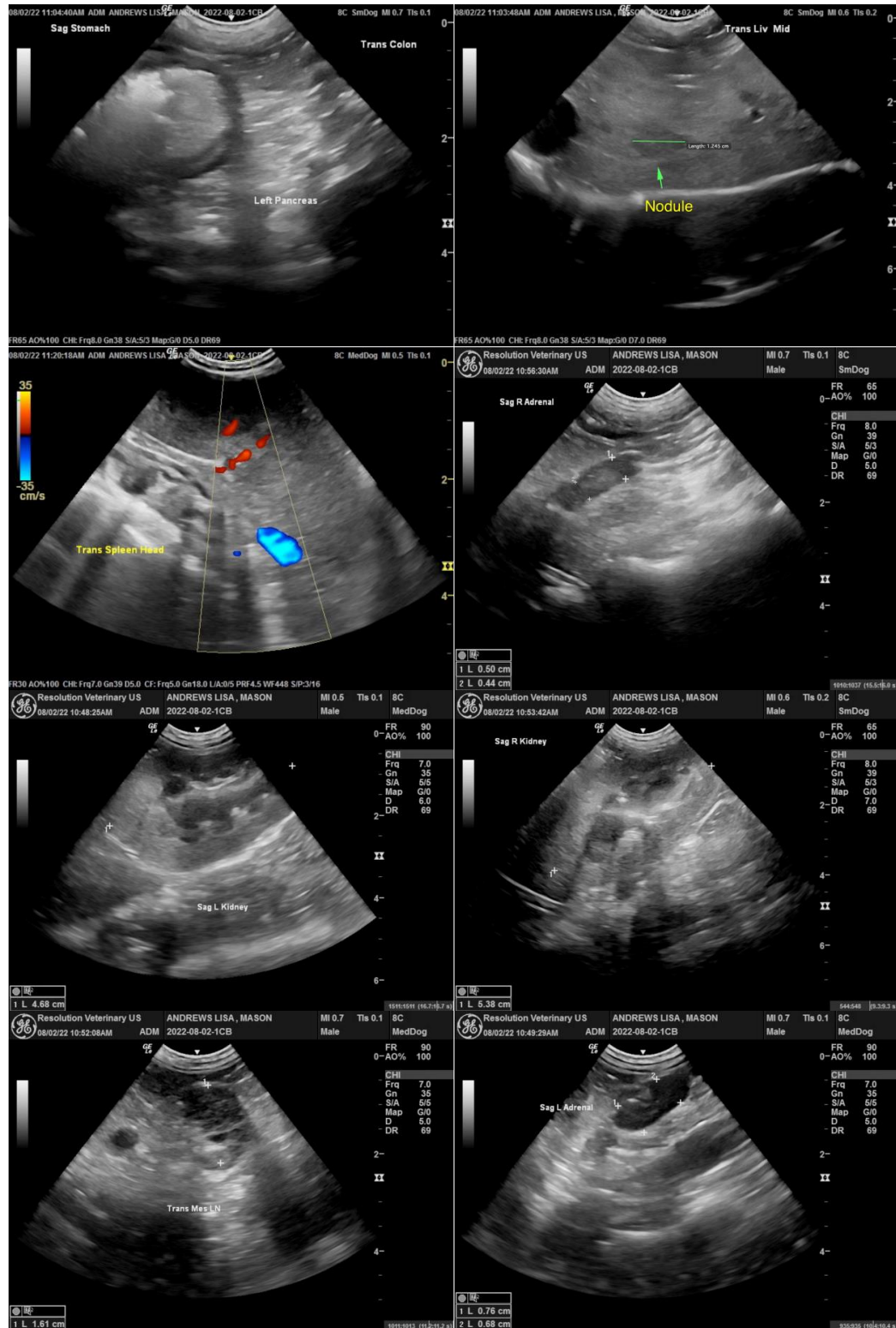
Dr. Gerrow

INVOICE

14468

DATE

8/2/22





PATIENT

Mason Andrews

SPECIES

Canine

BREED

Cockapoo

SEX

Male Neuter

AGE

11

WEIGHT

11 kg

INTERPRETED BY

R. McKenzie Daniel,
DVM, DABVP
(Canine and Feline)

IMAGING PERFORMED BY

Dr. Belan

HOSPITAL NAME

Healing Traditions
VC

REFERRING VET

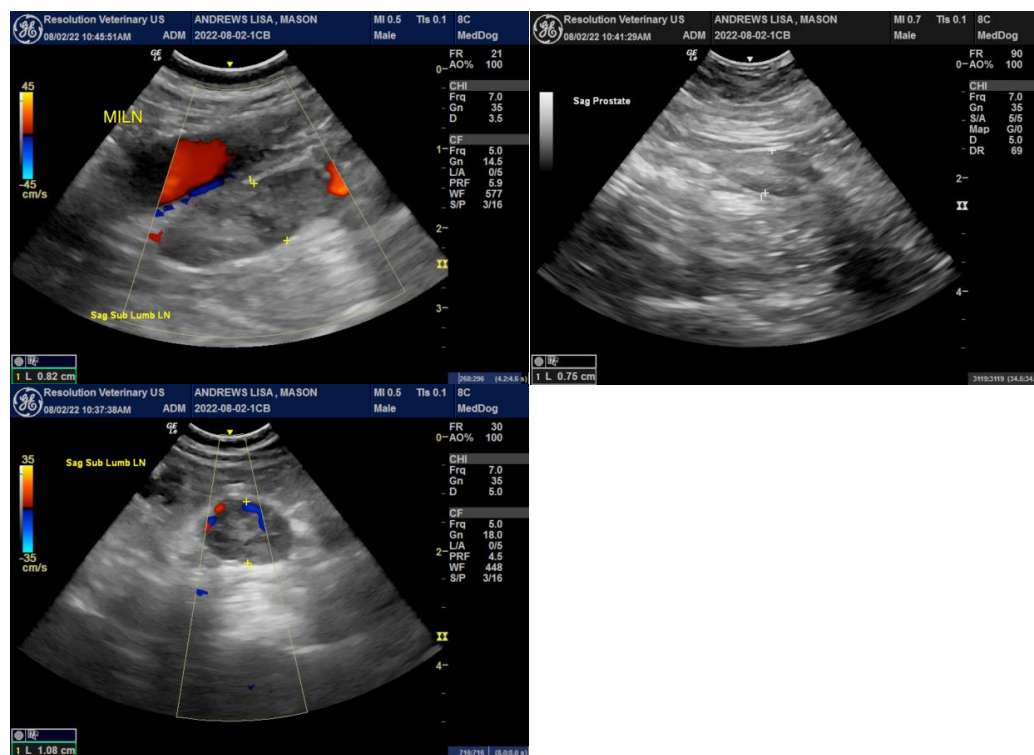
Dr. Gerrow

INVOICE

14468

DATE

8/2/22



The information and recommendations provided are based on the images presented by the referring veterinarian/sonographer. No evaluation can be communicated regarding pathology that was not visible in the image/video clips provided.

Thank you for this referral. If the clinical or image interpretation does not parallel your findings or if I can be of any further assistance please contact me.

R. McKenzie Daniel, DVM, DABVP (Canine / Feline Practice)
info@SonoPath.com