



PATIENT PRESENTING CLINICAL SIGNS

Juniper Mattinson

History: Vomiting 2-4 times daily for the last 2 weeks. Energy is up and down. Mild-moderately decreased appetite. No current meds.

SPECIES

Abnormal PE/Chem/CBC/UA Results: CBC/CHem/Lytes all WNL. Fecal Float negative.

Canine

ULTRASONOGRAPHIC EXAMINATION OF THE ABDOMEN

BREED

Standard Poodle

Urinary System

The urinary bladder, trigone, cystourethral junction, and visible pelvic urethra to a depth of 3 cm exhibited normal thickness and tone. Anechoic urine was present in the lumen with no uroliths or sediment. The ureteral papillae were normal. The ureters were not visible which is normal. No evidence of inflammatory or neoplastic changes were noted.

SEX

FS

Normal size and margination were present in the kidneys. A normal 1:3 cortex / medulla ratio and normal corticomedullary definition were maintained. The echogenicity of the cortex was similar to or slightly less than normal liver parenchyma while the medulla echogenicity was hypoechoic to the cortex with no evidence of pelvic dilation. The left kidney measured 4.8 cm in length. The right kidney measured 5.0 cm in length.

AGE

1yr

The area of the aortic trifurcation was free of pathology.

WEIGHT

19.3kg

Adrenal Glands

The left adrenal gland was uniform in size and contour with a uniformly hypoechoic parenchyma. The left adrenal gland measured 0.49 cm width at the caudal pole and 1.9 cm length. The right adrenal gland was uniform in size and contour with a uniformly hypoechoic parenchyma. The right adrenal gland measured 0.61 cm width at the caudal pole and 1.4 cm length.

INTERPRETED BY

R. McKenzie Daniel,
DVM, DABVP
(Canine and Feline)

Spleen

The spleen exhibited a finely textured and homogenous parenchyma which was hyperechoic to the liver and renal cortical parenchyma. The capsule was smooth and regular without apparent expansion. The splenic vasculature at the hilus was normal in volume with no evidence of congestion or thrombosis. Acute to chronic inflammatory, neoplastic, or benign parenchyma changes were not noted.

IMAGING PERFORMED BY

Crystal Hill

Liver

The liver was subjectively normal in size, structure, and contour. The liver parenchyma was uniform and hypoechoic to the spleen with a mild coarse echotexture. The hepatic and portal vasculature were normal in appearance without signs of congestion. The gallbladder was non-distended in size with thin walls and primarily anechoic luminal content. The cystic and common bile ducts were normal.

HOSPITAL NAME

New Hamburg Vet
Clinic

REFERRING VET

Dr. Schroder

Gastrointestinal

The stomach presented intact yet prominent wall layering with prominent gastric mucosa. The lumen of the stomach was empty with no signs of ileus, obstruction or foreign material.

INVOICE

11427ag

The small intestine presented intact wall layering with 1:3 muscularis/mucosa ratio. The lumen of the small intestine was empty with no signs of ileus, obstruction or foreign material. The duodenum wall measured 0.40 cm. The jejunum wall measured 0.35 cm.

DATE

08/19/2022

Normal visible colon wall layers were present with apparent formed feces in lumen.



PATIENT

Pancreas

Juniper Mattinson

The parenchyma of the left limb, body and right limb of the pancreas presented isoechoic to the adjacent omental fat. A normal curvilinear capsule contour of the pancreas was present. The visible pancreatic duct was normal. No signs of active inflammation or neoplastic disease was evident.

SPECIES

Canine

Free Abdomen

No overt lymphadenopathy or peritoneal effusion was present.

BREED

Standard Poodle

ULTRASONOGRAPHIC FINDINGS

- Gastritis pattern
- Overtly normal small bowel
- Unremarkable pancreas

SEX

FS

INTERPRETATION OF THE FINDINGS & FURTHER RECOMMENDATIONS

The appearance of the gastrointestinal tract was non-specific with considerations including dietary intolerance / food hypersensitivity, occult parasitism, gastritis, inflammatory bowel disease without evidence of mural changes or other. A GI panel to include PLI/TLI/Cobalamin/Folate, fresh fecal analysis to assess for parasitic ova / Giardia and resting cortisol to rule out occult Addison's Disease is warranted.

AGE

1yr

A clinical trial of **Zithromax (Dogs: 5-10 mg/kg p.o. q24h. May increase dosing interval to q48h after 3-5 days of treatment)**, **Metronidazole (10-20 mg/kg p.o. b.i.d.)**, **Pepcid (0.5-1 mg/kg s.i.d.)** and **Sucralfate (0.5-2 g/dog PO)** or **Omeprazole (1 mg/kg p.o. s.i.d.)** over the next 3 weeks along with a **novel-protein or hydrolyzed diet** with slurry feeding b.i.d./t.i.d. over the next 2-4 days and then increase to canned diet bid. Dry food should be avoided over the next 4 weeks. A recheck sonogram to assess GI improvement or progression would be ideal in 4 weeks.

WEIGHT

19.3kg

INTERPRETED BY

R. McKenzie Daniel,
DVM, DABVP
(Canine and Feline)

Prophylactic deworming (Panacur 50 mg/kg SID x 5 consecutive days with repeat protocol in 3 weeks even if fecal testing is negative) and high colony count probiotic (Proviale or Visbiome) may prove beneficial.

IMAGING PERFORMED BY

Crystal Hill

Gastric endoscopy may be indicated if persistent vomiting despite therapy.

HOSPITAL NAME

New Hamburg Vet
Clinic

REFERRING VET

Dr. Schroder

INVOICE

11427ag

DATE

08/19/2022



PATIENT

Juniper Mattinson

SPECIES

Canine

BREED

Standard Poodle

SEX

FS

AGE

1yr

WEIGHT

19.3kg

INTERPRETED BY

R. McKenzie Daniel,
DVM, DABVP
(Canine and Feline)

IMAGING PERFORMED BY

Crystal Hill

HOSPITAL NAME

New Hamburg Vet
Clinic

REFERRING VET

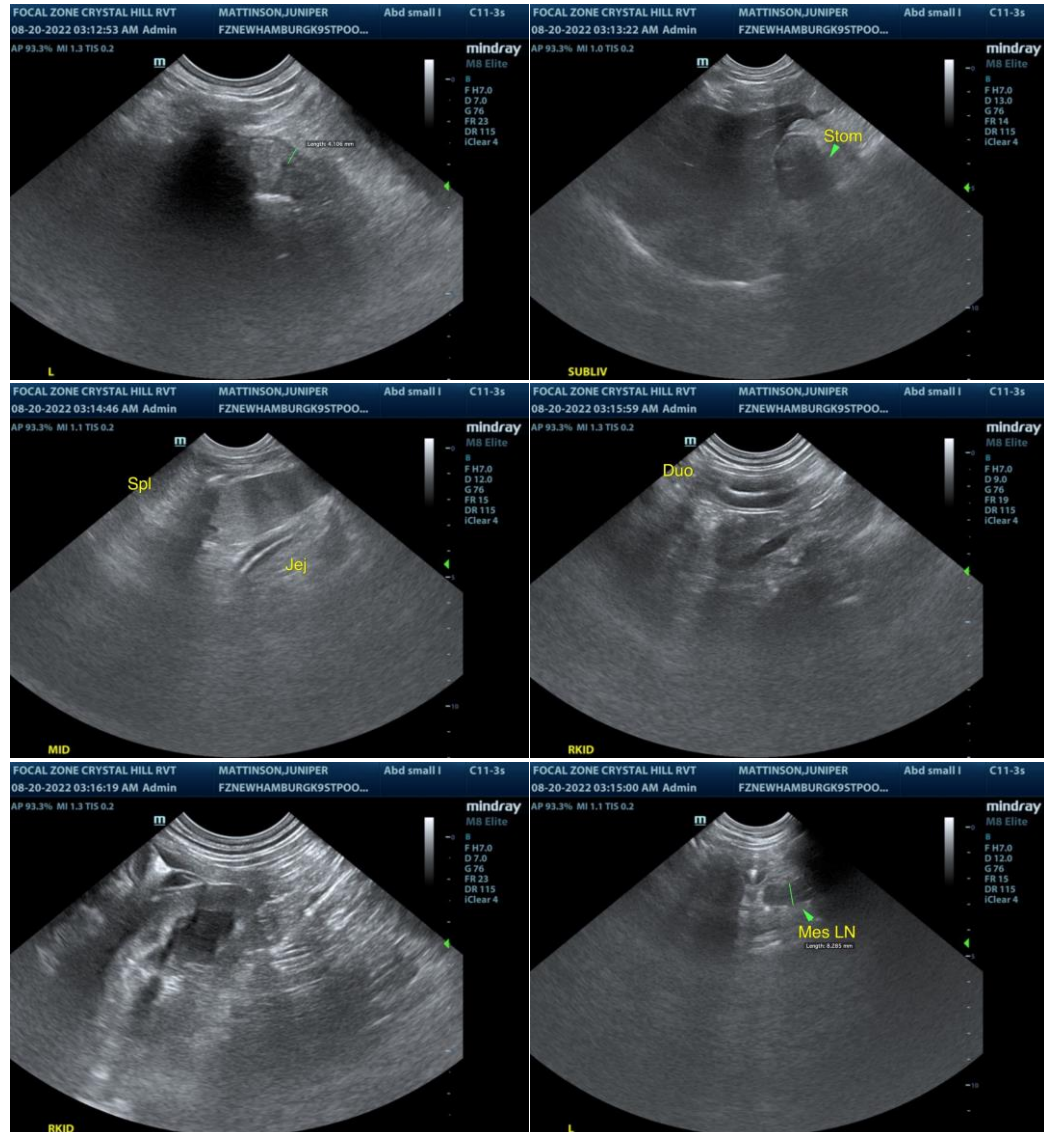
Dr. Schroder

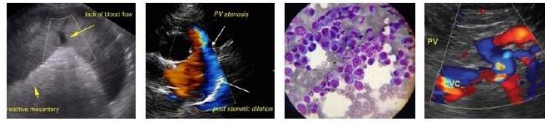
INVOICE

11427ag

DATE

08/19/2022





PATIENT
Juniper Mattinson

SPECIES
Canine

BREED
Standard Poodle

SEX
FS

AGE
1yr

WEIGHT
19.3kg

INTERPRETED BY

R. McKenzie Daniel,
DVM, DABVP
(Canine and Feline)

IMAGING PERFORMED BY

Crystal Hill

HOSPITAL NAME

New Hamburg Vet
Clinic

REFERRING VET

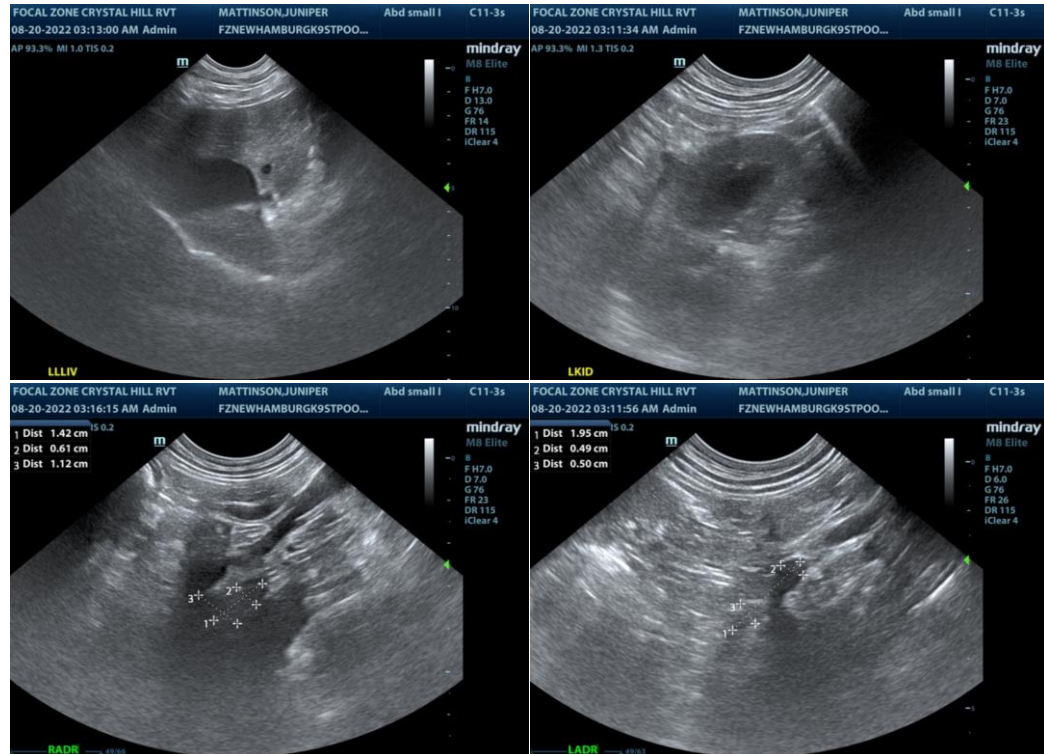
Dr. Schroder

INVOICE

11427ag

DATE

08/19/2022



The information and recommendations provided are based on the images presented by the referring veterinarian/sonographer. No evaluation can be communicated regarding pathology that was not visible in the image/video clips provided.

Thank you for this referral. If the clinical or image interpretation does not parallel your findings or if I can be of any further assistance please contact me.

R. McKenzie Daniel, DVM, DABVP (Canine / Feline Practice)

info@SonoPath.com