



**PATIENT PRESENTING CLINICAL SIGNS**

Dr. Peterson Huggins

History: 3 week history of reduced energy, increased thirst. Abdomen is slightly enlarged on exam with muscle loss along dorsum. No pain on exam, no masses palpated in abdomen.

**SPECIES**

Canine

Abnormal PE/Chem/CBC/UA Results: Glucose 334, ALT 194, AST 103, ALP 1683, GGT 29 all elevated. 3 plus urine glucose. Current Medications NOne

**BREED**

Terrier Mix

**ULTRASONOGRAPHIC EXAMINATION OF THE ABDOMEN**

**Urinary System**

**SEX**

MN

The urinary bladder, trigone, cystourethral junction, and visible pelvic urethra exhibited normal thickness and tone. Anechoic urine was present in the lumen with no uroliths or sediment. The ureteral papillae were normal. The ureters were not visible which is normal. No evidence of inflammatory or neoplastic changes were noted.

**AGE**

11yr

Normal size and margination was present in the kidneys. A normal 1:3 cortex / medulla ratio was maintained. The medulla and cortices were uniform in texture with some increased echogenicity and mild loss of corticomedullary symmetry and definition expected for the age of the patient. Intermittent bilateral small cortical cysts along with pinpoint medullary mineral was present. No evidence of pelvic dilation was present. The left kidney measured 4.8 cm in length. The right kidney measured 5.7 cm in length.

**WEIGHT**

12.63lb

The area of the aortic trifurcation was free of pathology.

**INTERPRETED BY**

R. McKenzie Daniel,  
DVM, DABVP  
(Canine and Feline)

The area of the residual prostate was free of pathology.

**Adrenal Glands**

Bilateral symmetrical adrenal gland enlargement with uniformly hypoechoic parenchyma was present. The left adrenal gland measured 0.77 cm width at the caudal pole and 0.77 cm width at the cranial pole. The right adrenal gland measured 1.1 cm width at the caudal pole and 1.4 cm width at the cranial pole.

**IMAGING PERFORMED BY**

Sara Hansen

**Spleen**

The spleen exhibited primarily finely textured parenchyma which was hyperechoic to the liver and renal cortical parenchyma. Mild generalized parenchyma heterogeneity was present without evidence of nodular changes. The capsule was smooth and regular without apparent expansion. The splenic vasculature at the hilus was normal in volume with no evidence of congestion or thrombosis. The parenchymal heterogeneity is likely consistent with benign changes such as extramedullary hematopoiesis or age-related remodeling with minor potential for inflammatory or neoplastic disease.

**HOSPITAL NAME**

Amazon Park AC

**REFERRING VET**

Dr. Jones

**Liver**

The liver presented moderately increased in size. The parenchyma of the liver was subjectively increased in echogenicity compared to the spleen and renal cortices. The echotexture of the liver parenchyma was uniform with a mild coarse echotexture. The capsule of the liver was symmetrical in margination. The hepatic and portal vasculature were normal in appearance without signs of congestion.

**INVOICE**

11432ag

**DATE**

08/19/2022

The gallbladder was non-distended in size with primarily anechoic luminal content and moderate non-dependent to congealed debris. The cystic and common bile ducts were normal.



**PATIENT** *Gastrointestinal*

Dr. Peterson Huggins

The stomach presented intact wall layering with a normal wall layer ratio. The lumen of the stomach contained variably echogenic ingesta and chyme with no signs of ileus, obstruction or foreign material.

**SPECIES**

Canine

The small intestine presented intact wall layering with 1:3 muscularis/mucosa ratio. The lumen of the small intestine was empty with no signs of ileus, obstruction or foreign material.

**BREED**

Terrier Mix

Normal visible colon wall layers were present with apparent formed feces in lumen.

**SEX**

MN

*Pancreas*

The pancreas was normal in size and contour with isoechoic to heterogeneous parenchyma compared to adjacent omentum. No signs of active inflammation or neoplasia.

**AGE**

11yr

*Free Abdomen*

No overt lymphadenopathy or peritoneal effusion was present.

**WEIGHT**

12.63lb

**ULTRASONOGRAPHIC FINDINGS**

- Bilateral prominent uniform adrenal glands
- Hepatomegaly
- Gallbladder debris (non-mucocele)
- Mild chronic renal changes with small cortical cysts
- Gastric ingesta-likely post prandial presentation

**INTERPRETED BY**

R. McKenzie Daniel,  
DVM, DABVP  
(Canine and Feline)

**INTERPRETATION OF THE FINDINGS & FURTHER RECOMMENDATIONS**

A urine C/S on a sterile urine sample is recommended. A fructosamine level is suggested if clinical concern for diabetes. A full adrenal workup is recommended. Hepatosupportive medications including Denamarin and Ursodiol may prove beneficial. The appearance of the liver was nonspecific but may indicate steroid or other vacuolar hepatopathies, chronic hepatitis/cholangiohepatitis, lipidosis, or fibrosis while round cell hepatic neoplasia cannot be excluded.

**IMAGING PERFORMED BY**

Sara Hansen

**HOSPITAL NAME**

Amazon Park AC

**REFERRING VET**

Dr. Jones

**INVOICE**

11432ag

**DATE**

08/19/2022



**PATIENT**

Dr. Peterson Huggins

**SPECIES**

Canine

**BREED**

Terrier Mix

**SEX**

MN

**AGE**

11yr

**WEIGHT**

12.63lb

**INTERPRETED BY**

R. McKenzie Daniel,  
DVM, DABVP  
(Canine and Feline)

**IMAGING PERFORMED BY**

Sara Hansen

**HOSPITAL NAME**

Amazon Park AC

**REFERRING VET**

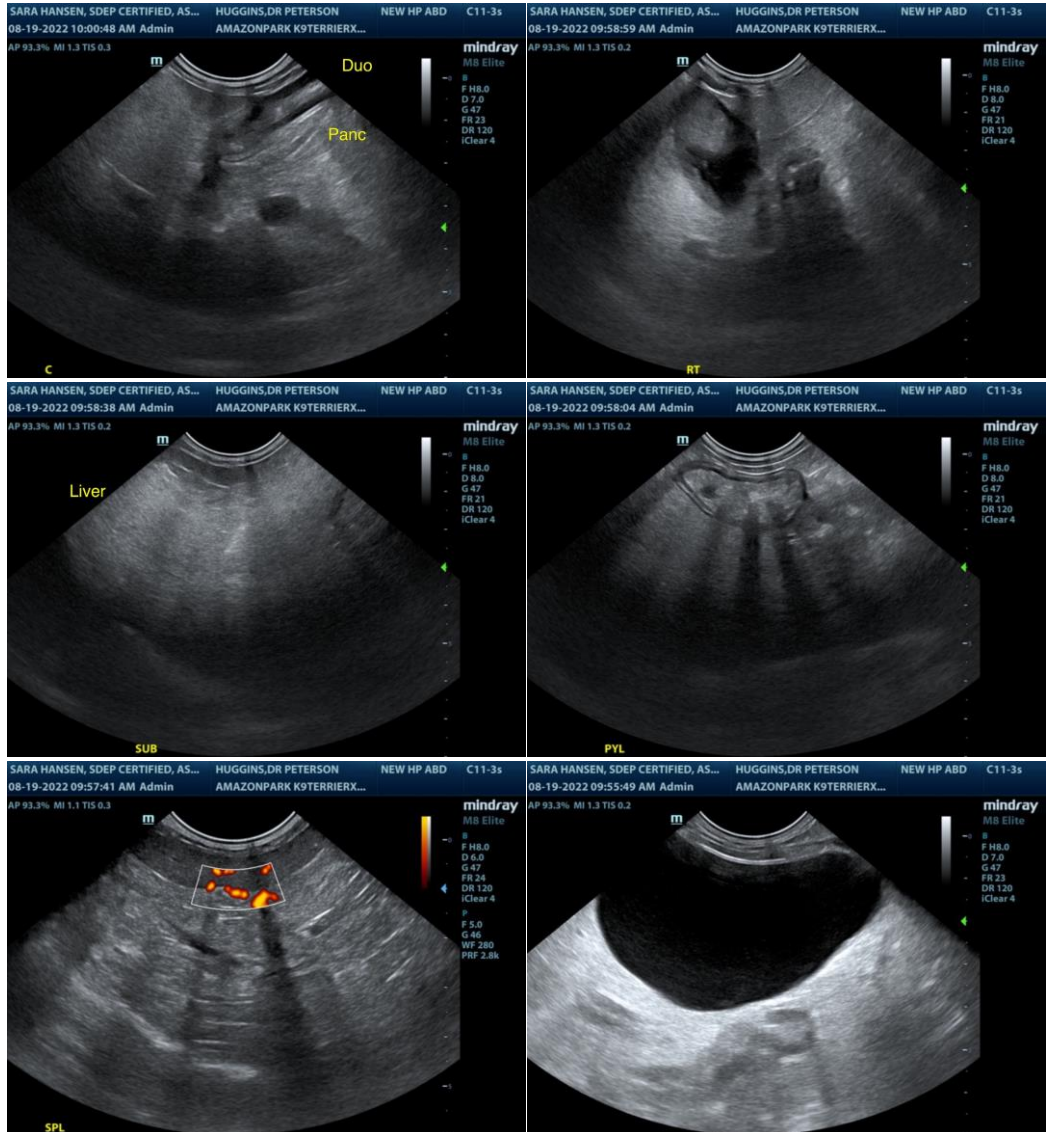
Dr. Jones

**INVOICE**

11432ag

**DATE**

08/19/2022





**PATIENT**

Dr. Peterson Huggins

**SPECIES**

Canine

**BREED**

Terrier Mix

**SEX**

MN

**AGE**

11yr

**WEIGHT**

12.63lb

**INTERPRETED BY**

R. McKenzie Daniel,  
DVM, DABVP  
(Canine and Feline)

**IMAGING PERFORMED BY**

Sara Hansen

**HOSPITAL NAME**

Amazon Park AC

**REFERRING VET**

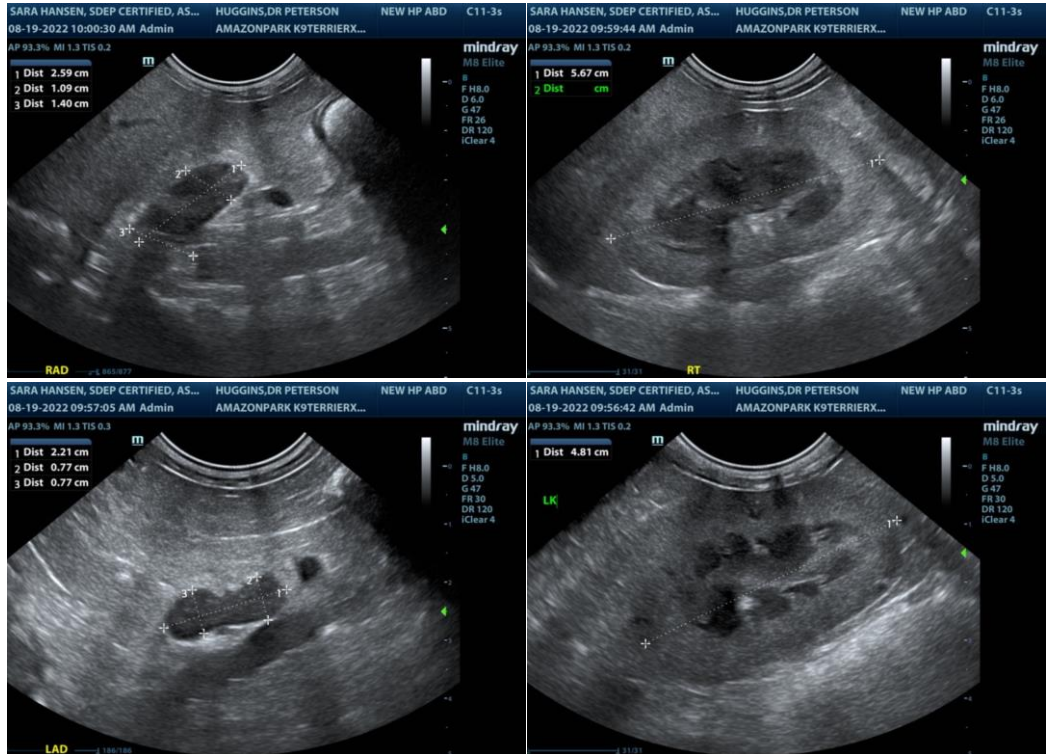
Dr. Jones

**INVOICE**

11432ag

**DATE**

08/19/2022



The information and recommendations provided are based on the images presented by the referring veterinarian/sonographer. No evaluation can be communicated regarding pathology that was not visible in the image/video clips provided.

Thank you for this referral. If the clinical or image interpretation does not parallel your findings or if I can be of any further assistance please contact me.

R. McKenzie Daniel, DVM, DABVP (Canine / Feline Practice)

info@SonoPath.com