



PATIENT

Monkey Spence

SPECIES

Feline

BREED

DSH

SEX

M/N

AGE

7 years

WEIGHT

5.9 kg

INTERPRETED BY

R. McKenzie Daniel,
DVM, DABVP
(Canine and Feline)

IMAGING PERFORMED BY

Dave Stasiuk RDMS,
RDCS

HOSPITAL NAME

Fish Creek Pet
Hospital

REFERRING VET

Dr. E. Johnson

INVOICE

14861

DATE

8/18/23

PRESENTING CLINICAL SIGNS

1/52 Hx of vomiting. Low appetite. Lethargic. Chewing on foam. Unremarkable labs and AXR.

ULTRASONOGRAPHIC EXAMINATION OF THE ABDOMEN

Urinary System

The urinary bladder, trigone, cystourethral junction, and visible pelvic urethra to a depth of 2.0 cm exhibited normal thickness and tone. Anechoic urine was present in the lumen with no uroliths or sediment. The ureteral papillae were normal. The ureters were not visible which is normal. No evidence of inflammatory or neoplastic changes was noted.

No evidence of pathology in the area of the aortic trifurcation.

Normal size and margination were present in the kidneys. A normal 1:3 cortex / medulla ratio and normal corticomedullary definition were maintained. The echogenicity of the cortex was similar to or slightly less than normal liver parenchyma while the medulla echogenicity was hypoechoic to the cortex with no evidence of pelvic dilation. The left kidney measured 4.4 cm in length. The right kidney measured 4.2 cm in length.

Adrenal Glands

The left and right adrenal glands were uniform in size and contour with a uniformly hypoechoic parenchyma. The left adrenal gland measured 0.43 cm width and the right adrenal gland measured 0.37 cm width.

Spleen

The spleen exhibited a finely textured and homogenous parenchyma which was hyperechoic to the liver and renal cortical parenchyma. The capsule was smooth and regular without apparent expansion. The splenic vasculature at the hilus was normal in volume with no evidence of congestion or thrombosis. Acute to chronic inflammatory, neoplastic, or benign parenchyma changes were not noted.

Liver/ Gallbladder

The liver was subjectively normal in size, structure, and contour. The liver parenchyma was uniform and hypoechoic to the spleen with a mild coarse echotexture. The hepatic and portal vasculature were normal in appearance without signs of congestion. The gallbladder was non-distended in size with thin walls and primarily anechoic luminal content. The cystic and common bile ducts were normal.

Gastrointestinal

The stomach presented intact wall layering. The stomach was moderately distended with retained anechoic fluid and mild hyperechoic nonshadowing chyme.

Generalized intact intestinal wall layering exhibiting normal wall layer ratio was present. The upper to mid duodenum exhibited mild retained fluid and fluid distention extending caudally to the approximate level of the distal duodenum to potential upper jejunum. Within the distal duodenum to potential upper jejunum, a strongly shadowing lumen echo measuring approximately 2.0 cm in diameter was present. Intact, mildly thickened distal duodenum to potential proximal jejunum wall layering was noted in the



PATIENT

Monkey Spence

area of the lumen echo, suggestive of secondary or associated focal intestinal inflammation. Empty small intestine was noted distal to the upper duodenum to possible proximal jejunum echo.

SPECIES

Feline

Normal visible colon wall layers were present with apparent formed feces in lumen.

BREED

DSH

Pancreas

The pancreas was normal in size and contour with subtle nonhomogeneous hypoechoic parenchyma with left and right limb mild pancreatic duct dilation.

SEX

M/N

Free Abdomen

No overt lymphadenopathy was present. A small pocket of scant free fluid was noted in the right cranial abdomen between the right lateral and caudate liver lobe.

AGE

7 years

ULTRASONOGRAPHIC FINDINGS

- Distal duodenum to potential upper jejunum lumen foreign body with gastroduodenal obstructive pattern
- Possible concurrent mild chronic pancreatitis

WEIGHT

5.9 kg

INTERPRETATION OF THE FINDINGS & FURTHER RECOMMENDATIONS

Exploratory laparotomy with expectation towards enterotomy and gross inspection of the gastrointestinal tract and pancreas is recommended.

INTERPRETED BY

R. McKenzie Daniel,
DVM, DABVP
(Canine and Feline)

IMAGING PERFORMED BY

Dave Stasiuk RDMS,
RDCS

HOSPITAL NAME

Fish Creek Pet
Hospital

REFERRING VET

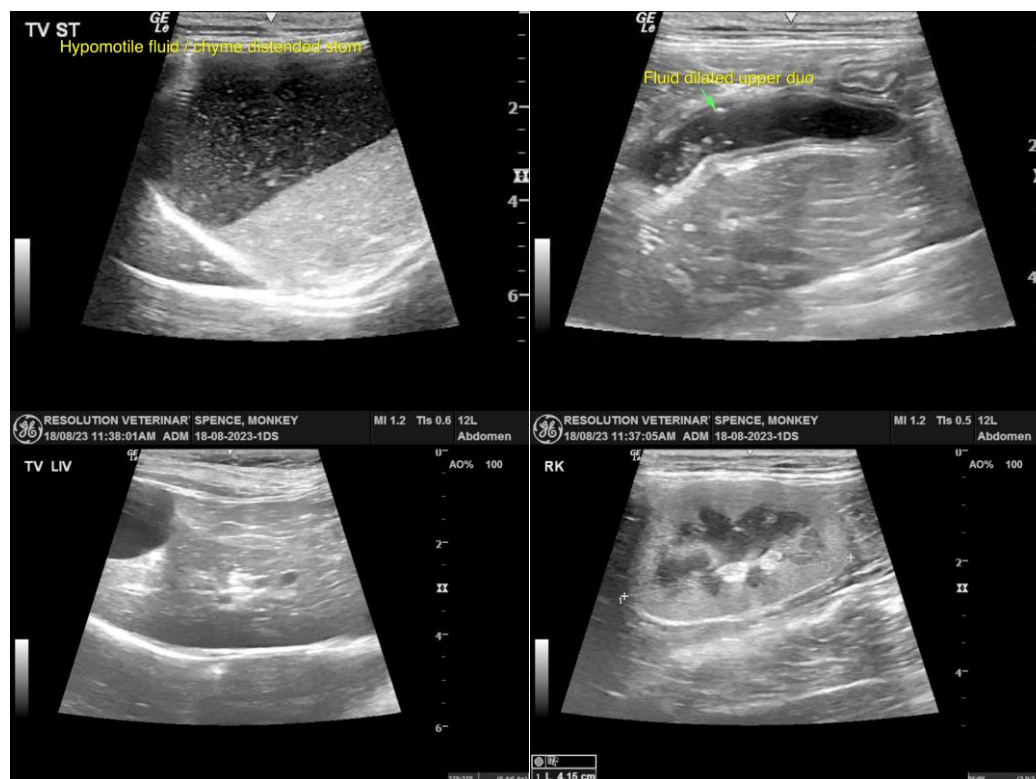
Dr. E. Johnson

INVOICE

14861

DATE

8/18/23





PATIENT

Monkey Spence

SPECIES

Feline

BREED

DSH

SEX

M/N

AGE

7 years

WEIGHT

5.9 kg

INTERPRETED BY

R. McKenzie Daniel,
DVM, DABVP
(Canine and Feline)

IMAGING PERFORMED BY

Dave Stasiuk RDMS,
RDMS

HOSPITAL NAME

Fish Creek Pet
Hospital

REFERRING VET

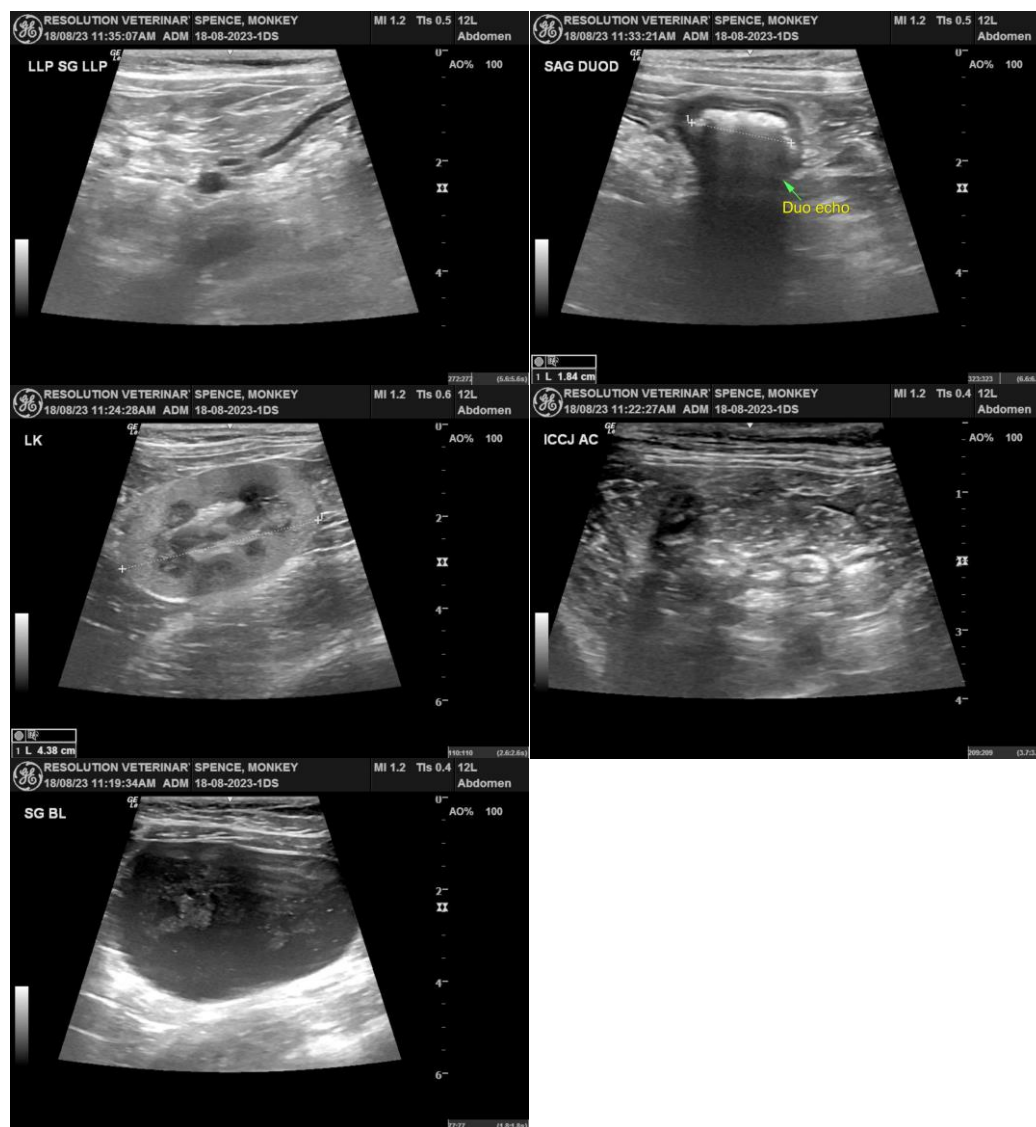
Dr. E. Johnson

INVOICE

14861

DATE

8/18/23



The information and recommendations provided are based on the images presented by the referring veterinarian/sonographer. No evaluation can be communicated regarding pathology that was not visible in the image/video clips provided.

Thank you for this referral. If the clinical or image interpretation does not parallel your findings or if I can be of any further assistance, please contact me.

R. McKenzie Daniel, DVM, DABVP (Canine/Feline Practice)
info@sonopath.com