



PATIENT

Daisy Moles

SPECIES

Canine

BREED

Boston Terrier

SEX

FS

AGE

8 years

WEIGHT

26.8 lbs.

INTERPRETED BY

R. McKenzie Daniel,
DVM, DABVP
(Canine and Feline)

IMAGING PERFORMED BY

A. Rodriguez

HOSPITAL NAME

Foxfield VS

REFERRING VET

A. Rodriguez

INVOICE

14832

DATE

8/17/23

PRESENTING CLINICAL SIGNS

Hx of mast cell.. Met check
Abnormal PE/Chem/CBC/UA Results: WNL

ULTRASONOGRAPHIC EXAMINATION OF THE ABDOMEN

Urinary System

The urinary bladder, trigone, cystourethral junction, and visible pelvic urethra to a depth of 3.0 cm exhibited normal thickness and tone. Anechoic urine was present in the lumen with no uroliths or sediment. The ureteral papillae were normal. The ureters were not visible which is normal. No evidence of inflammatory or neoplastic changes was noted.

A solitary, medial iliac lymph node was present. The lymph node was isoechoic, homogeneous, and non-enlarged without evidence of peripheral inflammation and maintaining a normal width: length ratio (<0.5). The lymph node measured 2.1 cm x 0.76 cm. There was no evidence of perilymphatic inflammation.

Normal size and margination were present in the kidneys. A normal 1:3 cortex / medulla ratio and normal corticomedullary definition were maintained. The echogenicity of the cortex was similar to or slightly less than normal liver parenchyma while the medulla echogenicity was hypoechoic to the cortex with no evidence of pelvic dilation. The left kidney measured 4.8 cm in length. The right kidney measured 5.0 cm in length.

Adrenal Glands

The left adrenal gland was uniform in size and contour with a uniformly hypoechoic parenchyma. The left adrenal gland measured 1.6 cm length x 0.65 cm width at the caudal pole. The right adrenal gland was uniform in size and contour with a uniformly hypoechoic parenchyma. The right adrenal gland measured 2.0 cm length x 0.82 cm width at the caudal pole.

Spleen

The spleen exhibited a finely textured and homogenous parenchyma which was hyperechoic to the liver and renal cortical parenchyma. The capsule was smooth and regular without apparent expansion. The splenic vasculature at the hilus was normal in volume with no evidence of congestion or thrombosis. Acute to chronic inflammatory, neoplastic, or benign parenchyma changes were not noted.

Liver/ Gallbladder

The liver was subjectively normal in size, structure, and contour. The liver parenchyma was uniform and hypoechoic to the spleen with a mild coarse echotexture. The hepatic and portal vasculature were normal in appearance without signs of congestion. The gallbladder was non-distended in size with thin walls and primarily anechoic luminal content. The cystic and common bile ducts were normal.

Gastrointestinal

The stomach presented intact wall layering with a normal wall layer ratio. The lumen of the stomach was empty with no signs of ileus, obstruction, or foreign material.



PATIENT

Daisy Moles

SPECIES

Canine

BREED

Boston Terrier

SEX

FS

AGE

8 years

WEIGHT

26.8 lbs.

The small intestine presented intact wall layering with 1:3 muscularis/mucosa ratio. The lumen of the small intestine was empty with no signs of ileus, obstruction, or foreign material.

Normal visible colon wall layers were present with apparent formed feces in lumen.

Pancreas

The parenchyma of the left limb, body, and right limb of the pancreas presented isoechoic to the adjacent omental fat. A normal curvilinear capsule contour of the pancreas was present. The visible pancreatic duct was normal. No signs of active inflammation or neoplastic disease were evident.

Free Abdomen

No evidence of omental masses, lymphadenopathy, or peritoneal effusion.

ULTRASONOGRAPHIC FINDINGS

- Sonographically unremarkable abdomen
- Mild isoechoic nonenlarged medial iliac lymph node - not consistent with inflammatory or neoplastic lymphatic criteria, likely incidental

INTERPRETATION OF THE FINDINGS & FURTHER RECOMMENDATIONS

There was no evidence of intrabdominal or retroperitoneal primary or metastatic neoplastic criteria. Sonographic monitoring of the abdominal cavity ideally based on oncology recommendations is suggested.

INTERPRETED BY

R. McKenzie Daniel,
DVM, DABVP
(Canine and Feline)

IMAGING PERFORMED BY

A. Rodriguez

HOSPITAL NAME

Foxfield VS

REFERRING VET

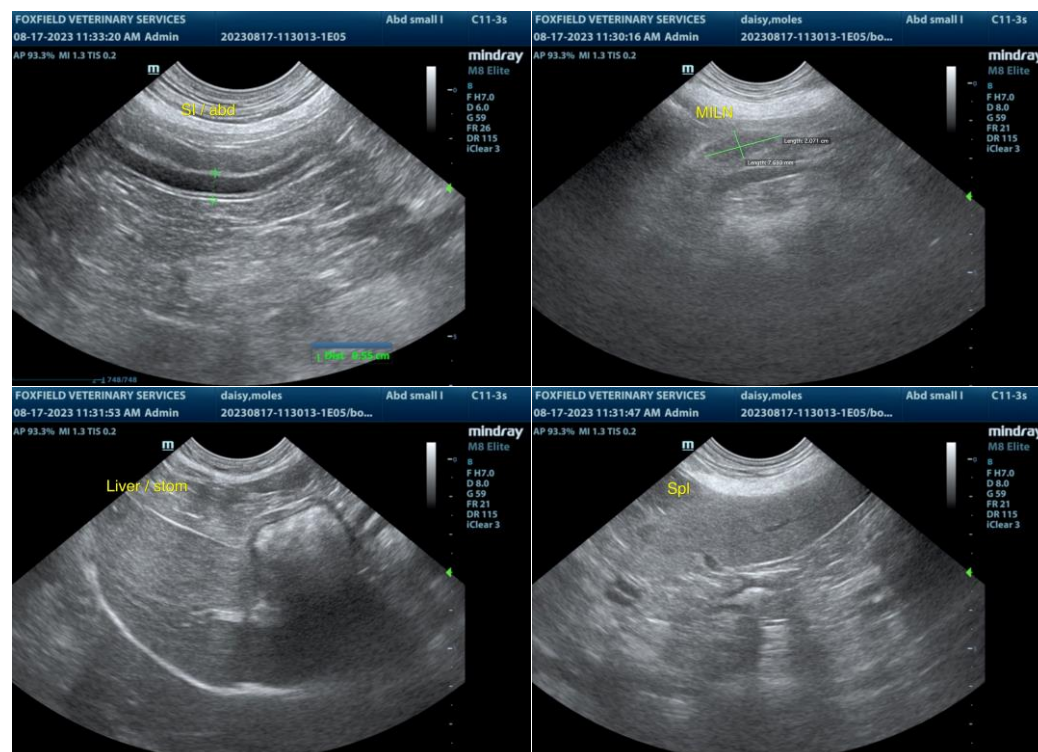
A. Rodriguez

INVOICE

14832

DATE

8/17/23





PATIENT

Daisy Moles

SPECIES

Canine

BREED

Boston Terrier

SEX

FS

AGE

8 years

WEIGHT

26.8 lbs.

INTERPRETED BY

R. McKenzie Daniel,
DVM, DABVP
(Canine and Feline)

IMAGING PERFORMED BY

A. Rodriguez

HOSPITAL NAME

Foxfield VS

REFERRING VET

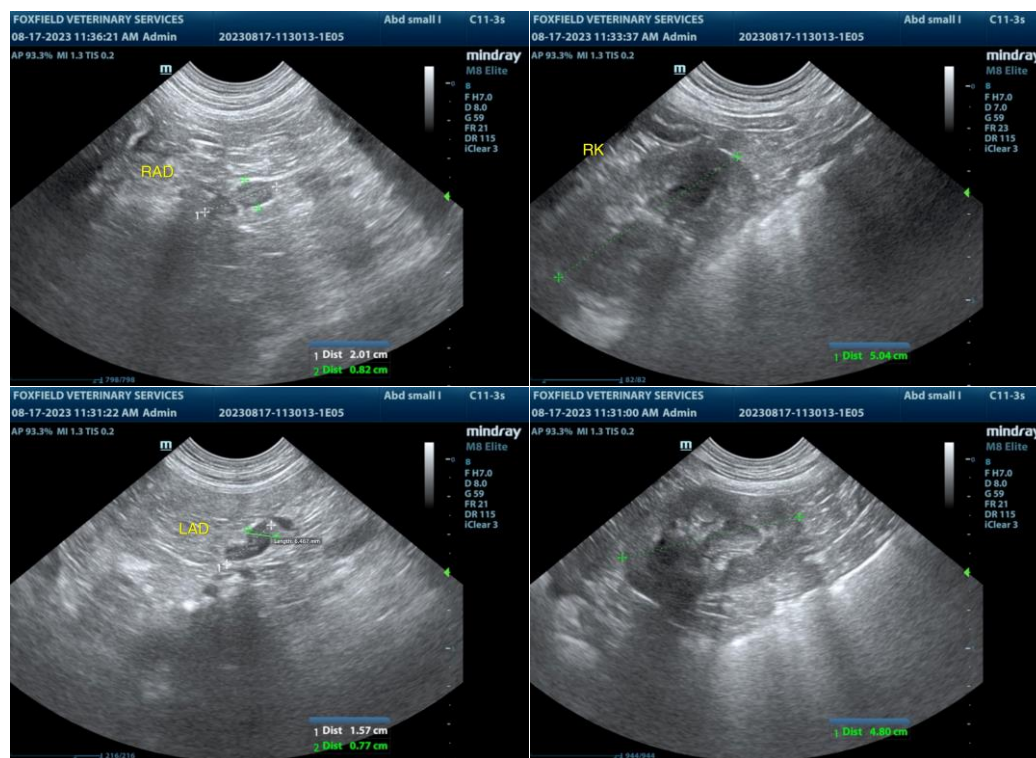
A. Rodriguez

INVOICE

14832

DATE

8/17/23



The information and recommendations provided are based on the images presented by the referring veterinarian/sonographer. No evaluation can be communicated regarding pathology that was not visible in the image/video clips provided.

Thank you for this referral. If the clinical or image interpretation does not parallel your findings or if I can be of any further assistance, please contact me.

R. McKenzie Daniel, DVM, DABVP (Canine/Feline Practice)

info@sonopath.com