



PATIENT PRESENTING CLINICAL SIGNS

Phaedra Carney History of colitis, referral vet noted bloodwork abnormalities and decreased body condition Endure Joint Supplement

SPECIES Unremarkable CBC, Chemistry panel - Albumin 2.4, Globulin 4.7, A/G Ratio 0.5, Na/K ratio 33

Canine 4DX-negative, Giardia and intestinal parasite- negative

BREED ULTRASONOGRAPHIC EXAMINATION OF THE ABDOMEN

German Shepherd

Urinary System

SEX The urinary bladder, trigone, cystourethral junction, and visible pelvic urethra to a depth of 3.0 cm exhibited normal thickness and tone. Anechoic urine was present in the lumen with no uroliths or sediment. The ureteral papillae were normal. The ureters were not visible which is normal. No evidence of inflammatory or neoplastic changes was noted.
F/S

AGE The area of the aortic trifurcation was free of pathology.

2015 Normal size and margination were present in the kidneys. A normal 1:3 cortex / medulla ratio and normal corticomedullary definition were maintained. The echogenicity of the cortex was similar to or slightly less than normal liver parenchyma while the medulla echogenicity was hypoechoic to the cortex with no evidence of pelvic dilation. The left kidney measured 7.2 cm in length. The right kidney measured 7.4 cm in length.

WEIGHT 57

INTERPRETED BY Adrenal Glands

R. McKenzie Daniel, DVM, DABVP (Canine and Feline) The left adrenal gland was uniform in size and contour with a uniformly hypoechoic parenchyma. The left adrenal gland measured 2.3 cm length x 0.55 cm width at the caudal pole. The right adrenal gland was uniform in size and contour with a uniformly hypoechoic parenchyma. The right adrenal gland measured 2.5 cm length x 0.71 cm width at the caudal pole.

IMAGING PERFORMED BY Spleen
Rebekah Jakum, CVT

ARDMS/RVT The spleen exhibited a finely textured and homogenous parenchyma which was hyperechoic to the liver and renal cortical parenchyma. The capsule was smooth and regular without apparent expansion. The splenic vasculature at the hilus was normal in volume with no evidence of congestion or thrombosis. Acute to chronic inflammatory, neoplastic, or benign parenchyma changes were not noted.

HOSPITAL NAME

Mill Pond VC

REFERRING VET Liver/ Gallbladder

Dr. Thayer The liver was subjectively normal in size, structure, and contour. The liver parenchyma was uniform and hypoechoic to the spleen with a mild coarse echotexture. The hepatic and portal vasculature were normal in appearance without signs of congestion. The gallbladder was non-distended in size with thin walls and primarily anechoic luminal content. The cystic and common bile ducts were normal.

INVOICE

14650

DATE

8/17/22



PATIENT ***Gastrointestinal***

Phaedra Carney The stomach presented intact yet mildly prominent wall layering owing to propensity for mildly prominent gastric mucosa, as well as regional muscularis. The gastric body wall width measured 0.57 cm. The stomach was empty with minor luminal gas.

SPECIES

Canine The small intestine presented intact wall layering with 1:3 muscularis/mucosa ratio. Minor upper duodenal corrugation was present. The lumen of the small intestine was empty with no signs of ileus, obstruction, or foreign material. The duodenum wall measured 0.53 cm width. The jejunum wall measured 0.30 cm width.

BREED

German Shepherd The colon exhibited intact and overtly normal wall layering with subjective propensity for mildly prominent wall layering present in the proximal colon. The colon appeared to contain semi-formed to potential soft fecal matter. The proximal colon wall width measured 0.26 cm. By comparison, the descending colon wall adjacent to the urinary bladder measured 0.16 cm width.

SEX

F/S

Pancreas

AGE

2015

The parenchyma of the left limb, body, and right limb of the pancreas presented isoechoic to the adjacent omental fat. A normal curvilinear capsule contour of the pancreas was present. The visible pancreatic duct was normal. No signs of active inflammation or neoplastic disease were evident.

WEIGHT

57

Free Abdomen

No overt lymphadenopathy or peritoneal effusion was present.

ULTRASONOGRAPHIC FINDINGS

INTERPRETED BY

R. McKenzie Daniel,
DVM, DABVP
(Canine and Feline)

- Intact yet mildly prominent gastric walls - patient variant, potential for mild chronic gastritis
- Overtly normal small bowel
- Overtly normal colon, possible mild chronic proximal colitis

IMAGING PERFORMED BY

Rebekah Jakum, CVT
ARDMS/RVT

INTERPRETATION OF THE FINDINGS & FURTHER RECOMMENDATIONS

Overall, no overt evidence of abdominal visceral, specifically gastroenterocolic, pathology as a definitive cause of the chronic GI signs, decreased body condition, and / or inability to increase body condition. A GI panel to include PLI/TLI/Cobalamin/Folate to assess for occult intestinal or pancreatic disease as a contributing factor is suggested.

HOSPITAL NAME

Mill Pond VC

Empirical therapy for mild chronic colitis +/- gastritis, If evidence of inappetence and vomiting, with continued assessment of caloric plane, as well as potential higher calorie / higher fiber diet if available, and high colony count probiotic may prove beneficial.

REFERRING VET

Dr. Thayer

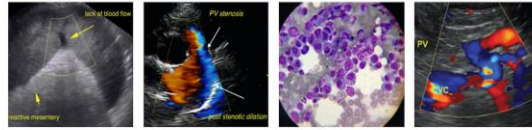
Sonographic reassessment of the gastrointestinal tract is recommended if progressive hypoalbuminemia is noted.

INVOICE

14650

DATE

8/17/22



PATIENT

Phaedra Carney

SPECIES

Canine

BREED

German Shepherd

SEX

F/S

AGE

2015

WEIGHT

57

INTERPRETED BY

R. McKenzie Daniel,
DVM, DABVP
(Canine and Feline)

IMAGING PERFORMED BY

Rebekah Jakum, CVT
ARDMS/RVT

HOSPITAL NAME

Mill Pond VC

REFERRING VET

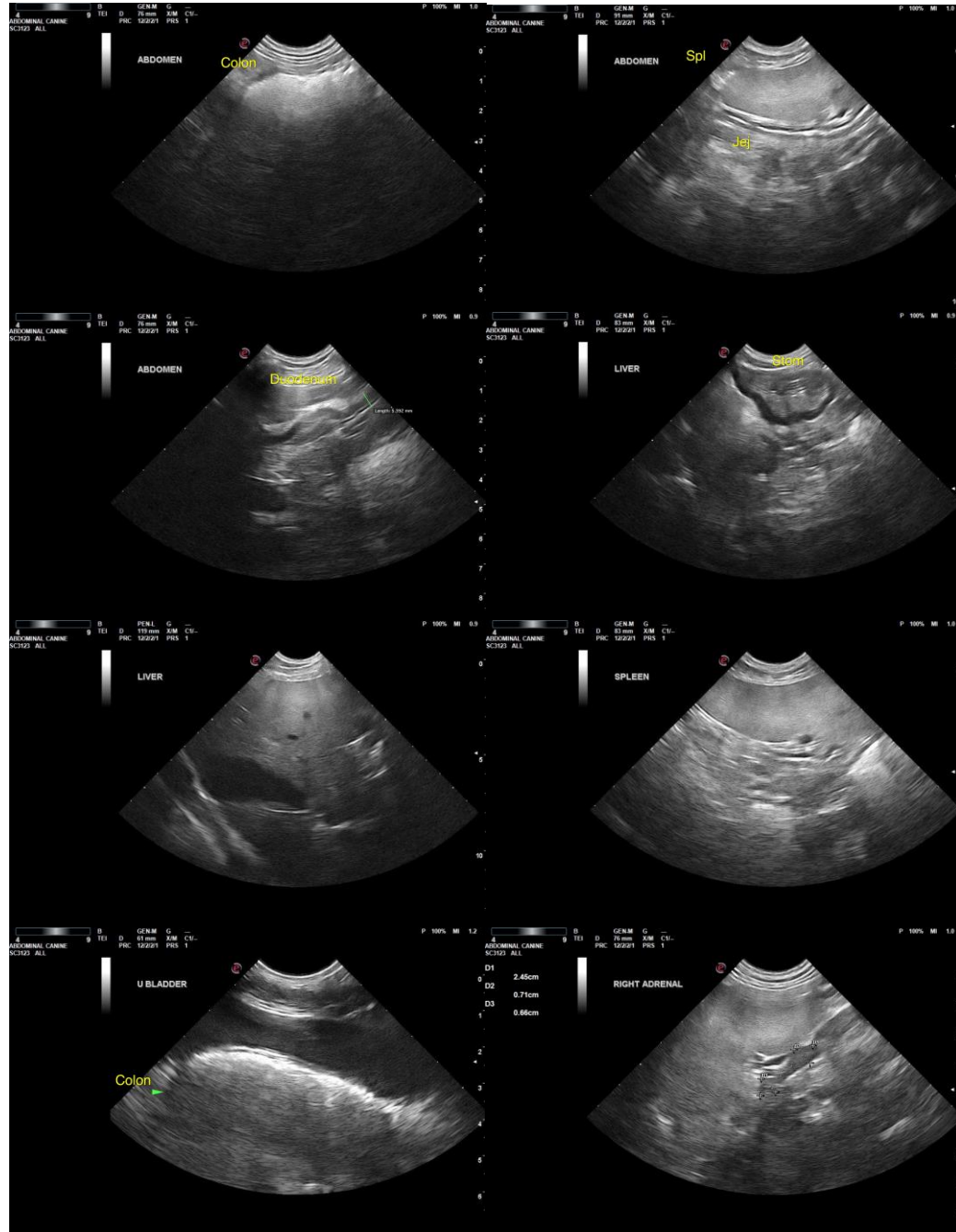
Dr. Thayer

INVOICE

14650

DATE

8/17/22





PATIENT

Phaedra Carney

SPECIES

Canine

BREED

German Shepherd

SEX

F/S

AGE

2015

WEIGHT

57

INTERPRETED BY

R. McKenzie Daniel,
DVM, DABVP
(Canine and Feline)

IMAGING PERFORMED BY

Rebekah Jakum, CVT
ARDMS/RVT

HOSPITAL NAME

Mill Pond VC

REFERRING VET

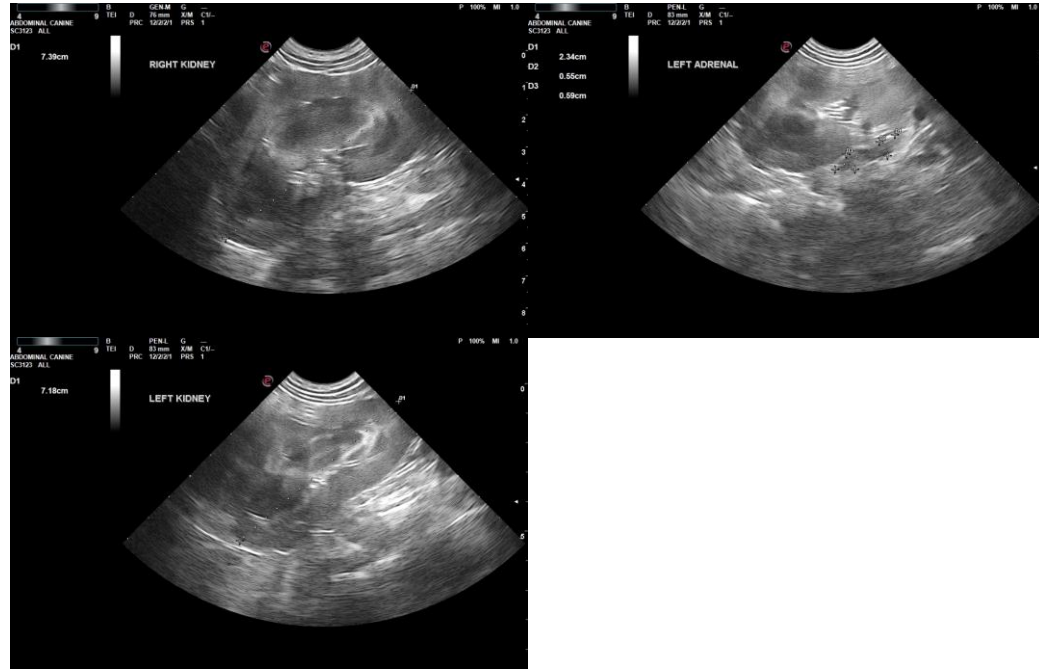
Dr. Thayer

INVOICE

14650

DATE

8/17/22



The information and recommendations provided are based on the images presented by the referring veterinarian/sonographer. No evaluation can be communicated regarding pathology that was not visible in the image/video clips provided.

Thank you for this referral. If the clinical or image interpretation does not parallel your findings or if I can be of any further assistance, please contact me.

R. McKenzie Daniel, DVM, DABVP (Canine/Feline Practice)
mac.daniel@sonopath.com