SonoPath
Clinical Sonography & Telecytology

EDUCATIONAL TELECONSULTATION SERVICES™

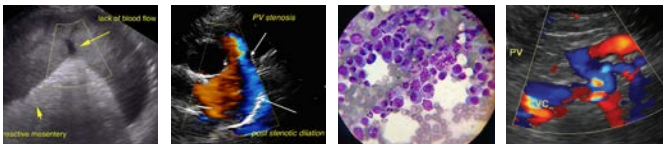

SonoPath.com
1-800-838-4268 info@sonopath.com

PATIENT
Simsek Maraz

SPECIES
Canine

BREED
Rottweiler X

SEX
Neutered Male

AGE
23 Months

WEIGHT
52.8 Pounds

INTERPRETED BY
R. McKenzie Daniel, DVM, DABVP (Canine and Feline)

IMAGING PERFORMED BY
Kim Liedberg

HOSPITAL NAME
SVS Imaging

REFERRING VET
Dr. Vivek

INVOICE
24750

DATE
8/17/21

PRESENTING CLINICAL SIGNS

Had a cough 3 months earlier and resolved after doxycycline treatment. No heart murmur has been detected during PE. This echocardiogram is a screening panel for a base line heart check

ULTRASONOGRAPHIC EXAMINATION OF THE HEART

CANINE CARDIAC PARAMETERS	MR VMAX (m/s)	TR VMAX (m/s)	LA/AO (Boon method)	LA/AO (Heart Base; Swe)	FS (%)	EF (%)	EPSS (cm)
NORMAL PARAMETER	4.5-5.5	<2.7	1.3	<1.6	28-40	40-100	<0.6
PATIENT			NM	1.26	35	67.8	0.25
CANINE CARDIAC PARAMETERS	**HR** (BPM)	**AV VMAX** (m/s)	**PV MAX** (m/s)	**BODY WEIGHT** (kg)	**LA** 2D short axis Base view (cm)	**LVIDd** Avg; 2D and m-mode short axis (cm)	**LVIDs** Avg; 2D and m-mode short axis (cm)
NORMAL PARAMETER	50-100	0.7-1.7	0.7-1.6				
PATIENT	161	1.8	1.1		3.9	4.0	

Cardiac Presentation

The echocardiogram in this patient demonstrated normal **left atrial** size based on 3 separate methods of LA evaluation. The cranial and caudal **mitral** valve leaflets presented normal linear structure, extension in systole, and union in diastole with normal kinesis. The **left ventricle** presented thicknesses with linear contour and was not dilated nor restricted. The **myocardium** presented normal echogenicity without subjective evidence of significant fibrotic or ischemic disease. **Contractility** of the ventricular walls was adequate and in normal range for this patient evidenced by the fractional shortening measurement and subjective evaluation of the different regions of the myocardium. The **left ventricular outflow** tract demonstrated normal laminar flow and subjective structural integrity. The **right atrium** and auricle revealed normal size, structure and content. No evidence of masses was noted. **Tricuspid** valvular assessment demonstrated adequate linear morphology and kinesis. The **right ventricle** was of normal size (1/3 diameter of LV), chordae structure, myocardial echogenicity and thickness. **Pulmonary outflow** tract assessment revealed normal valve structure, laminar flow, and diameter (approx.1:1 pa/ao ratio). No visible **pericardial** or free pleura fluid was noted. The cranial **mediastinum and pericardial and extra-cardiac regions** were free of masses in the visible window.

ULTRASONOGRAPHIC FINDINGS

- Overtly normal cardiac structure and function

INTERPRETATION OF THE FINDINGS & FURTHER RECOMMENDATIONS

No evidence of structural or functional cardiomyopathy, including no evidence of valvular insufficiency, stenotic disease, systolic dysfunction or shunt. Given the lack of structural or functional cardiomyopathy, the recent coughing in this patient is non-cardiogenic in origin. Recheck echocardiogram is suggested only if clinically indicated, such as clinical signs suggestive of heart disease or development of a heart murmur.

SonoPath
Clinical Sonography & Telecytology

EDUCATIONAL TELECONSULTATION SERVICES™

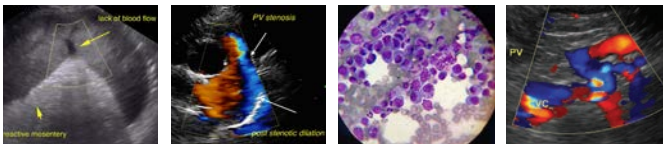

SonoPath.com™
1-800-838-4268 info@sonopath.com

PATIENT

Simsek Maraz

SPECIES

Canine

BREED

Rottweiler X

SEX

Neutered Male

AGE

23 Months

WEIGHT

52.8 Pounds

INTERPRETED BY

R. McKenzie Daniel, DVM, DABVP (Canine and Feline)

IMAGING PERFORMED BY

Kim Liedberg

HOSPITAL NAME

SVS Imaging

REFERRING VET

Dr. Vivek

INVOICE

24750

DATE

8/17/21

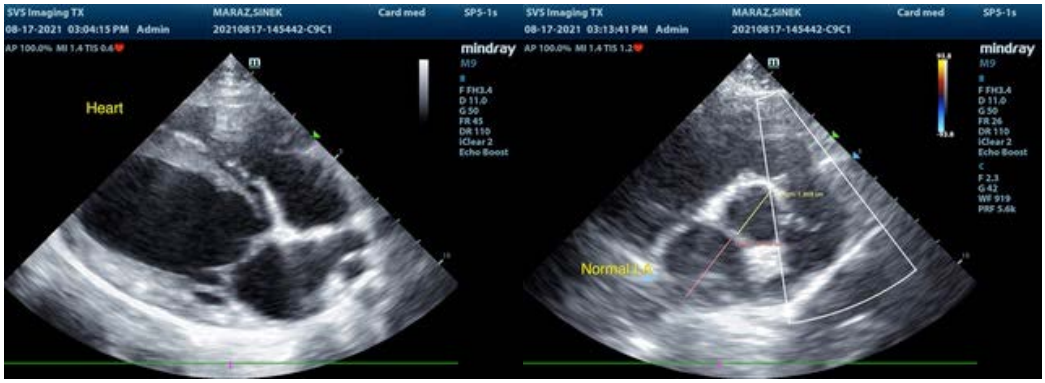

The information and recommendations provided are based on the images presented by the referring veterinarian. No evaluation can be communicated regarding pathology that was not visible in the image/video clips provided.

Thank you for this referral. If the clinical or image interpretation does not parallel your findings or if I can be of any further assistance please contact me.

R. McKenzie Daniel, DVM, DABVP (Canine / Feline Practice)
info@SonoPath.com