**PATIENT**

Rolly Davis

**SPECIES**

Feline

**BREED**

DSH

**SEX**

Neutered Male

**AGE**

13 Years

**WEIGHT**

9 Pounds

**INTERPRETED BY**R. McKenzie Daniel, DVM,  
DABVP (Canine and Feline)**IMAGING PERFORMED BY**

Sarah Pender, CVT

**HOSPITAL NAME**

SVS Imaging QC

**REFERRING VET**

Dr. Kulemin

**INVOICE**

24748

**DATE**

8/17/21

**PRESENTING CLINICAL SIGNS**

Diarrhea Diabetic (since 12/2020) Polyphagic/failure to gain weight (despite well-controlled DM) Abnormal PE/Chem/CBC/UA Results: FIV Positive (known since 9/2019). Long-standing (at least since 7/2018) regenerative Heinz body anemia with basophilic stippling. Mild, fairly stable CRD/azotemia. Elevated fPL (39.8 mcg/L) on 12/2020; TAMU GI Panel pending. Radiographs 9/2020 WNLs, other than a very full colon. Distended abdomen.

**ULTRASONOGRAPHIC EXAMINATION OF THE ABDOMEN****Urinary System**

The urinary bladder, trigone, cystourethral junction, and visible pelvic urethra to a depth of cm exhibited normal thickness and tone. Anechoic urine was present in the lumen with no uroliths or sediment. The ureteral papillae were normal. The ureters were not visible which is normal. No evidence of inflammatory or neoplastic changes were noted.

The left kidney was enlarged in size, measuring approximately 5.7 cm in length. The right kidney was normal in size, measuring 3.5 cm in length. The renal cortex presented uniformly increased in echogenicity with uniform echotexture. The renal cortex appeared to be hypertrophied resulting in an altered cortex: medulla ratio. Moderate loss of corticomedullary distinction was also present. The renal medullary volume was subjectively reduced. Minor dystrophic non-obstructive medullary mineral was noted in the left kidney.

**Adrenal Glands**

Both adrenal glands were mildly prominent in size, yet overall normal structure and contour. The right adrenal gland measured 0.56 cm in width. The left adrenal gland measured 0.49 cm in width.

**Spleen**

The spleen exhibited mild generalized enlargement (1.2 cm in width at the level of the hilus) and primarily finely textured parenchyma which was hyperechoic to the liver and renal cortical parenchyma. Mild generalized parenchyma heterogeneity was present without evidence of nodular changes. The capsule was smooth and regular without apparent expansion. The splenic vasculature at the hilus was normal in volume with no evidence of congestion or thrombosis. The parenchymal heterogeneity is likely consistent with benign changes such as extramedullary hematopoiesis or age related remodeling with minor potential for inflammatory or neoplastic disease.

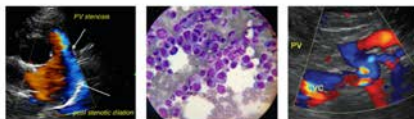
**Liver**

The liver was mildly enlarged. The parenchyma of the liver was subjectively normal in echogenicity compared to the spleen and renal cortices. The liver parenchyma was uniform with a mildly coarse echotexture. The capsule of the liver was symmetrically rounded to mildly swollen in margination. The hepatic and portal vasculature were normal in appearance without signs of congestion. The gallbladder was non-distended in size with primarily anechoic luminal content. The cystic and common bile ducts were normal

**Gastrointestinal**

The stomach presented intact wall layering with a normal wall layer ratio. The lumen of the stomach was empty with no signs of ileus, obstruction or foreign material.

The small intestine presented intact wall layering with generalized propensity for mildly prominent muscularis layer. No evidence of loss of intestinal wall layering or intestinal masses. Duodenum wall measured 0.34 cm. Jejunum wall measured 0.29 cm.

**PATIENT**

Rolly Davis

Ileocolic wall measured 0.41 cm. Normal visible colon wall layers were present with apparent formed feces in lumen.

***Pancreas*****SPECIES**

Feline

The pancreas exhibited generalized enlargement and asymmetrical contour with hypoechoic to heterogeneous parenchyma and subtle nodular changes. The left pancreatic limb measured 1.3 cm in width.

**BREED**

DSH

***Free Abdomen***

Intermittent, mildly prominent to enlarged mesenteric nodes were present. The lymph node was essentially isoechoic to adjacent omentum without evidence of peripheral inflammation and maintaining a normal width: length ratio (<0.5). Small pockets of scant free fluid were noted around the urinary bladder and caudal liver margins. Subtle generalized reactive mesentery noted.

**SEX**

Neutered Male

**ULTRASONOGRAPHIC FINDINGS**

- Bilateral chronic interstitial nephrosis with non-specific left kidney renomegaly.
- Mild non-specific hepatosplenomegaly
- IBD intestinal pattern with associated, subjectively reactive mesenteric lymphadenopathy
- Enlarged, hypoechoic to heterogeneous, nodular pancreas
- Scant peritoneal free fluid

**AGE**

13 Years

**WEIGHT**

9 Pounds

**INTERPRETATION OF THE FINDINGS & FURTHER RECOMMENDATIONS****INTERPRETED BY**R. McKenzie Daniel, DVM,  
DABVP (Canine and Feline)

Overall, the small intestine exhibited subtle mural changes suggestive of IBD with associated reactive lymphadenopathy. The potential for neoplastic infiltrative enteropathy with round cells (i.e., lymphoma) possible yet considered less likely given the sonographic appearance of the small intestine and associated lymphadenopathy. The appearance of the pancreas is suggestive of concurrent chronic active pancreatitis with pancreatic parenchymal remodeling and potential areas of nodular hyperplasia. Concurrently, mild hepatosplenomegaly was non-specific with considerations including benign, reactive or age related hepatosplenic changes.

**IMAGING PERFORMED BY**

Sarah Pender, CVT

Screening hepatosplenic FNA using 25-gauge needle and assuming normal clotting status could be considered primarily to ensure only benign hepatosplenic changes are present. Further renal staging to include urine C/S and protein: creatinine ratio on sterile urine sample may be considered. Pending GI panel, empirical therapy for probable IBD may be considered.

**HOSPITAL NAME**

SVS Imaging QC

For an additional charge, internal medicine consult can be utilized through SonoPath.com. You can select the internal medicine drop down at <http://spa.sonopath.com/>.

**REFERRING VET**

Dr. Kulemin

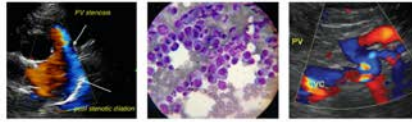
One of the world's top internists & SonoPath associate Dr. Remo Lobetti BVSc, MMedVet, PhD, DECVIM can evaluate your case through SonoPath. <https://sonopath.com/resources/sonopath-services/internal-medicine-teleconsultation-services>

**INVOICE**

24748

**DATE**

8/17/21



**PATIENT**

Rolly Davis

**SPECIES**

Feline

**BREED**

DSH

**SEX**

Neutered Male

**AGE**

13 Years

**WEIGHT**

9 Pounds

**INTERPRETED BY**

R. McKenzie Daniel, DVM,  
DABVP (Canine and Feline)

**IMAGING PERFORMED BY**

Sarah Pender, CVT

**HOSPITAL NAME**

SVS Imaging QC

**REFERRING VET**

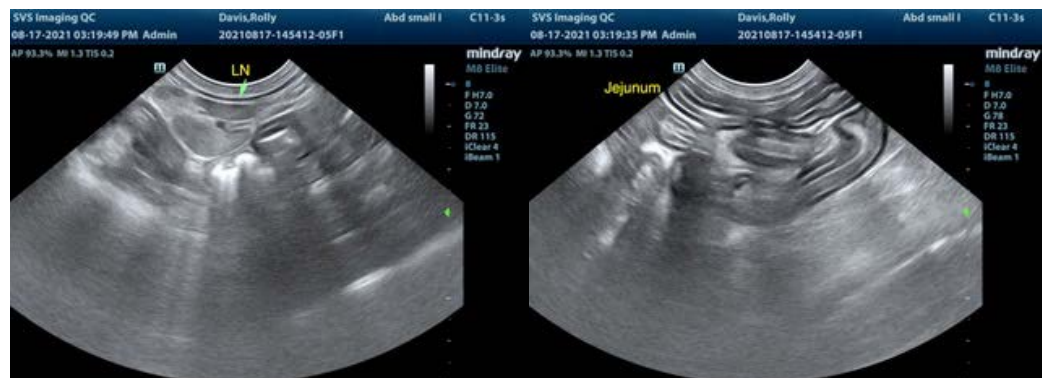
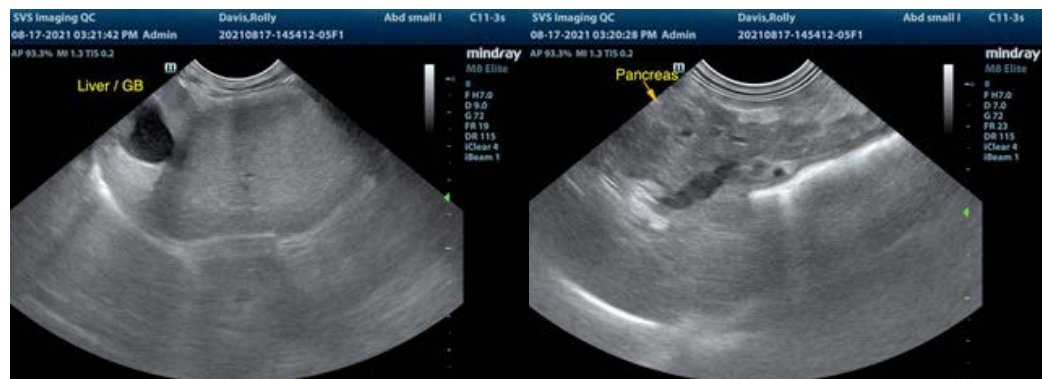
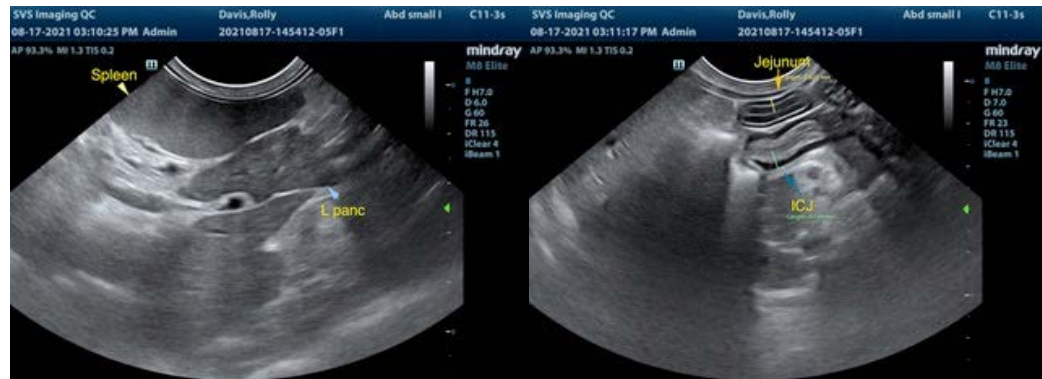
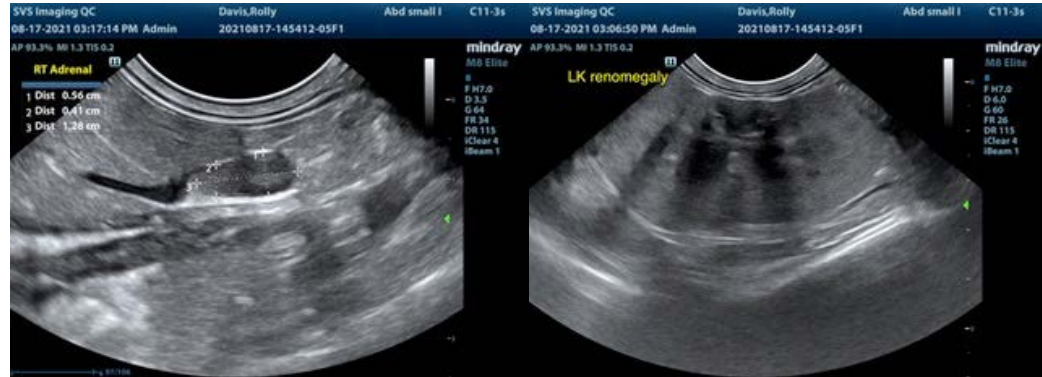Dr. Kulemin

**INVOICE**

24748

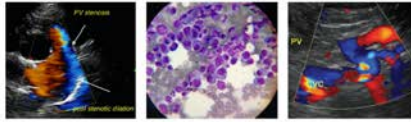
**DATE**

8/17/21



IMAGING PERFORMED BY

svsimaging.net 309-737-3070



Clinical Sonography & Telectology

EDUCATIONAL TELECONSULTATION SERVICES™

1-800-838-4268 info@sonopath.com SonoPath.com

**PATIENT**

Rolly Davis

**SPECIES**

Feline

**BREED**

DSH

**SEX**

Neutered Male

**AGE**

13 Years

**WEIGHT**

9 Pounds

**INTERPRETED BY**

R. McKenzie Daniel, DVM,  
DABVP (Canine and Feline)

**IMAGING  
PERFORMED BY**

Sarah Pender, CVT

**HOSPITAL NAME**

SVS Imaging QC

**REFERRING VET**

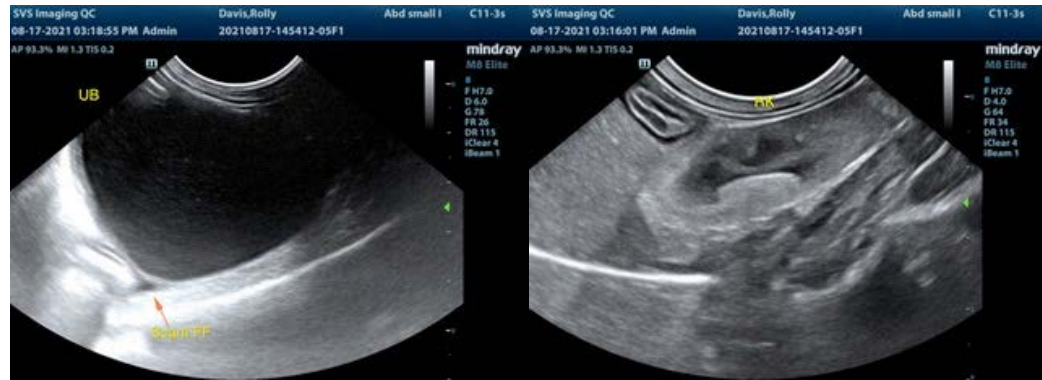Dr. Kulemin

**INVOICE**

24748

**DATE**

8/17/21



The information and recommendations provided are based on the images presented by the referring veterinarian. No evaluation can be communicated regarding pathology that was not visible in the image/video clips provided.

Thank you for this referral. If the clinical or image interpretation does not parallel your findings or if I can be of any further assistance please contact me.

R. McKenzie Daniel, DVM, DABVP (Canine / Feline Practice)  
info@SonoPath.com