**PATIENT**

Junior Witt

SPECIES

Canine

BREED

Pit Bull

SEX

Neutered Male

AGE

14 Years

WEIGHT

57 Pounds

INTERPRETED BYR. McKenzie Daniel, DVM,
DABVP (Canine and Feline)**IMAGING
PERFORMED BY**

Sarah Pender, CVT

HOSPITAL NAME

SVS Imaging QC

REFERRING VET

Dr. Kelli Ruther

INVOICE

24747

DATE

8/17/21

PRESENTING CLINICAL SIGNS

Hematuria and stranguria, reoccurring UTI since April 2021. Painful in back end- suspect arthritis in hips.

Abnormal PE/Chem/CBC/UA Results: UA/C&S- E.coli susceptible to Cefpodoxime (previous allergic reaction to Amoxicillin) 5/11 and 7/22. Started 2 week Cefpodoxime on 7/28. O still seeing hematuria and stranguria 8/10. Abdominal radiographs taken 8/10. No urinary calculi identified. CBC: overall WNL. Chem: K 8.0 (H); Glob 4.7 (H); ALP 752 (H) Extremely painful abdomen during scan.

ULTRASONOGRAPHIC EXAMINATION OF THE ABDOMEN**Urinary System**

The urinary bladder exhibited moderate overall distention with generalized extensive yet variable wall thickening, exhibiting non-homogeneous echogenicity. No overt evidence of mural mineralization. Ventral urinary bladder wall measured up to 2.0 cm in diameter. Anechoic urine was present without evidence of calculi. The proximal urethra exhibited significant thickening to a depth of approximately 4.0 cm. The proximal urethra measured 2.2 cm in width. Regional reactive to inflamed mesentery noted around the urinary bladder. No evidence of concurrent effusion.

The left kidney presented severe hydronephrosis exhibited by replacement of discernable medullary parenchyma with primary anechoic fluid extending into the lateral diverticuli. The left kidney measured 7.9 cm.

The right kidney exhibited mild to moderate hydronephrosis with maintained medullary parenchyma and fluid dilation extending into the lateral diverticuli. The right kidney measured 8.8 cm. Mild proximal right ureter dilation noted. The right ureter dilation measured 0.54 cm diameter. No overt evidence of obstructive nephrolithiasis.

Adrenal Glands

The right adrenal gland was normal in size. Mild parenchyma heterogeneity and mild capsule asymmetry was present without suspicion for overt neoplasia. The right adrenal gland measured 3.3 cm length x 0.99 cm at the caudal pole. No overt pathology in the area of the left adrenal gland.

Spleen

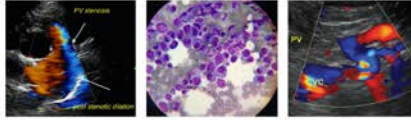
The spleen exhibited a finely textured and homogenous parenchyma which was hyperechoic to the liver and renal cortical parenchyma. The capsule was smooth and regular without apparent expansion. The splenic vasculature at the hilus was normal in volume with no evidence of congestion or thrombosis. Acute to chronic inflammatory, neoplastic, or benign parenchyma changes were not noted.

Liver

The liver exhibited mild generalized enlargement. The liver parenchyma was mildly nonuniform and hypoechoic to the spleen with a moderate coarse echotexture and subjective mild to benign parenchymal remodeling. The hepatic and portal vasculature were normal in appearance without signs of congestion. The gallbladder was non distended in size with mild, echogenic, nonmineralized biliary sludge. The cystic duct and common bile ducts were normal without evidence of dilation.

Gastrointestinal

The stomach presented intact wall layering with a normal wall layer ratio. The lumen of the stomach contained echogenic, nonshadowing ingesta most consistent with post prandial presentation without signs of ileus, obstruction or foreign material.

**PATIENT**

Junior Witt

The small intestine presented intact wall layering with 1:3 muscularis/mucosa ratio. The lumen of the small intestine was empty with no signs of ileus, obstruction or foreign material.

Normal visible colon wall layers were present with apparent formed feces in lumen.

SPECIES***Pancreas***

Canine

The parenchyma of the left limb, body and right limb of the pancreas presented isoechoic to the adjacent omental fat. A normal curvilinear capsule contour of the pancreas was present. The visible pancreatic duct was normal. No signs of active inflammation or neoplastic disease was evident.

BREED

Pit Bull

Free Abdomen

No overt lymphadenopathy.

SEX

Neutered Male

ULTRASONOGRAPHIC FINDINGS

- Generalized severely thickened urinary bladder and proximal urethra
- Left kidney severe hydronephrosis
- Right kidney mild to moderate hydronephrosis with proximal right ureter dilation
- Vacuolar hepatopathy pattern with parenchymal remodeling
- Mild gallbladder debris – non-mucocele
- Mild gastric ingesta – probable post-prandial presentation

AGE

14 Years

WEIGHT

57 Pounds

INTERPRETATION OF THE FINDINGS & FURTHER RECOMMENDATIONS

The severely thickened urinary bladder may indicate severe chronic cystitis or potential extensive bladder tumor. Bladder neoplasia extending into the proximal urethra is favored. Consequently, left and right ureter obstruction (likely at the level of the urinary bladder) with secondary left and right kidney hydronephrosis is suspected. Potential for concurrent chronic left and right kidney pyelonephritis cannot be excluded. Urinary bladder biopsies for histopathology and tissue culture and sensitivity with potential for stent placement, primarily to try to preserve functionality of the right kidney, could be considered. Further assessment with excretory urography may be indicated. However, a very guarded to potentially unfavorable long-term prognosis is likely indicated.

INTERPRETED BY

R. McKenzie Daniel, DVM,
DABVP (Canine and Feline)

IMAGING PERFORMED BY

Sarah Pender, CVT

HOSPITAL NAME

SVS Imaging QC

REFERRING VET

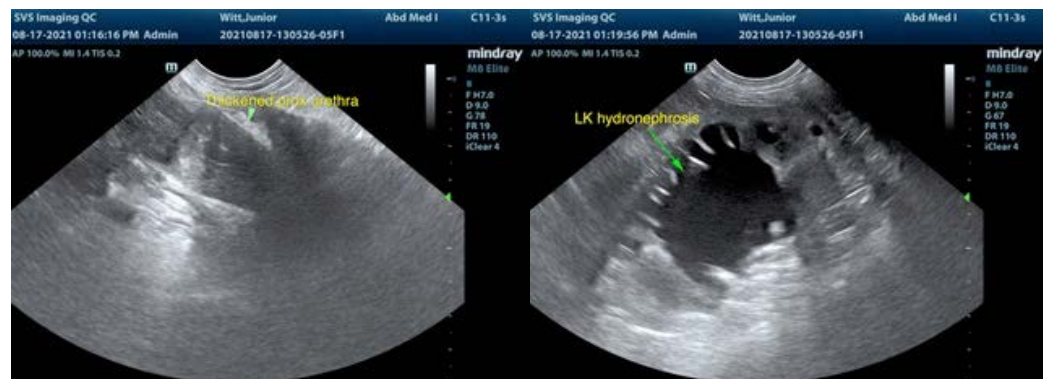
Dr. Kelli Ruther

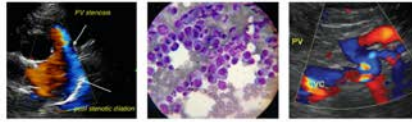
INVOICE

24747

DATE

8/17/21





PATIENT

Junior Witt

SPECIES

Canine

BREED

Pit Bull

SEX

Neutered Male

AGE

14 Years

WEIGHT

57 Pounds

INTERPRETED BY

R. McKenzie Daniel, DVM,
DABVP (Canine and Feline)

IMAGING PERFORMED BY

Sarah Pender, CVT

HOSPITAL NAME

SVS Imaging QC

REFERRING VET

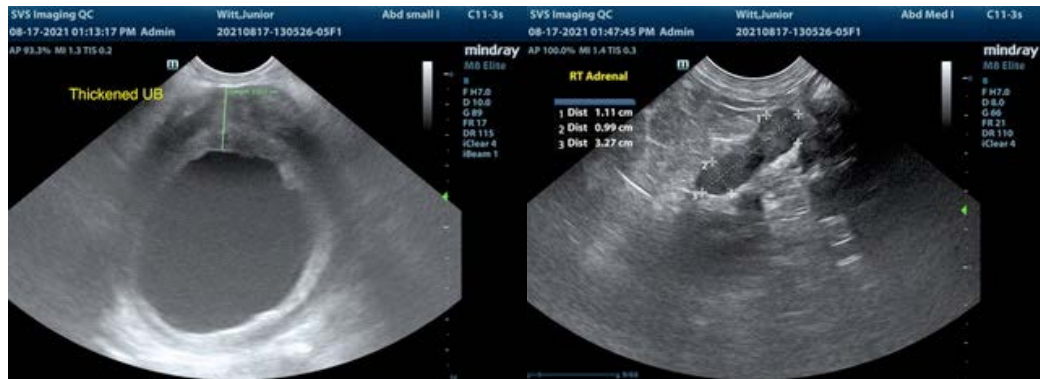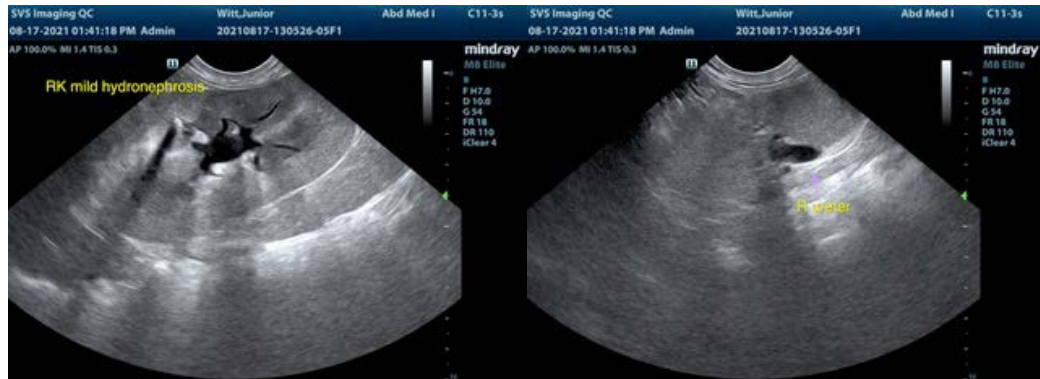
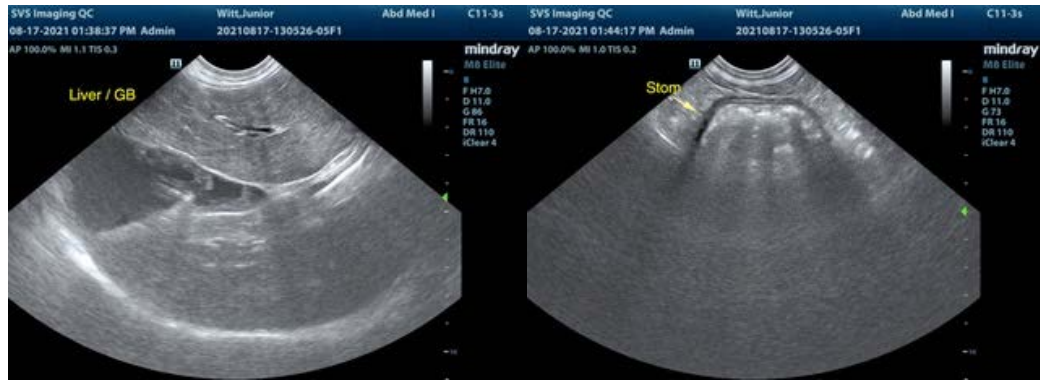Dr. Kelli Ruther

INVOICE

24747

DATE

8/17/21



The information and recommendations provided are based on the images presented by the referring veterinarian. No evaluation can be communicated regarding pathology that was not visible in the image/video clips provided.

Thank you for this referral. If the clinical or image interpretation does not parallel your findings or if I can be of any further assistance please contact me.

R. McKenzie Daniel, DVM, DABVP (Canine / Feline Practice)
info@SonoPath.com