



PATIENT	PRESENTING CLINICAL SIGNS
Rufus Schauer	Rechecking: eating History: 3y 9m old Lab Retriever presents for follow-up of C/S/V/D: straining to defecate E/D/U/D: inappetance, drinking a lot, urinating ok, not defecating/straining to defecate
SPECIES	Abnormal PE/Chem/CBC/UA Results: 8/3 RAD REPORT Testing Performed: abd rads Results: 1) empty GIT 2) suspect mild fluid filled and adynamic colon r/o gastroenteritis
Canine	
	ULTRASONOGRAPHIC EXAMINATION OF THE ABDOMEN
BREED	Urinary System
Retriever	The urinary bladder, trigone, cystourethral junction, and visible pelvic urethra to a depth of 3 cm exhibited normal thickness and tone. Anechoic urine was present in the lumen with no uroliths or sediment. The ureteral papillae were normal. The ureters were not visible which is normal. No evidence of inflammatory or neoplastic changes were noted.
SEX	
MN	Normal size and margination were present in the kidneys. A normal 1:3 cortex / medulla ratio and normal corticomedullary definition were maintained. The echogenicity of the cortex was similar to or slightly less than normal liver parenchyma while the medulla echogenicity was hypoechoic to the cortex with no evidence of pelvic dilation. The left kidney measured 6.8 cm in length. The right kidney measured 6.9 cm in length.
AGE	
3yr	The area of the aortic trifurcation was free of pathology.
WEIGHT	No overt pathology in the area of the residual prostate.
81.9lb	The area of the iliac trifurcation was free of pathology including no evidence of medial, iliac or sublumbar lymphadenopathy.
INTERPRETED BY	Adrenal Glands
R. McKenzie Daniel, DVM, DABVP (Canine and Feline)	The left and right adrenal glands were not definitively visualized.
	Spleen
IMAGING PERFORMED BY	The spleen exhibited mild subnormal size with a finely textured and homogenous parenchyma which was hyperechoic to the liver and renal cortical parenchyma. The capsule was smooth and regular without apparent expansion. The splenic vasculature at the hilus was normal in volume with no evidence of congestion or thrombosis. Acute to chronic inflammatory, neoplastic, or benign parenchyma changes were not noted.
Michaleen	
HOSPITAL NAME	Liver
DPC Veterinary Hospital	The liver was subjectively normal in size, structure, and contour. The liver parenchyma was uniform and hypoechoic to the spleen with a mild coarse echotexture. The hepatic and portal vasculature were normal in appearance without signs of congestion. The gallbladder was non-distended in size with thin walls and primarily anechoic luminal content with mild hyperechoic luminal debris-likely incidental. The cystic and common bile ducts were normal.
REFERRING VET	
Dr. White	
INVOICE	Gastrointestinal
11378ag	The stomach was indistinctly visualized yet appeared to be primarily empty containing luminal gas and overtly normal wall layering.
DATE	The intestinal tract exhibited segmental moderate to variable hypoechoic mural hypertrophy with loss of discernable wall layering and associated segmental paralytic ileus. Additional segments were markedly
08/16/2022	



PATIENT

Rufus Schauer

distended with retained focally shadowing ingesta/chyme. Concurrent segments were also primarily empty exhibiting intact wall layering. Colon distention containing non formed fecal matter was present.

Pancreas

SPECIES

Canine

The parenchyma of the left limb, body and right limb of the pancreas presented isoechoic to the adjacent omental fat. A normal curvilinear capsule contour of the pancreas was present. The visible pancreatic duct was normal. No signs of active inflammation or neoplastic disease was evident.

BREED

Retriever

Free Abdomen

Regional peri-intestinal hyperechoic mesentery surrounding the abnormal intestinal segments was present.

SEX

MN

No overt lymphadenopathy or peritoneal effusion was present.

ULTRASONOGRAPHIC FINDINGS

AGE

3yr

- Segmental moderately thickened intestine to segmental potentially multifocal intestinal mural masses with associated suspected paralytic ileus
- Segmental moderate to markedly dilated intestine containing focally shadowing ingesta/chyme
- Volume contracted spleen
- Peri-intestinal hyperechoic reactive/inflamed mesentery

WEIGHT

81.9lb

INTERPRETATION OF THE FINDINGS & FURTHER RECOMMENDATIONS

The primary finding of segmental intestinal mural pathology with potential for partial obstruction may indicate severe inflammatory intestinal disease with primary concern for infiltrative pathology i.e. neoplasia, fungal or other. Given the extent of the intestinal pathology, definitive segments involved was difficult to ascertain. Primary small intestinal, large intestinal or potential for mixed mural pathology is possible. Intestinal biopsies would be required for a definitive diagnosis.

Three view chest radiographs suggested if not done to assess for thoracic pathology.

Abdominal CT is likely ideal for further assessment and surgical planning if possible.

INTERPRETED BY

R. McKenzie Daniel,
DVM, DABVP
(Canine and Feline)

IMAGING PERFORMED BY

Michaleen

HOSPITAL NAME

DPC Veterinary
Hospital

REFERRING VET

Dr. White

INVOICE

11378ag

DATE

08/16/2022



PATIENT

Rufus Schauer

SPECIES

Canine

BREED

Retriever

SEX

MN

AGE

3yr

WEIGHT

81.9lb

INTERPRETED BY

R. McKenzie Daniel,
DVM, DABVP
(Canine and Feline)

IMAGING PERFORMED BY

Michaleen

HOSPITAL NAME

DPC Veterinary
Hospital

REFERRING VET

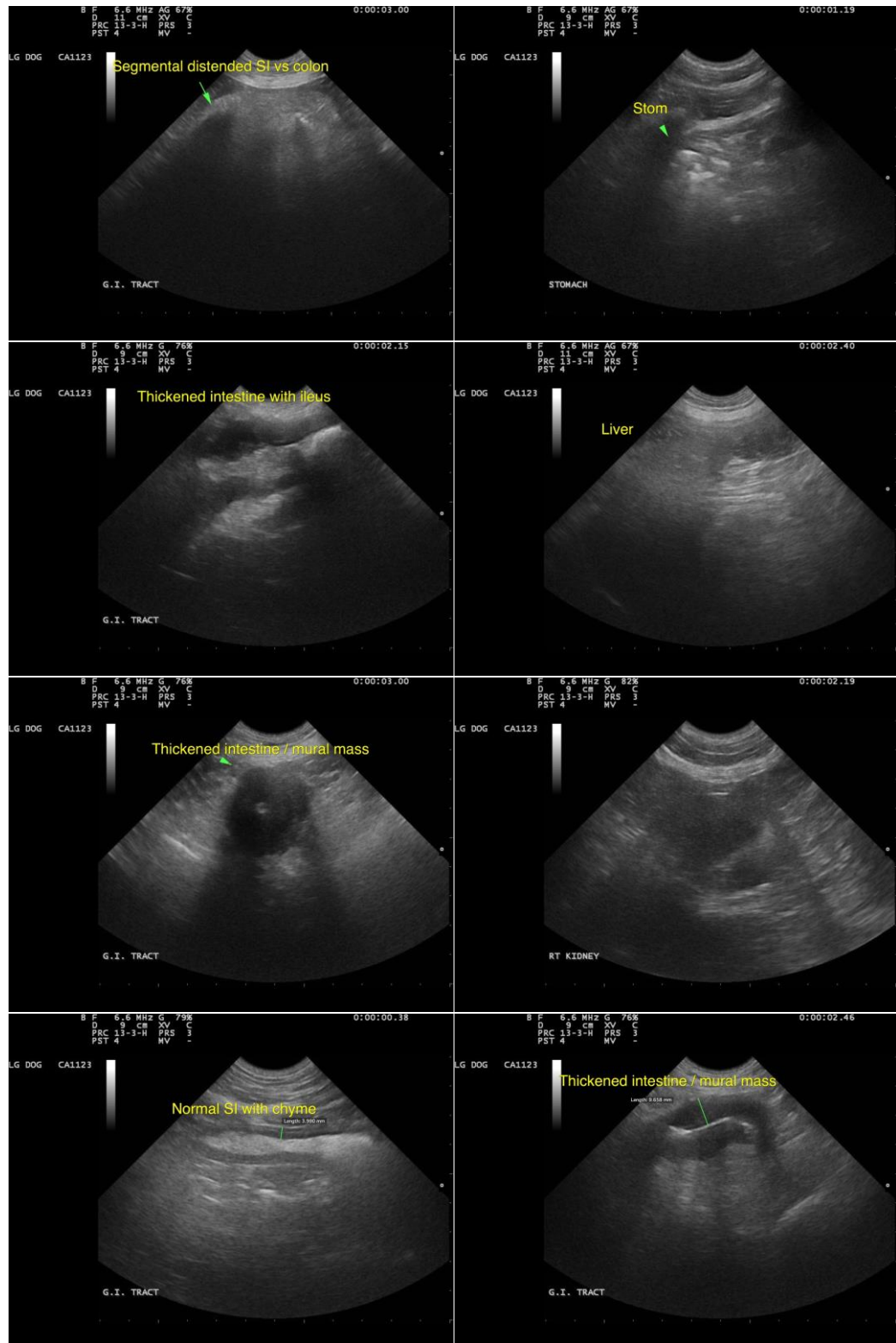
Dr. White

INVOICE

11378ag

DATE

08/16/2022





PATIENT

Rufus Schauer

SPECIES

Canine

BREED

Retriever

SEX

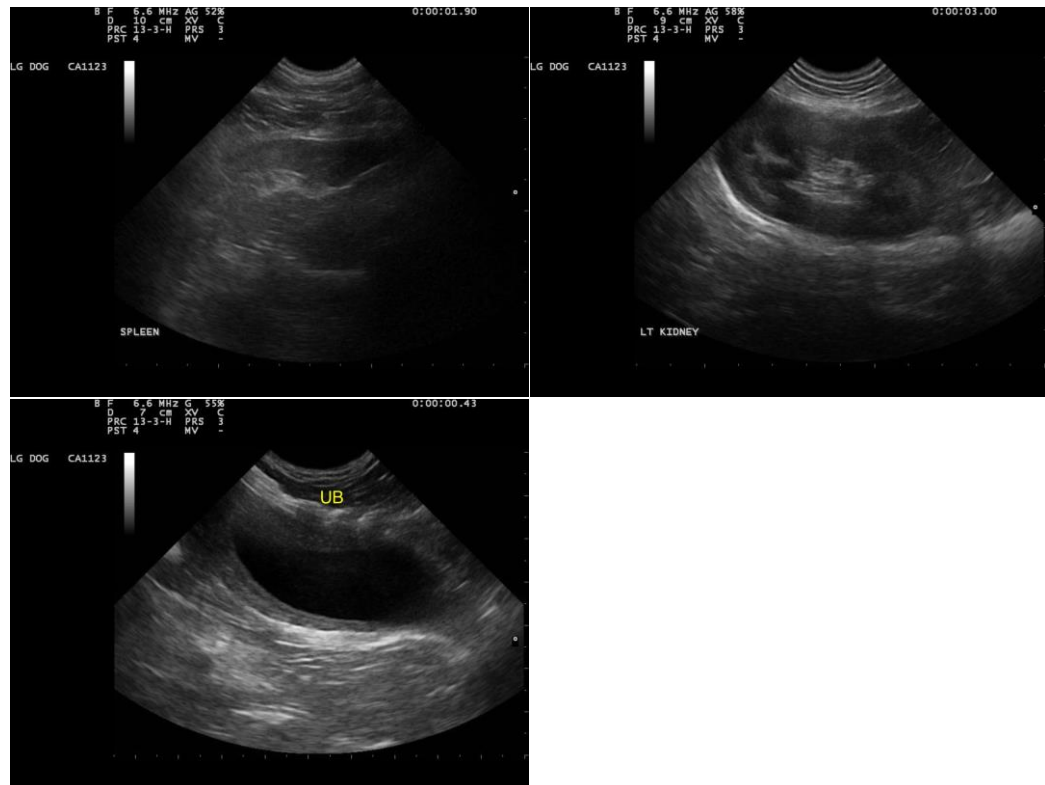
MN

AGE

3yr

WEIGHT

81.9lb



The information and recommendations provided are based on the images presented by the referring veterinarian/sonographer. No evaluation can be communicated regarding pathology that was not visible in the image/video clips provided.

INTERPRETED BY

R. McKenzie Daniel,
DVM, DABVP
(Canine and Feline)

Thank you for this referral. If the clinical or image interpretation does not parallel your findings or if I can be of any further assistance please contact me.

R. McKenzie Daniel, DVM, DABVP (Canine / Feline Practice)

IMAGING PERFORMED BY

Michaleen

info@SonoPath.com

HOSPITAL NAME

DPC Veterinary
Hospital

REFERRING VET

Dr. White

INVOICE

11378ag

DATE

08/16/2022