



PATIENT

Kitty Russel
Milonotoulos

SPECIES

Feline

BREED

DSH

SEX

FS

AGE

4yr

WEIGHT

9.8lb

PRESENTING CLINICAL SIGNS

Finding of elevated proBNP.

Abnormal PE/Chem/CBC/UA Results: June 29th, proBNP 156. Remainder of labs and exam wnl. BP 192, unlikely true as P had no anxiolytics onboard.

ULTRASONOGRAPHIC EXAMINATION OF THE HEART

FELINE CARDIAC PARAMETERS	BODY WEIGHT (kg)	HR (BPM)	IVSd (cm)	LVIDd (cm)	LVWd (cm)	FS (%)	EF (%)
NORMAL PARAMETER	-----	150-240	0.3-0.6	1.0-2.1	0.25-0.6	35-67	80-100
PATIENT		NM	0.5	1.2	0.4	50	80
FELINE CARDIAC PARAMETERS	LA/AO (Boon)	LA/AO HEART BASE (Sisson)	LA 2D 4-chamber long axis AS to FW (Sisson) (cm)		LVOT VEL. (m/s)	RVOT VEL. (m/s)	IVRT (m/)
NORMAL PARAMETER	<1.5	0.88-1.79	0.7-1.7		<1.6	<1.3	40-60
PATIENT		1.2	1.2		1.0	1.1	
Adapted from June Boon, Veterinary Echocardiography, 1998							
Sisson D et al. JVIM 1991; 5: 232, Jacobs et al. Am J Vet Res 1985; 46:1705							

INTERPRETED BY

R. McKenzie Daniel,
DVM, DABVP
(Canine and Feline)

IMAGING PERFORMED BY

Sorbo

HOSPITAL NAME

Cambridge Veterinary
Care

REFERRING VET

Sorbo

INVOICE

14628ag

DATE

08/15/2023

Cardiac Presentation

The echocardiogram in this patient demonstrated normal left atrial size based on 3 separate LA measurements. The cranial and caudal mitral valve leaflets presented normal linear structure and kinetics. No overt MR present on Doppler. The left ventricle presented normal thicknesses with linear contour and was not dilated nor restricted. The myocardium presented normal echogenicity without subjective evidence of significant fibrotic or ischemic disease. The contractility of the ventricular walls was adequate and in normal range for this patient evidenced by the fractional shortening measurement and subjective evaluation of the different regions and angles of the myocardium. The left ventricular outflow tract demonstrated normal laminar flow and subjective structural integrity. Normal measured LVOT velocity was present. The right atrium and auricle revealed normal size, structure and content. No evidence of masses was noted or chamber overload. Tricuspid valvular assessment demonstrated adequate linear morphology and kinetics. No overt TR present on Doppler. The right ventricle was of normal size (1/3 diameter of LV), chordae structure, myocardial echogenicity and thickness. Pulmonic tract assessment revealed normal valve structure, laminar flow, and diameter (approx. 1:1 pa/ao ratio). Normal measured RVOT velocity was present. No visible pericardial or free pleura fluid was noted or extra cardiac pathology in the visible planes. The cranial mediastinum and pericardial regions were free of masses in the visible window.



PATIENT

Kitty Russel
Milonotoulos

ULTRASONOGRAPHIC FINDINGS

- Normal echocardiogram.

SPECIES

Feline

INTERPRETATION OF THE FINDINGS & FURTHER RECOMMENDATIONS

No evidence of structural or functional cardiomyopathy was present in this study including no evidence of overt HCM criteria, left/right heart chamber enlargement, LV systolic dysfunction, clinical pulmonary hypertension, significant valvular insufficiencies or arrhythmia. The lack of left/right heart chamber enlargement, specifically the lack of LA enlargement, indicates that any potential risk of clinical cardiomyopathy is low.

BREED

DSH

No indication for cardiac medications. Monitoring of pro BNP is suggested with potential recheck echocardiogram if progressive BNP elevations or development of a murmur.

SEX

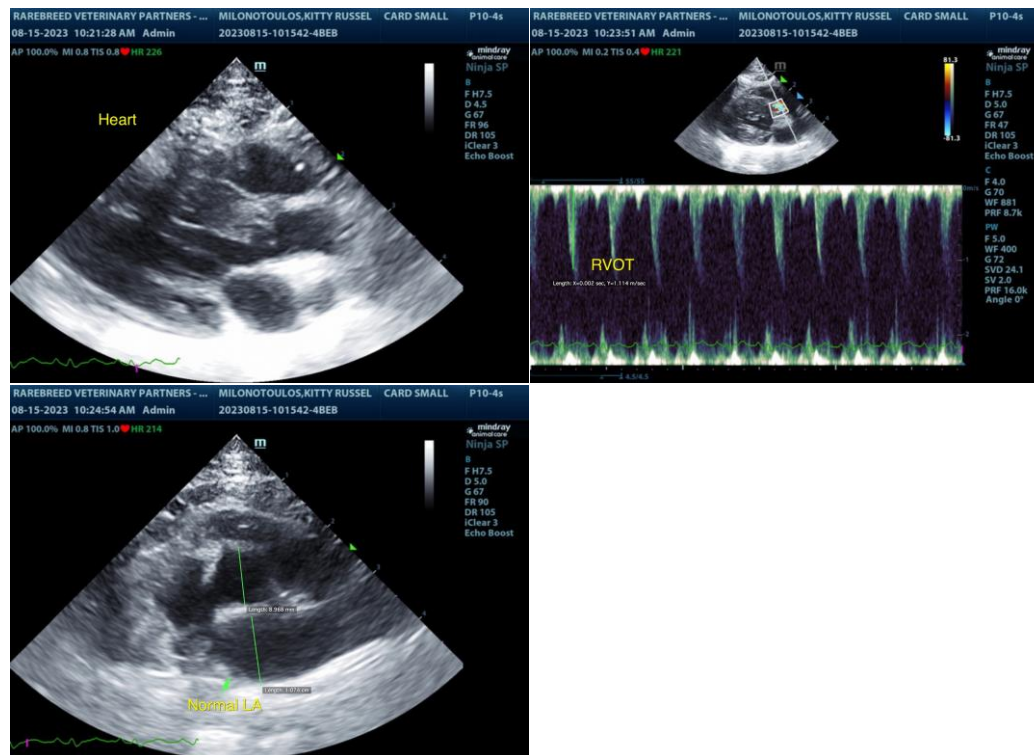
FS

AGE

4yr

WEIGHT

9.8lb



INTERPRETED BY

R. McKenzie Daniel,
DVM, DABVP
(Canine and Feline)

IMAGING PERFORMED BY

Sorbo

HOSPITAL NAME

Cambridge Veterinary
Care

REFERRING VET

Sorbo

The information and recommendations provided are based on the images presented by the referring veterinarian/sonographer. No evaluation can be communicated regarding pathology that was not visible in the image/video clips provided.

Thank you for this referral. If the clinical or image interpretation does not parallel your findings or if I can be of any further assistance, please contact me.

INVOICE

14628ag

R. McKenzie Daniel, DVM, DABVP (Canine/Feline Practice)

DATE

08/15/2023



PATIENT

info@sonopath.com

Kitty Russel
Milonotoulos

SPECIES

Feline

BREED

DSH

SEX

FS

AGE

4yr

WEIGHT

9.8lb

INTERPRETED BY

R. McKenzie Daniel,
DVM, DABVP
(Canine and Feline)

**IMAGING
PERFORMED BY**

Sorbo

HOSPITAL NAME

Cambridge Veterinary
Care

REFERRING VET

Sorbo

INVOICE

14628ag

DATE

08/15/2023