



PATIENT

Jackie Nemchik

SPECIES

Feline

BREED

DSH-Calico

SEX

FS

AGE

18 years

WEIGHT

10 lbs.

INTERPRETED BY

R. McKenzie Daniel,
DVM, DABVP
(Canine and Feline)

IMAGING PERFORMED BY

Meredith Swart

HOSPITAL NAME

Swart Veterinary
Imaging

REFERRING VET

Meredith Swart

INVOICE

14808

DATE

8/15/23

PRESENTING CLINICAL SIGNS

Known murmur. Patient is also hyperthyroid- well managed. Patient in need of dental so echo is pre-operative.

Abnormal PE/Chem/CBC/UA Results: Labwork last run last year, WNL including BNP

ULTRASONOGRAPHIC EXAMINATION OF THE HEART

FELINE CARDIAC PARAMETERS	BODY WEIGHT (kg)	HR (BPM)	IVSd (cm)	LVIDd (cm)	LVWd (cm)	FS (%)	EF (%)
NORMAL PARAMETER	-----	150-240	0.3-0.6	1.0-2.1	0.25-0.6	35-67	80-100
PATIENT		NM	0.51	1.1	0.52	49	80
FELINE CARDIAC PARAMETERS	LA/AO (Boon)	LA/AO HEART BASE (Sisson)	LA 2D 4-chamber long axis AS to FW (Sisson) (cm)	LVOT VEL. (m/s)	RVOT VEL. (m/s)	IVRT (m/)	
NORMAL PARAMETER	<1.5	0.88-1.79	0.7-1.7	<1.6	<1.3	40-60	
PATIENT	1.24	1.3	1.2	NM	0.92	NM	
Adapted from June Boon, Veterinary Echocardiography, 1998 Sisson D et al. JVIM 1991; 5: 232, Jacobs et al. Am J Vet Res 1985; 46:1705							

Cardiac Presentation

The echocardiogram in this patient demonstrated normal **left atrial** size based on 3 separate LA measurements. The cranial and caudal **mitral** valve leaflets presented normal linear structure and kinetics. No obvious MR on doppler. The **left ventricle** presented normal thicknesses with linear contour and was not dilated nor restricted. The **myocardium** presented normal echogenicity without subjective evidence of significant fibrotic or ischemic disease. **Contractility** of the ventricular walls was adequate and in normal range for this patient evidenced by the fractional shortening measurement and subjective evaluation of the different regions and angles of the myocardium. The **left ventricular outflow** tract demonstrated normal laminar flow and subjective structural integrity. The **right atrium** and auricle revealed normal size, structure and content. No evidence of masses was noted or chamber overload. **Tricuspid** valvular assessment demonstrated adequate linear morphology and kinetics. The **right ventricle** was of normal size (1/3 diameter of LV), chordae structure, myocardial echogenicity and thickness. **Pulmonic** tract assessment revealed normal valve structure, laminar flow, and diameter (approx. 1:1 pa/ao ratio). Normal measured RVOT velocity was noted. No visible **pericardial** or free pleura fluid was noted or extra cardiac pathology in the visible planes. The cranial **mediastinum and pericardial regions** were free of masses in the visible window.

ULTRASONOGRAPHIC FINDINGS

- Normal echocardiogram



PATIENT

Jackie Nemchik

SPECIES

Feline

BREED

DSH-Calico

SEX

FS

AGE

18 years

WEIGHT

10 lbs.

INTERPRETED BY

R. McKenzie Daniel,
DVM, DABVP
(Canine and Feline)

IMAGING PERFORMED BY

Meredith Swart

HOSPITAL NAME

Swart Veterinary
Imaging

REFERRING VET

Meredith Swart

INVOICE

14808

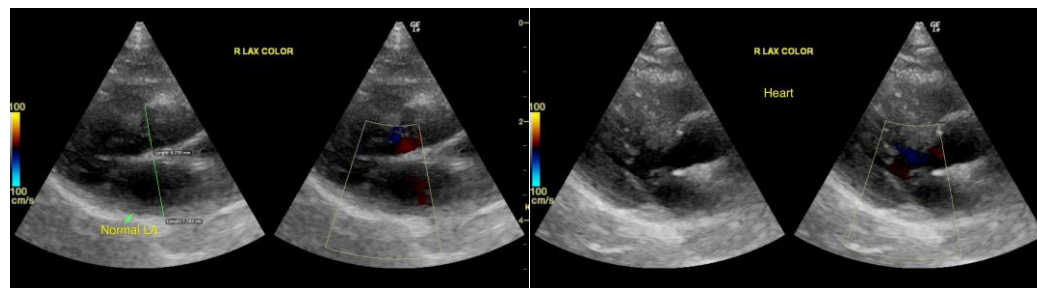
DATE

8/15/23

INTERPRETATION OF THE FINDINGS & FURTHER RECOMMENDATIONS

There was no evidence of structural or functional cardiomyopathy including no evidence of HCM, left or right heart chamber enlargement, LV systolic dysfunction, overt or significant valvular insufficiencies, or clinical pulmonary hypertension. Assuming no evidence of volume changes such as dehydration or anemia, a benign physiologic / flow murmur is considered probable, although a small non-sonographically evident flow abnormality cannot be definitively excluded. Regardless, the lack of left or right heart chamber enlargement indicates that the heart is stable and that the hemodynamic effects of the murmur are low. There is no indication for cardiac medications. Continued monitoring of the murmur is recommended with a recheck echocardiogram suggested if clinical signs consistent with heart disease arise or if murmur intensity increases. There are no anesthetic contraindications.

Suggested anesthetic protocol may include opioid or Benzodiazepine pre-med, induction with Propofol or Alfaxalone, and appropriate gas anesthesia with avoidance of alpha 2 agonists.



The information and recommendations provided are based on the images presented by the referring veterinarian/sonographer. No evaluation can be communicated regarding pathology that was not visible in the image/video clips provided.

Thank you for this referral. If the clinical or image interpretation does not parallel your findings or if I can be of any further assistance please contact me.

R. McKenzie Daniel, DVM, DABVP (Canine / Feline Practice)
info@SonoPath.com