



PATIENT	PRESENTING CLINICAL SIGNS
Oliver Furlong	Animal had a heart murmur diagnosed in 2019, no extensive cardiac workup at that time. Animal presented 8/5/22 to HV, ADR, mildly pale gums. Was not eating well. Treated with supportive care and Sr Labs sent out. HR 120, RR 30 Heart murmur G3/6 Current Medications: SQF and Entyce
SPECIES	Abnormal PE/Chem/CBC/UA Results: Evidence of chronic bleeding on labs Rads of chest and abdomen - Radiologist noted hepatomegaly and small, suspected nodules in chest (See attached rad report)
Canine	
BREED	ULTRASONOGRAPHIC EXAMINATION OF THE ABDOMEN
German Shorthair Pointer	Urinary System
SEX	The urinary bladder, trigone, cystourethral junction, and visible pelvic urethra exhibited normal thickness and tone. Anechoic urine was present in the lumen with no uroliths or sediment. The ureteral papillae were normal. The ureters were not visible which is normal. No evidence of inflammatory or neoplastic changes were noted.
MN	
AGE	Normal size and margination was present in the kidneys. A normal 1:3 cortex / medulla ratio was maintained. The medulla and cortices were uniform in texture with some increased echogenicity and mild loss of corticomedullary symmetry and definition expected for the age of the patient. No evidence of pelvic dilation was present. The left kidney measured 6.7 cm in length. The right kidney measured 6.9 cm in length.
11yr	
WEIGHT	The area of the aortic trifurcation was free of pathology.
53.6lb	Adrenal Glands
INTERPRETED BY	The bilateral adrenal glands were normal in size. Mild parenchyma heterogeneity and mild capsule asymmetry was present without suspicion for overt neoplasia. The left adrenal gland measured 2.2 cm length and 0.40 cm width in the caudal pole. The right adrenal gland measured 2.4 cm length and 0.59 cm width in the caudal pole.
R. McKenzie Daniel, DVM, DABVP (Canine and Feline)	Spleen
IMAGING PERFORMED BY	The spleen exhibited overall normal size and contour with generalized mild parenchyma heterogeneity and multiple mildly expansive hypoechoic splenic nodules, an example measuring 1.5 cm in diameter. The splenic vasculature at the hilus was normal in volume with no evidence of congestion or thrombosis.
Amanda Lacey Crook	Liver
HOSPITAL NAME	The liver was subjectively mildly enlarged with mildly rounded capsule contour and generalized non-homogeneous parenchyma exhibiting evidence of remodeling. Multiple variably sized isoechoic to variably echogenic intraparenchymal nodules were present, an example measuring 5.3 cm in diameter. Suspect indistinct nodular intraparenchymal mass in the left liver measuring ~ 8 cm in diameter. The hepatic and portal vasculature were normal in appearance without signs of congestion.
Rivers Edge Pet Medical Center	INVOICE
REFERRING VET	The gallbladder was non-distended in size with thin walls and primarily anechoic luminal content. The cystic and common bile ducts were normal.
Dr. Christensen	Gastrointestinal
INVOICE	
11372ag	
DATE	
08/15/2022	



PATIENT

Oliver Furlong

The stomach presented intact wall layering with a normal wall layer ratio. The lumen of the stomach contained mild to moderate ingesta exhibiting progressive distal acoustic shadowing with no signs of ileus, obstruction or foreign material. The pylorus wall measured 0.45 cm in width.

SPECIES

Canine

The small intestine presented intact wall layering with 1:3 muscularis/mucosa ratio. The lumen of the small intestine was empty with no signs of ileus, obstruction or foreign material.

Normal visible colon wall layers were present with apparent formed feces in lumen.

BREED

German Shorthair
Pointer

Pancreas

The parenchyma of the left limb, body and right limb of the pancreas presented isoechoic to the adjacent omental fat. A normal curvilinear capsule contour of the pancreas was present. The visible pancreatic duct was normal. No signs of active inflammation or neoplastic disease was evident.

SEX

MN

Free Abdomen

No overt lymphadenopathy was present.

AGE

11yr

Small pockets of scant perihepatic to peritoneal free fluid were present.

WEIGHT

53.6lb

ULTRASONOGRAPHIC FINDINGS

- Hepatomegaly exhibiting nodular parenchyma, suspect indistinct nodular intraparenchymal mass in the left liver-vacuolar hepatopathy, inflammatory hepatopathy, hyperplasia, hematopoiesis, fibrosis, neoplasia or other
- Non-specific splenic nodules-hyperplasia, hematopoiesis, hematomas, infection/splenitis, infarcts or neoplasia
- Small pockets of scant peritoneal free fluid
- Overtly normal GI tract with progressively shadowing gastric ingesta
- Mild chronic renal changes

INTERPRETED BY

R. McKenzie Daniel,
DVM, DABVP
(Canine and Feline)

INTERPRETATION OF THE FINDINGS & FURTHER RECOMMENDATIONS

Concern for potential multicentric hepatosplenic neoplasia is warranted given the sonographic abnormalities. Assuming normal clotting status and using a 25g needle a hepatosplenic FNA is recommended for screening cytology and further clarification.

IMAGING PERFORMED BY

Amanda Lacey Crook

The progressively shadowing gastric ingesta is non-specific and may indicate post prandial presentation. Correlation with most recent meal ingestion is suggested. If NPO, some degree of gastric stasis could be possible. Monitoring for evidence of gastric emptying over the next 24 hours could be considered.

HOSPITAL NAME

Rivers Edge Pet
Medical Center

REFERRING VET

Dr. Christensen

INVOICE

11372ag

DATE

08/15/2022



PATIENT

Oliver Furlong

SPECIES

Canine

BREED

German Shorthair
Pointer

SEX

MN

AGE

11yr

WEIGHT

53.6lb

INTERPRETED BY

R. McKenzie Daniel,
DVM, DABVP
(Canine and Feline)

**IMAGING
PERFORMED BY**

Amanda Lacey Crook

HOSPITAL NAME

Rivers Edge Pet
Medical Center

REFERRING VET

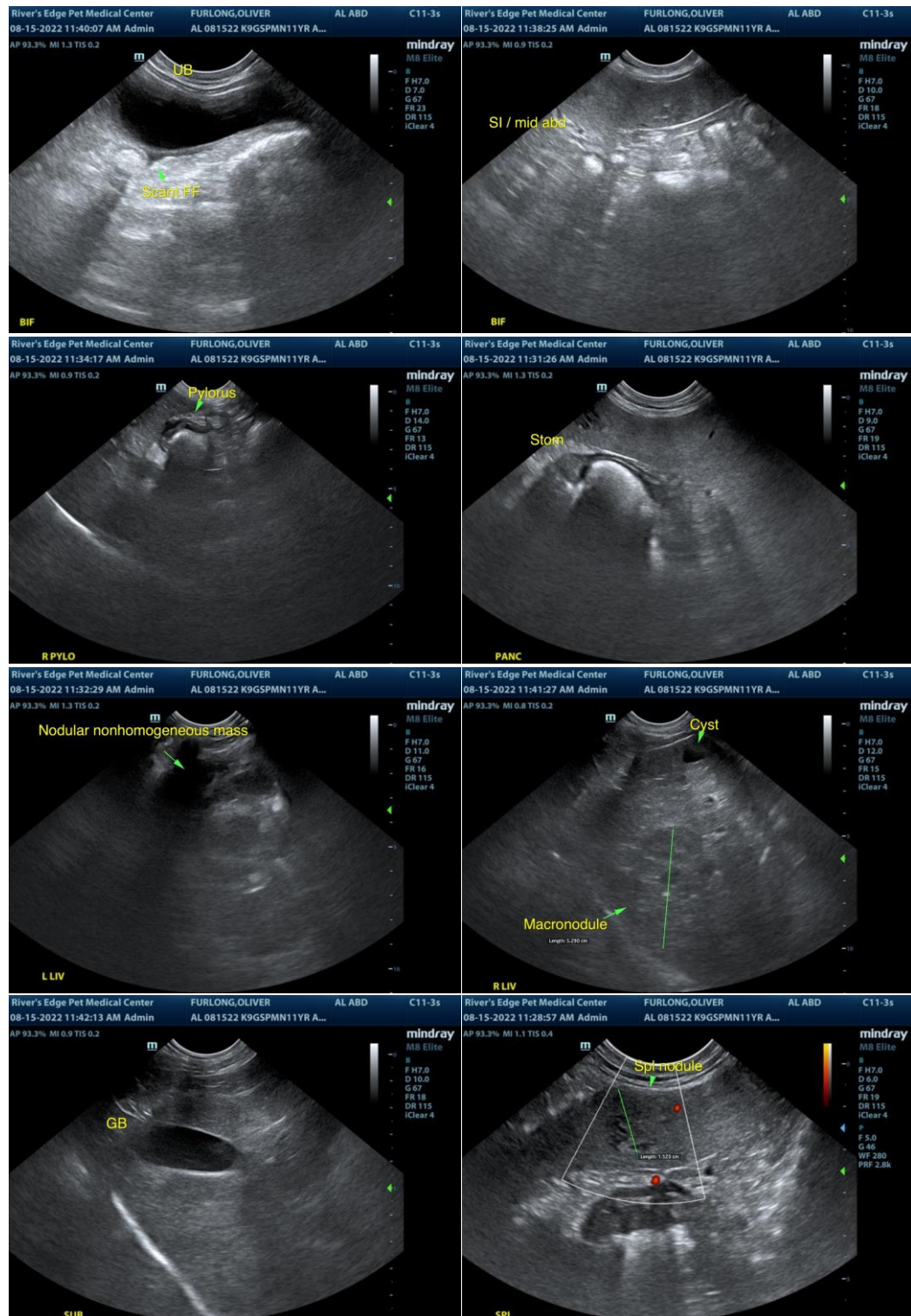
Dr. Christensen

INVOICE

11372ag

DATE

08/15/2022





PATIENT

Oliver Furlong

SPECIES

Canine

BREED

German Shorthair
Pointer

SEX

MN

AGE

11yr

WEIGHT

53.6lb

INTERPRETED BY

R. McKenzie Daniel,
DVM, DABVP
(Canine and Feline)

**IMAGING
PERFORMED BY**

Amanda Lacey Crook

HOSPITAL NAME

Rivers Edge Pet
Medical Center

REFERRING VET

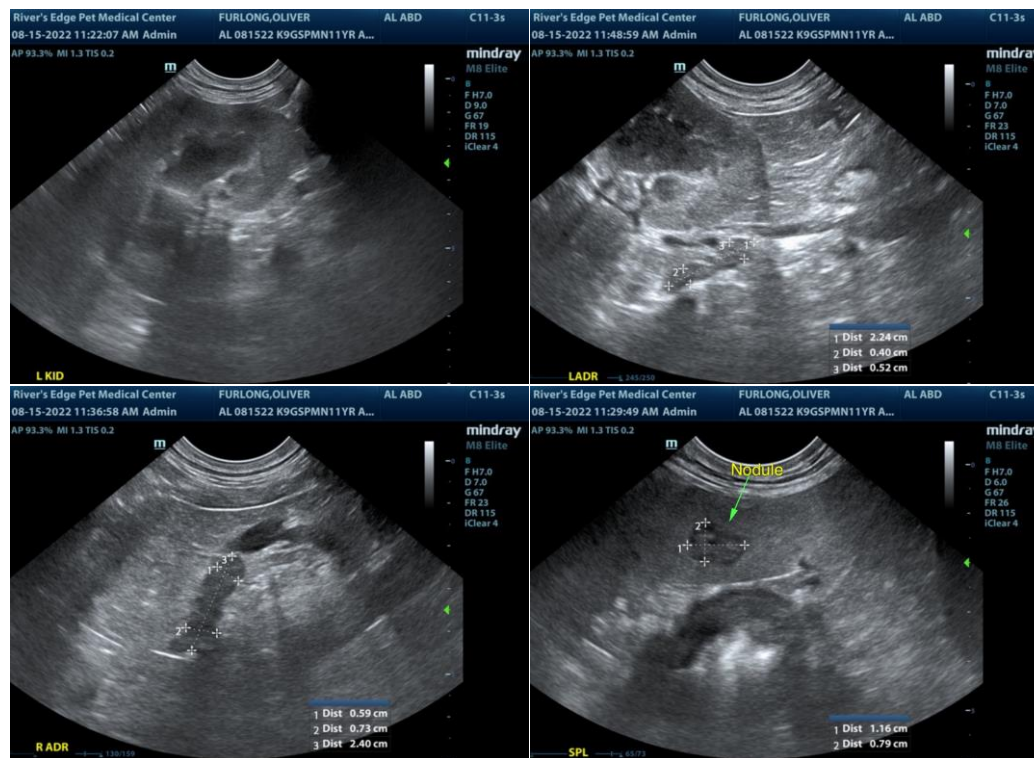
Dr. Christensen

INVOICE

11372ag

DATE

08/15/2022



The information and recommendations provided are based on the images presented by the referring veterinarian/sonographer. No evaluation can be communicated regarding pathology that was not visible in the image/video clips provided.

Thank you for this referral. If the clinical or image interpretation does not parallel your findings or if I can be of any further assistance please contact me.

R. McKenzie Daniel, DVM, DABVP (Canine / Feline Practice)

info@SonoPath.com