
**PATIENT**

Daisy Leach

**PRESENTING CLINICAL SIGNS**

History: Wobbly hind end, shifting leg lameness. Seems weak per O. Current meds: Doxy 400mg 1/2 bid, Novox 75mg bid

**SPECIES**

Canine

Abnormal PE/Chem/CBC/UA Results: WNL incl. 4dx

**ULTRASONOGRAPHIC EXAMINATION OF THE ABDOMEN AND HEART**

BREED	CANINE CARDIAC PARAMETERS	MR VMAX (m/s)	TR VMAX (m/s)	LA/AO (Boon method)	LA/AO (Heart Base; Swe)	FS (%)	EF (%)	EPSS (cm)
Golden Mix								
SEX	NORMAL PARAMETER	4.5-5.5	<2.7	1.3	<1.3	28-40	40-100	<0.6
F	PATIENT				1.2	27.5	54	0.37
AGE	CANINE CARDIAC PARAMETERS	HR (BPM)	AV VMAX (m/s)	PV MAX (m/s)	BODY WEIGHT (kg)	LA 2D short axis Base view (cm)	LVIDd Avg; 2D and m-mode short axis (cm)	LVIDs Avg; 2D and m-mode short axis (cm)
2yr								
WEIGHT	NORMAL PARAMETER	50-100	0.7-1.7	0.7-1.6				
89lb	PATIENT	82	1.47	1.0		3.9	4.1	

**INTERPRETED BY**

 R. McKenzie Daniel,  
 DVM, DABVP  
 (Canine and Feline)

**Cardiac Presentation**

The echocardiogram in this patient demonstrated normal left atrial size based on 3 separate methods of LA evaluation. The cranial and caudal mitral valve leaflets presented normal linear structure, extension in systole, and union in diastole with normal kinesis. The left ventricle presented thicknesses with linear contour and was not dilated nor restricted. The myocardium presented normal echogenicity without subjective evidence of significant fibrotic or ischemic disease. Contractility of the ventricular walls was mildly subnormal yet adequate and in normal range for this patient evidenced by the fractional shortening measurement and subjective evaluation of the different regions of the myocardium. The left ventricular outflow tract demonstrated normal laminar flow and subjective structural integrity. The right atrium and auricle revealed normal size, structure and content. No evidence of masses was noted. Tricuspid valvular assessment demonstrated adequate linear morphology and kinesis. The right ventricle was of normal size (1/3 diameter of LV), chordae structure, myocardial echogenicity and thickness. Pulmonary outflow tract assessment revealed normal valve structure, laminar flow, and diameter (approx.1:1 pa/ao ratio). No visible pericardial or free pleura fluid was noted. The cranial mediastinum and pericardial and extra-cardiac regions were free of masses in the visible window. Possible mild bradycardia, no evidence of arrhythmia.

**IMAGING PERFORMED BY**

Shari Reffi CVT

**HOSPITAL NAME**

 Animal Hospital of  
 Sussex County

**REFERRING VET**

Dr. Spinks

**Urinary System**
**INVOICE**

11355ag

The urinary bladder, trigone, cystourethral junction, and visible pelvic urethra to a depth of 2 cm exhibited normal thickness and tone. Anechoic urine was present in the lumen with no uroliths or sediment. The ureteral papillae were normal. The ureters were not visible which is normal. No evidence of inflammatory or neoplastic changes were noted.

**DATE**

08/15/2022

Normal size and margination were present in the kidneys. A normal 1:3 cortex / medulla ratio and normal corticomedullary definition were maintained. The echogenicity of the cortex was similar to or slightly



<b>PATIENT</b>	less than normal liver parenchyma while the medulla echogenicity was hypoechoic to the cortex with no evidence of pelvic dilation. The left kidney measured 6.4 cm in length. The right kidney measured 7.1 cm in length.
Daisy Leach	
<b>SPECIES</b>	The area of the aortic trifurcation was free of pathology.
Canine	No overt pathology in the area of the bilateral ovaries or uterus.
<b>BREED</b>	<b>Adrenal Glands</b>
Golden Mix	Both adrenal glands were subnormal in size compared to expected size given breed and body weight with normal position. The left adrenal gland measured 0.45 cm width at the caudal pole and 0.35 cm width at the cranial pole. The right adrenal gland measured 0.38 cm width at the caudal pole and 0.43 cm width at the cranial pole.
<b>SEX</b>	<b>Spleen</b>
F	The spleen exhibited a finely textured and homogenous parenchyma which was hyperechoic to the liver and renal cortical parenchyma. The capsule was smooth and regular without apparent expansion. The splenic vasculature at the hilus was normal in volume with no evidence of congestion or thrombosis. Acute to chronic inflammatory, neoplastic, or benign parenchyma changes were not noted.
<b>AGE</b>	
2yr	
<b>WEIGHT</b>	<b>Liver</b>
89lb	The liver was subjectively subnormal in size with normal structure, and contour. The liver parenchyma was uniform and hypoechoic to the spleen with a mild coarse echotexture. The hepatic and portal vasculature was subjectively adequate without signs of congestion.
<b>INTERPRETED BY</b>	The gallbladder was non-distended in size with thin walls and primarily anechoic luminal content. The cystic and common bile ducts were normal.
R. McKenzie Daniel, DVM, DABVP (Canine and Feline)	<b>Gastrointestinal</b>
<b>IMAGING PERFORMED BY</b>	The stomach presented intact wall layering with a normal wall layer ratio. The lumen of the stomach was empty with no signs of ileus, obstruction or foreign material.
Shari Reffi CVT	The small intestine presented intact wall layering with 1:3 muscularis/mucosa ratio. The duodenum exhibited potential for mild ileus. The lumen of the small intestine was empty with no signs of obstruction or foreign material.
<b>HOSPITAL NAME</b>	Normal visible colon wall layers were present with apparent formed feces in lumen.
Animal Hospital of Sussex County	<b>Pancreas</b>
<b>REFERRING VET</b>	The parenchyma of the left limb, body and right limb of the pancreas presented isoechoic to the adjacent omental fat. A normal curvilinear capsule contour of the pancreas was present. The visible pancreatic duct was normal. No signs of active inflammation or neoplastic disease was evident.
Dr. Spinks	<b>Free Abdomen</b>
<b>INVOICE</b>	No overt lymphadenopathy or peritoneal effusion was present.
11355ag	<b>ULTRASONOGRAPHIC FINDINGS</b>
<b>DATE</b>	<ul style="list-style-type: none"> <li>• Normal echocardiogram with mild subnormal yet adequate LV contractility</li> <li>• Subnormal bilateral adrenal glands</li> <li>• Subjective borderline subnormal liver size</li> </ul>
08/15/2022	



**PATIENT**

- Mild duodenal ileus, possible mild duodenitis

Daisy Leach

**INTERPRETATION OF THE FINDINGS & FURTHER RECOMMENDATIONS**

**SPECIES**

No overt evidence of structural or functional cardiomyopathy as an obvious cause of the patient's weakness or hind leg abnormalities. DCM criteria is not present. No indication for cardiac medications.

Canine

A resting cortisol level with ACTH stim is strongly suggested to assess for or rule out Addison's disease given the subnormal adrenal size.

**BREED**

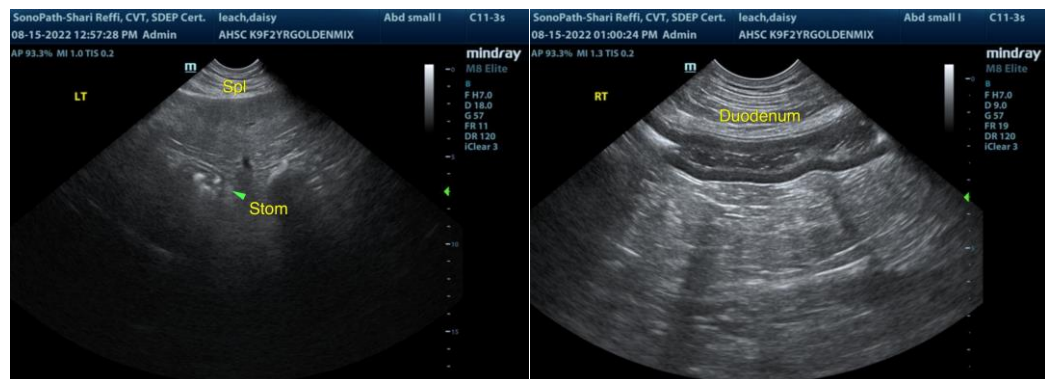
The potential subnormal liver size may be a patient variant. Bile acid testing could be considered for further assessment.

Golden Mix

Potential for duodenitis could be considered if recent inappetence or vomiting.

**SEX**

F



**AGE**

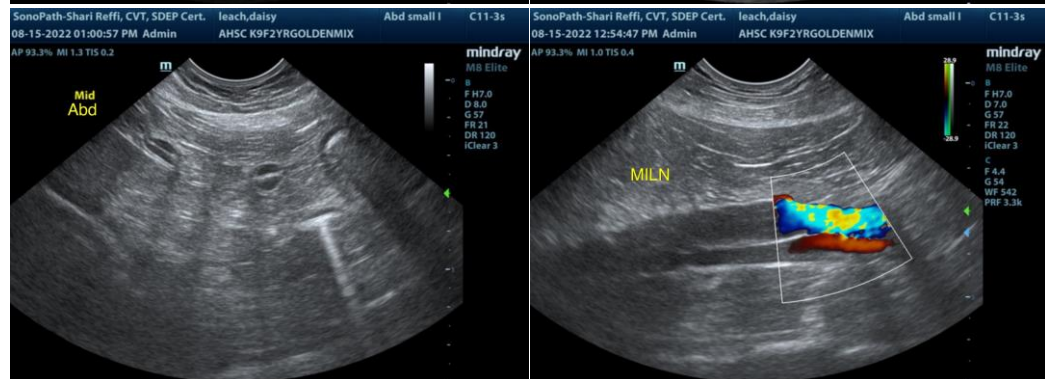
2yr

**WEIGHT**

89lb

**INTERPRETED BY**

R. McKenzie Daniel,  
DVM, DABVP  
(Canine and Feline)

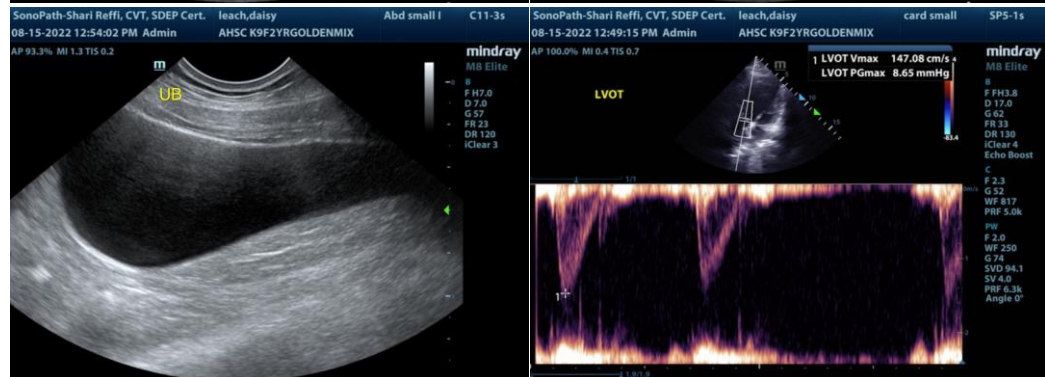


**IMAGING PERFORMED BY**

Shari Reffi CVT

**HOSPITAL NAME**

Animal Hospital of  
Sussex County



**REFERRING VET**

Dr. Spinks

**INVOICE**

11355ag

**DATE**

08/15/2022



**PATIENT**

Daisy Leach

**SPECIES**

Canine

**BREED**

Golden Mix

**SEX**

F

**AGE**

2yr

**WEIGHT**

89lb

**INTERPRETED BY**

R. McKenzie Daniel,  
DVM, DABVP  
(Canine and Feline)

**IMAGING PERFORMED BY**

Shari Reffi CVT

**HOSPITAL NAME**

Animal Hospital of  
Sussex County

**REFERRING VET**

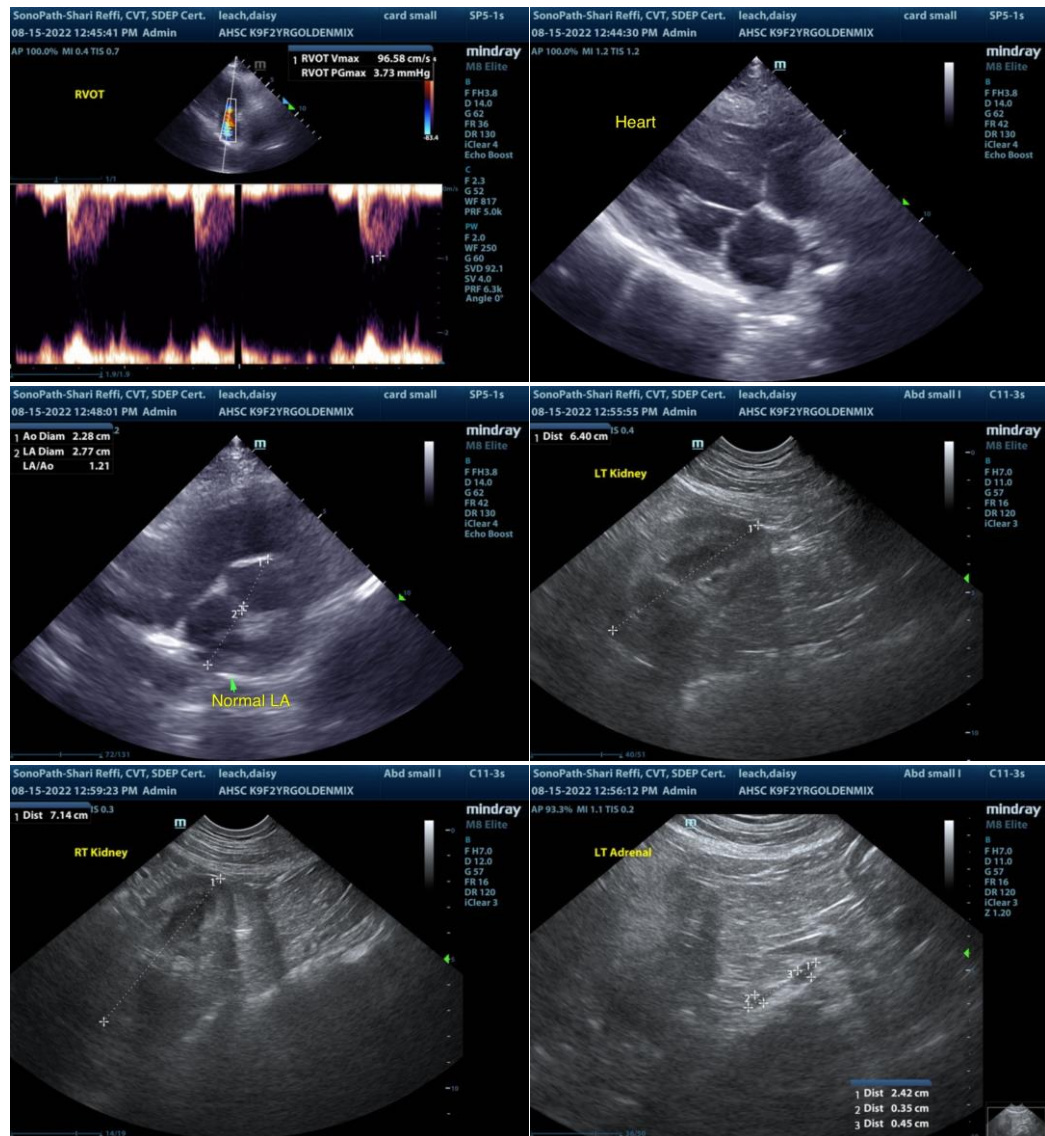
Dr. Spinks

**INVOICE**

11355ag

**DATE**

08/15/2022



The information and recommendations provided are based on the images presented by the referring veterinarian/sonographer. No evaluation can be communicated regarding pathology that was not visible in the image/video clips provided.

Thank you for this referral. If the clinical or image interpretation does not parallel your findings or if I can be of any further assistance please contact me.

R. McKenzie Daniel, DVM, DABVP (Canine / Feline Practice)

info@SonoPath.com