



PATIENT

Prince Herrington

PRESENTING CLINICAL SIGNS

Baseline check due to age. No issues or concerns noted

SPECIES

Canine

ULTRASONOGRAPHIC EXAMINATION OF THE ABDOMEN

Urinary System

The urinary bladder, trigone, cystourethral junction, and visible pelvic urethra exhibited normal thickness and tone. Anechoic urine was present in the lumen with no uroliths or sediment. The ureteral papillae were normal. The ureters were not visible which is normal. No evidence of inflammatory or neoplastic changes were noted.

BREED

Flat Coat Retriever

Normal size and margination were present in the kidneys. A normal 1:3 cortex / medulla ratio and normal corticomedullary definition were maintained. The echogenicity of the cortex was similar to or slightly less than normal liver parenchyma while the medulla echogenicity was hypoechoic to the cortex with no evidence of pelvic dilation. The left kidney measured 7.7 cm in length. The right kidney measured 7.8 cm in length.

SEX

M

AGE

7yr

The area of the aortic trifurcation was free of pathology.

The prostate was enlarged in size with intact, symmetrical capsule contour. The margins of the gland were intact and able to be differentiated from the surrounding tissue. The prostatic parenchyma was mildly echogenic to heteroechoic without parenchymal mineralization. The prostate measured 3.0 cm in diameter.

WEIGHT

78

The visualized testicles were sonographically unremarkable.

Adrenal Glands

The left adrenal gland indistinctly visualize with no overt pathology. The left adrenal gland subjectively measured 0.92 cm width at the caudal pole. The right adrenal gland was not definitely visualized.

INTERPRETED BY

R. McKenzie Daniel,
DVM, DABVP
(Canine and Feline)

Spleen

The spleen exhibited a finely textured and homogenous parenchyma which was hyperechoic to the liver and renal cortical parenchyma. The capsule was smooth and regular without apparent expansion. The splenic vasculature at the hilus was normal in volume with no evidence of congestion or thrombosis. Acute to chronic inflammatory, neoplastic, or benign parenchyma changes were not noted.

IMAGING PERFORMED BY

Hope Brossman

Liver/Gallbladder

The liver was subjectively normal in size, structure, and contour. The liver parenchyma was uniform and hypoechoic to the spleen with a mild coarse echotexture. Normal vascular volume. The hepatic and portal vasculature were normal in appearance without signs of congestion. The gallbladder was non-distended in size with thin walls and primarily anechoic luminal content. The cystic and common bile ducts were normal.

HOSPITAL NAME

Animal Mansion
Veterinary Hospital

REFERRING VET

Shelley Parker DVM

Gastrointestinal

The stomach presented intact wall layering with a normal wall layer ratio. The lumen of the stomach was empty with no signs of ileus, obstruction or foreign material.

INVOICE

14603ag

DATE

08/14/2023



PATIENT

Prince Herrington

The small intestine presented intact wall layering with 1:3 muscularis/mucosa ratio. The lumen of the small intestine was empty with no signs of ileus, obstruction or foreign material.

Normal visible colon wall layers were present with apparent formed feces in lumen.

SPECIES

Canine

Pancreas

The parenchyma of the left limb, body and right limb of the pancreas presented isoechoic to the adjacent omental fat. A normal curvilinear capsule contour of the pancreas was present. The visible pancreatic duct was normal. No signs of active inflammation or neoplastic disease was evident.

BREED

Flat Coat Retriever

Free Abdomen

No omental masses, overt lymphadenopathy or peritoneal effusion was present.

SEX

M

ULTRASONOGRAPHIC FINDINGS

- Sonographically unremarkable abdomen.
- Mild benign prostatic hyperplasia-expected for intact male.

AGE

7yr

INTERPRETATION OF THE FINDINGS & FURTHER RECOMMENDATIONS

WEIGHT

78

Overall, no overt evidence of significant abdominal visceral pathology.

INTERPRETED BY

R. McKenzie Daniel,
DVM, DABVP
(Canine and Feline)

IMAGING PERFORMED BY

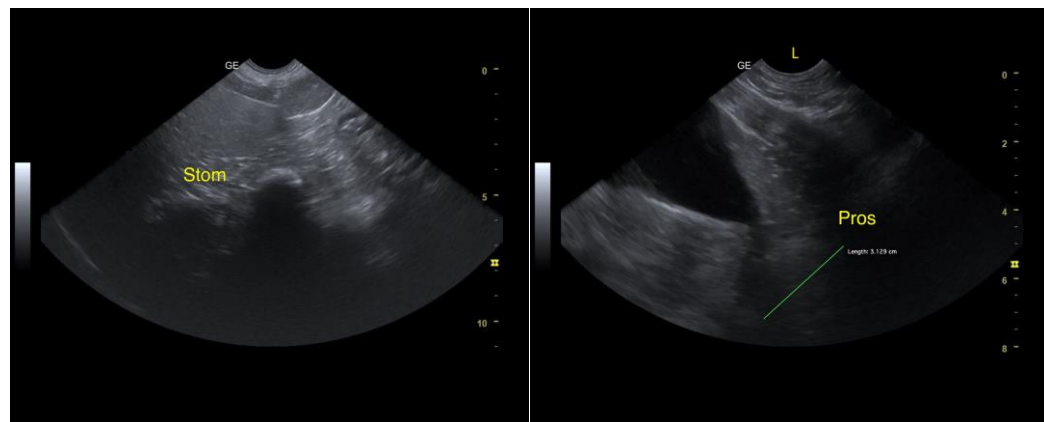
Hope Brossman

HOSPITAL NAME

Animal Mansion
Veterinary Hospital

REFERRING VET

Shelley Parker DVM



INVOICE

14603ag

DATE

08/14/2023



PATIENT

Prince Herrington

SPECIES

Canine

BREED

Flat Coat Retriever

SEX

M

AGE

7yr

WEIGHT

78

INTERPRETED BY

R. McKenzie Daniel,
DVM, DABVP
(Canine and Feline)

IMAGING PERFORMED BY

Hope Brossman

HOSPITAL NAME

Animal Mansion
Veterinary Hospital

REFERRING VET

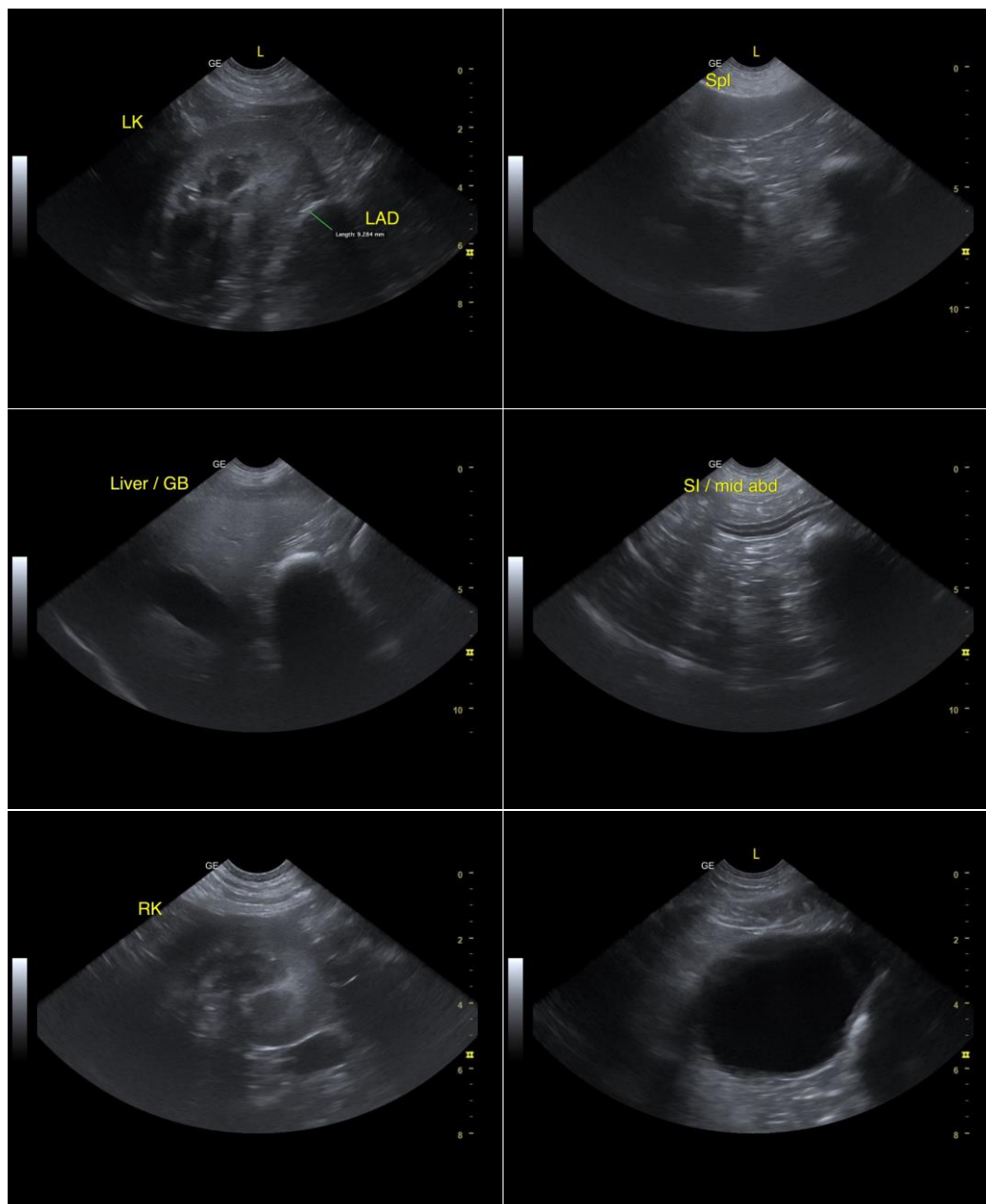
Shelley Parker DVM

INVOICE

14603ag

DATE

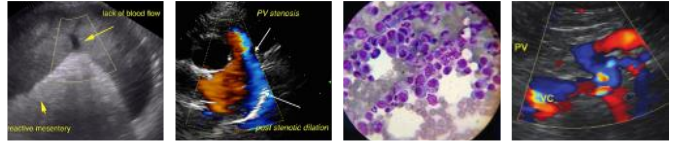
08/14/2023



The information and recommendations provided are based on the images presented by the referring veterinarian/sonographer. No evaluation can be communicated regarding pathology that was not visible in the image/video clips provided.

Thank you for this referral. If the clinical or image interpretation does not parallel your findings or if I can be of any further assistance, please contact me.

R. McKenzie Daniel, DVM, DABVP (Canine/Feline Practice)



PATIENT

info@sonopath.com

Prince Herrington

SPECIES

Canine

BREED

Flat Coat Retriever

SEX

M

AGE

7yr

WEIGHT

78

INTERPRETED BY

R. McKenzie Daniel,
DVM, DABVP
(Canine and Feline)

**IMAGING
PERFORMED BY**

Hope Brossman

HOSPITAL NAME

Animal Mansion
Veterinary Hospital

REFERRING VET

Shelley Parker DVM

INVOICE

14603ag

DATE

08/14/2023