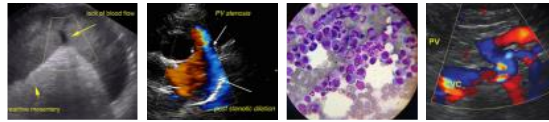




PATIENT	PRESENTING CLINICAL SIGNS
Abena Lucca	Chronic vomiting; Radiographes were not concerning for GI FB. P ate that morning - There is debris within the stomach but looks likely to be normal food debris. Cannot R/O that it isn't something like cottony material, couch stuffing, etc but discussed P behavior with O and this is not something that is expected based on history. Sending out resting cortisol and then may rec US and hypoallergenic dietary trial if normal.
SPECIES	
Canine	
BREED	ULTRASONOGRAPHIC EXAMINATION OF THE ABDOMEN
Scottish Terrier Mix	Urinary System The urinary bladder, trigone, cystourethral junction, and visible pelvic urethra exhibited normal thickness and tone. Anechoic urine was present in the lumen with no uroliths or sediment. The ureteral papillae were normal. The ureters were not visible which is normal. No evidence of inflammatory or neoplastic changes were noted.
SEX	
FS	
AGE	
3yr	Normal size and margination were present in the kidneys. A normal 1:3 cortex / medulla ratio and normal corticomedullary definition were maintained. The echogenicity of the cortex was similar to or slightly less than normal liver parenchyma while the medulla echogenicity was hypoechoic to the cortex with no evidence of pelvic dilation. The left kidney measured 5.0 cm in length. The right kidney measured 5.9 cm in length.
WEIGHT	
38lb	The area of the aortic trifurcation was free of pathology.
INTERPRETED BY	Adrenal Glands
R. McKenzie Daniel, DVM, DABVP (Canine and Feline)	The left adrenal gland was uniform in size and contour with a uniformly hypoechoic parenchyma. The left adrenal gland measured 0.57 cm width at the caudal pole and 2.6 cm length. The right adrenal gland was uniform in size and contour with a uniformly hypoechoic parenchyma. The right adrenal gland measured 0.45 cm width at the caudal pole and 2.6 cm length.
IMAGING PERFORMED BY	Spleen
Sara Hansen	The spleen exhibited a finely textured and homogenous parenchyma which was hyperechoic to the liver and renal cortical parenchyma. The capsule was smooth and regular without apparent expansion. The splenic vasculature at the hilus was normal in volume with no evidence of congestion or thrombosis. Acute to chronic inflammatory, neoplastic, or benign parenchyma changes were not noted.
HOSPITAL NAME	Liver/Gallbladder
The Ark Veterinary Clinic	The liver was subjectively normal in size, structure, and contour. The liver parenchyma was uniform and hypoechoic to the spleen with a mild coarse echotexture. The hepatic and portal vasculature were normal in appearance without signs of congestion. The gallbladder was non-distended in size with thin walls and primarily anechoic luminal content. The cystic and common bile ducts were normal.
REFERRING VET	Gastrointestinal
Dr Sangl	The stomach presented intact wall layering with a normal wall layer ratio. The lumen of the stomach contained minor non-shadowing ingesta/chyme with no signs of ileus, obstruction or foreign material.
INVOICE	
14609ag	
DATE	
08/14/2023	



PATIENT

Abena Lucca

The small intestine presented intact wall layering with 1:3 muscularis/mucosa ratio. The lumen of the small intestine was empty with no signs of ileus, obstruction or foreign material.

Normal visible colon wall layers were present with apparent formed feces in lumen.

SPECIES

Canine

Pancreas

The parenchyma of the left limb, body and right limb of the pancreas presented isoechoic to the adjacent omental fat. A normal curvilinear capsule contour of the pancreas was present. The visible pancreatic duct was normal. No signs of active inflammation or neoplastic disease was evident.

BREED

Scottish Terrier Mix

Free Abdomen

SEX

FS

No omental masses, overt lymphadenopathy or peritoneal effusion was present.

AGE

3yr

ULTRASONOGRAPHIC FINDINGS

- Sonographically normal GI tract with minor gastric ingesta/chyme.
- Normal pancreas.

WEIGHT

38lb

INTERPRETATION OF THE FINDINGS & FURTHER RECOMMENDATIONS

INTERPRETED BY

R. McKenzie Daniel,
DVM, DABVP
(Canine and Feline)

Overall, no overt evidence of significant abdominal visceral specifically GI or pancreatic pathology as a definitive cause of the patient's chronic vomiting. The presence of minor gastric ingesta is nonspecific and likely indicates post-prandial presentation. Correlation with most recent meal ingestion is recommended. If documented NPO prior to the ultrasound, the presence of gastric ingesta may indicate some degree of gastric hypomotility or metabolic stasis. The sonographic presentation of the ingesta was most consistent with food, without evidence of foreign material.

IMAGING PERFORMED BY

Sara Hansen

Dietary indiscretion / food hypersensitivity, occult parasitism, structurally insignificant inflammatory gastroenteropathy or low grade to chronic pancreatitis both of which may appear sonographically normal are all potentials. Assessment for evidence of cranial abdominal/subxiphoid discomfort on palpation which may allude to low grade pancreatitis which may appear sonographically normal is recommended.

HOSPITAL NAME

The Ark Veterinary
Clinic

Empirically gastric protectant protocol i.e., Omeprazole 1 mg/kg PO SID with canned novel protein or hydrolyzed diet trial with avoidance of dry food over the next 3 weeks along and assessment of clinical response is recommended.

REFERRING VET

Dr Sangl

INVOICE

14609ag

DATE

08/14/2023



PATIENT

Abena Lucca

SPECIES

Canine

BREED

Scottish Terrier Mix

SEX

FS

AGE

3yr

WEIGHT

38lb

INTERPRETED BY

R. McKenzie Daniel,
DVM, DABVP
(Canine and Feline)

IMAGING PERFORMED BY

Sara Hansen

HOSPITAL NAME

The Ark Veterinary
Clinic

REFERRING VET

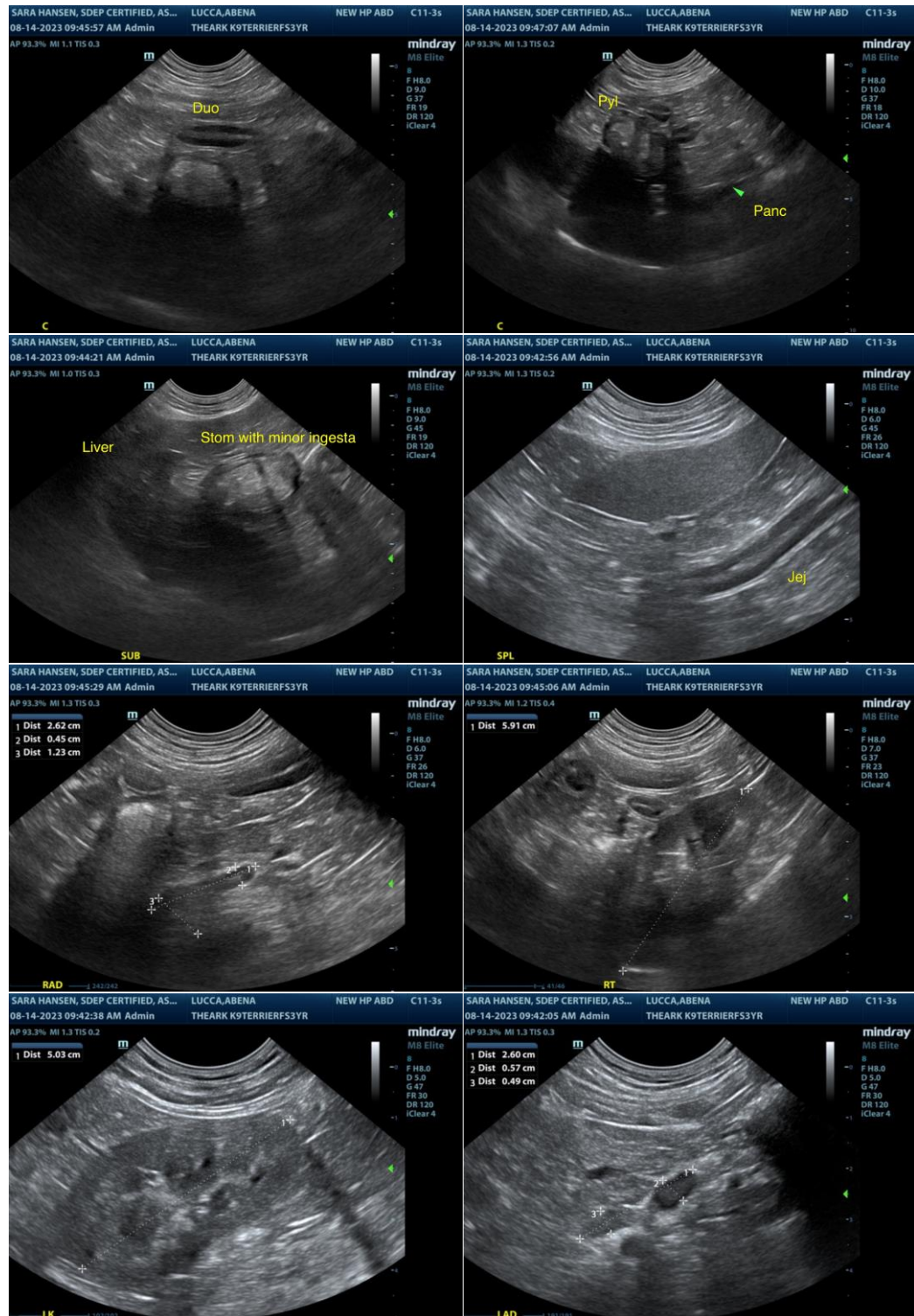
Dr Sangl

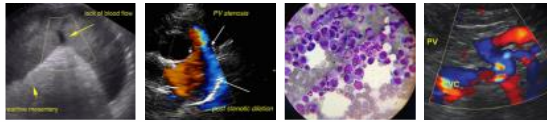
INVOICE

14609ag

DATE

08/14/2023





PATIENT

Abena Lucca

SPECIES

Canine

BREED

Scottish Terrier Mix

SEX

FS

AGE

3yr

WEIGHT

38lb

INTERPRETED BY

R. McKenzie Daniel,
DVM, DABVP
(Canine and Feline)

**IMAGING
PERFORMED BY**

Sara Hansen

HOSPITAL NAME

The Ark Veterinary
Clinic

REFERRING VET

Dr Sangl

INVOICE

14609ag

DATE

08/14/2023

The information and recommendations provided are based on the images presented by the referring veterinarian/sonographer. No evaluation can be communicated regarding pathology that was not visible in the image/video clips provided.

Thank you for this referral. If the clinical or image interpretation does not parallel your findings or if I can be of any further assistance please contact me.

R. McKenzie Daniel, DVM, DABVP (Canine / Feline Practice)

info@SonoPath.com