



**PATIENT**

Lexie Ivey

**SPECIES**

Canine

**BREED**

Mini Schnauzer

**SEX**

FS

**AGE**

3yr

**WEIGHT**

10.4kg

**INTERPRETED BY**

R. McKenzie Daniel,  
DVM, DABVP  
(Canine and Feline)

**IMAGING PERFORMED BY**

Erin Wicks

**HOSPITAL NAME**

Shores Veterinary  
Emergency Center

**REFERRING VET**

Dr. Slenbaker

**INVOICE**

11339ag

**DATE**

08/14/2022

**PRESENTING CLINICAL SIGNS**

Presented at our hospital for transfer from rDVM for pancreatitis

K9 ADR since Tuesday, V+ and NE, lethargic

Previous Health Concerns: None

Current Medications: None

Abnormal PE/Chem/CBC/UA Results

Abdominal: very painful/reactive cranial to mid abdominal palpation, no obvious mass noted

rDVM Radiology report: reduced right cranial abdominal detail, no evidence of foreign material or mechanical obstruction

rDVM bloodwork: RBC 8.93 H, Hgb 24.7 H, MCV 60.5 H, MCH 27.7 H, MCHC 45.7 H, PMN 0.74 L, Monocytes 3.96 H, platelets 710 H, Potassium 3.1 L, Chloride 103 L, Total protein 8.5 H, Globulin 4.6 H, ALP 312 H, Cholesterol 410 H, Amylase >2500 H, Lipase 5106 H

EPOC: Na 136 L, K+ 3.2 L, Cl 101 L, Ca 1.13 L, Lactate 5.79 H, Creat 1.6 H, HCT 56% H

USG at intake: 1.042

**ULTRASONOGRAPHIC EXAMINATION OF THE ABDOMEN**

**Urinary System**

The urinary bladder, trigone, cystourethral junction, and visible pelvic urethra to a depth of 3 cm exhibited normal thickness and tone. Anechoic urine was present in the lumen with no uroliths or sediment. The ureteral papillae were normal. The ureters were not visible which is normal. No evidence of inflammatory or neoplastic changes were noted.

Normal size and margination were present in the kidneys. A normal 1:3 cortex / medulla ratio and normal corticomedullary definition were maintained. The echogenicity of the cortex was similar to or slightly less than normal liver parenchyma while the medulla echogenicity was hypoechoic to the cortex with no evidence of pelvic dilation. The left kidney measured 4.8 cm in length. The right kidney measured 5.6 cm in length.

The area of the aortic trifurcation was free of pathology.

**Adrenal Glands**

The left adrenal gland was uniform in size and contour with a uniformly hypoechoic parenchyma. The left adrenal gland measured 0.56 cm width at the caudal pole and 0.56 cm width at the cranial pole. The right adrenal gland was not definitively visualized owing to perirenal omental artefact.

**Spleen**

The spleen exhibited a finely textured and homogenous parenchyma which was hyperechoic to the liver and renal cortical parenchyma. The capsule was smooth and regular without apparent expansion. The splenic vasculature at the hilus was normal in volume with no evidence of congestion or thrombosis. Acute to chronic inflammatory, neoplastic, or benign parenchyma changes were not noted.

**Liver**



**PATIENT**

Lexie Ivey

The liver presented enlarged in size. The parenchyma of the liver was subjectively normal in echogenicity compared to the spleen and renal cortices. The liver parenchyma was uniform with a mildly coarse echotexture. The capsule of the liver was symmetrically rounded to mildly swollen in margination. The hepatic and portal vasculature were normal in appearance without signs of congestion.

**SPECIES**

Canine

The gallbladder was non-distended in size with primarily anechoic luminal content. The cystic and common bile ducts were normal.

**Gastrointestinal**

**BREED**

Mini Schnauzer

The stomach presented intact yet prominent wall layering with a normal wall layer ratio. The lumen of the stomach was moderate to significantly distended with retained anechoic fluid with no signs of ileus, obstruction or foreign material.

**SEX**

FS

The duodenum presented intact yet prominent wall layering with 1:3 muscularis/mucosa ratio. The lumen of the small intestine was empty with no signs of ileus, obstruction or foreign material.

Normal visible colon wall layers were present with apparent formed feces in lumen.

**AGE**

3yr

**Pancreas**

Diffuse enlargement of the pancreas with ill-defined, hypoechoic to heterogeneous parenchyma and asymmetrical contour was present. Peripancreatic to generalized mid to cranial abdominal hyperechoic mesentery was present, indicative of reactive change, adhesions, focal peritonitis, or saponification. Mild localized free fluid was present around the abnormal pancreas.

**WEIGHT**

10.4kg

**Free Abdomen**

No overt lymphadenopathy was present.

**INTERPRETED BY**

R. McKenzie Daniel,  
DVM, DABVP  
(Canine and Feline)

**ULTRASONOGRAPHIC FINDINGS**

- Moderate to severe, potentiality necrotizing pancreatitis with associated peritonitis
- Gastroduodenitis with gastric hypomotility
- Reactive to vacuolar hepatopathy pattern

**IMAGING PERFORMED BY**

Erin Wicks

**INTERPRETATION OF THE FINDINGS & FURTHER RECOMMENDATIONS**

Aggressive therapy for moderate to severe pancreatitis and associated peritonitis with GI support is recommended. Minor potential for pancreatic neoplasia which may present in similar sonographic manner is possible yet thought less likely. Guarded to very guarded prognosis. Sonographic reassessment of the pancreas in 3-5 days may be considered pending clinical response to therapy.

**HOSPITAL NAME**

Shores Veterinary  
Emergency Center

**REFERRING VET**

Dr. Slenbaker

**INVOICE**

11339ag

**DATE**

08/14/2022



**PATIENT**

Lexie Ivey

**SPECIES**

Canine

**BREED**

Mini Schnauzer

**SEX**

FS

**AGE**

3yr

**WEIGHT**

10.4kg

**INTERPRETED BY**

R. McKenzie Daniel,  
DVM, DABVP  
(Canine and Feline)

**IMAGING PERFORMED BY**

Erin Wicks

**HOSPITAL NAME**

Shores Veterinary  
Emergency Center

**REFERRING VET**

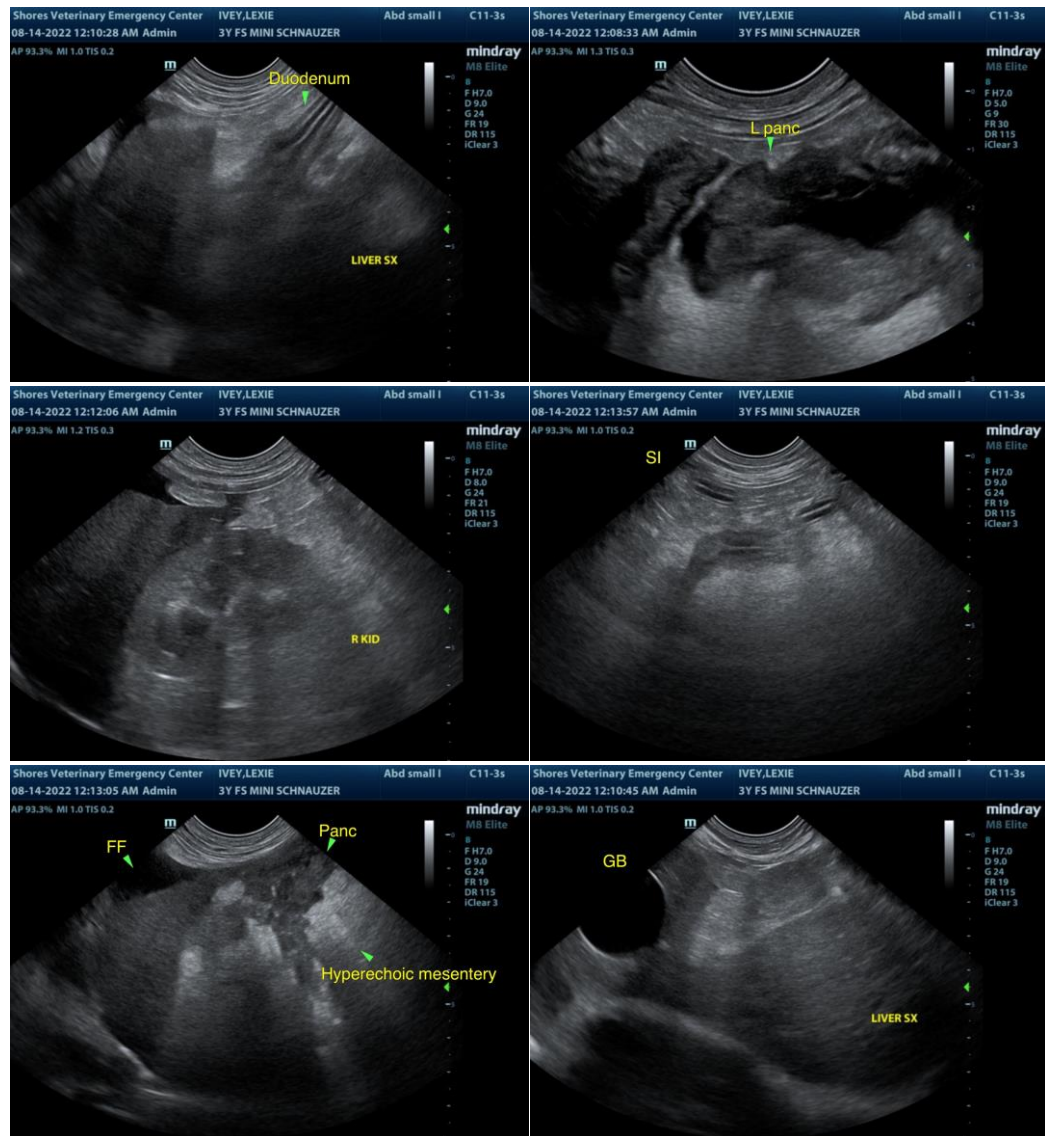
Dr. Slenbaker

**INVOICE**

11339ag

**DATE**

08/14/2022





**PATIENT**

Lexie Ivey

**SPECIES**

Canine

**BREED**

Mini Schnauzer

**SEX**

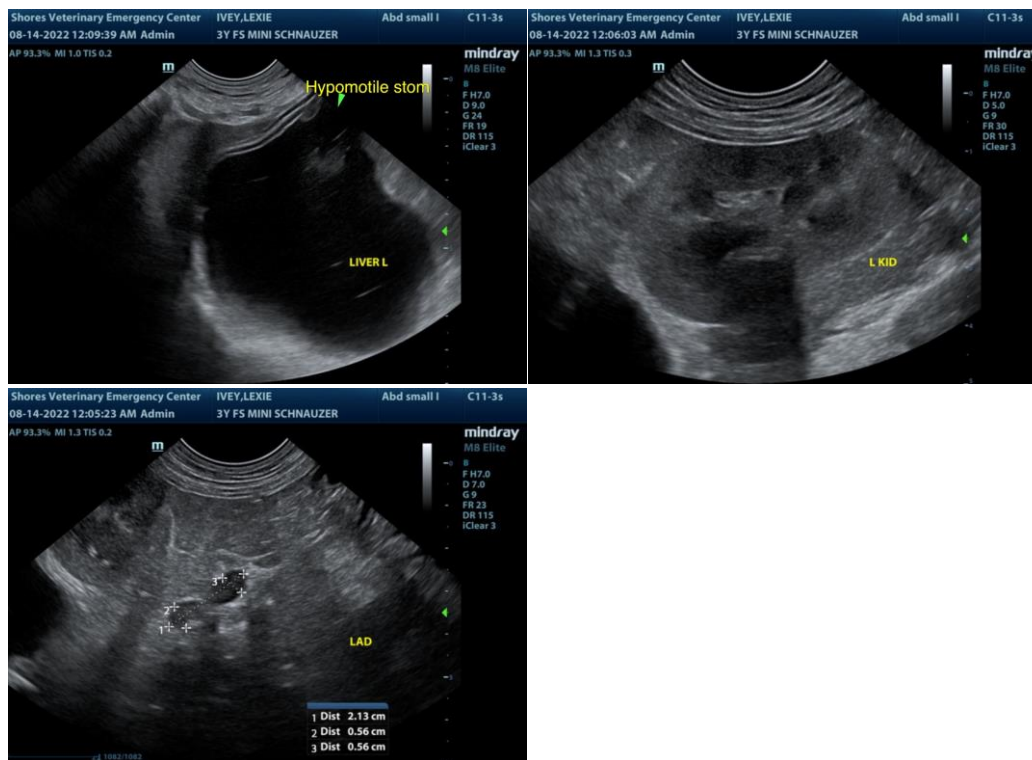
FS

**AGE**

3yr

**WEIGHT**

10.4kg



**INTERPRETED BY**

R. McKenzie Daniel,  
DVM, DABVP  
(Canine and Feline)

**IMAGING PERFORMED BY**

Erin Wicks

**HOSPITAL NAME**

Shores Veterinary  
Emergency Center

**REFERRING VET**

Dr. Slenbaker

**INVOICE**

11339ag

**DATE**

08/14/2022

The information and recommendations provided are based on the images presented by the referring veterinarian/sonographer. No evaluation can be communicated regarding pathology that was not visible in the image/video clips provided.

Thank you for this referral. If the clinical or image interpretation does not parallel your findings or if I can be of any further assistance please contact me.

R. McKenzie Daniel, DVM, DABVP (Canine / Feline Practice)

info@SonoPath.com