



PATIENT	PRESENTING CLINICAL SIGNS
Daisy Schmidt	Hospitalized for HGE. Thursday 8/10 went to groomer, Since then no interest in food, vomiting all day 8/11 with diarrhea. Diarrhea progressed to bloody diarrhea. Hx of chewing up toys. P eats human food as a normal diet Regurgitated twice overnight 8/12-13, radiographs did not show obvious obstruction.
SPECIES	
Canine	Abnormal PE/Chem/CBC/UA Results: CBC - Hemoconcentration HCT 54%, bands noted, rest wnl Chem10 - Elevated ALT 167, rest wnl CPL - < 50 (normal/negative) EPOC vbg- Hyperglycemia 137,
BREED	Hemoconcentration HCT 61%, rest wnl
Poodle x	ULTRASONOGRAPHIC EXAMINATION OF THE ABDOMEN
SEX	Urinary System
Spayed Female	The urinary bladder, trigone, cystourethral junction, and visible pelvic urethra to a depth of - cm exhibited normal thickness and tone. Primarily anechoic urine was present in the lumen. Mild non-dependent particulate sediment was present without evidence of calculus formation. The ureteral papillae were normal. The ureters were not visible which is normal. No evidence of inflammatory or neoplastic mural changes were noted.
AGE	
6 Years	
WEIGHT	Normal size and margination were present in the kidneys. A normal 1:3 cortex / medulla ratio and normal corticomedullary definition were maintained. The echogenicity of the cortex was similar to or slightly less than normal liver parenchyma while the medulla echogenicity was hypoechoic to the cortex with no evidence of pelvic dilation. The left kidney measured 3.8 cm. The right kidney measured 4.0 cm.
4.7 kg	
INTERPRETED BY	Adrenal Glands
R. McKenzie Daniel, DVM, DABVP (Canine and Feline)	The adrenal glands were overtly normal in size, position, and shape. The left adrenal gland measured 0.41 cm at the cranial pole and 0.52 cm at the caudal pole. The right adrenal gland measured 0.47 cm at the cranial pole and 0.45 cm at the caudal pole.
IMAGING PERFORMED BY	Spleen
Dr. Anna Wepprich	The spleen exhibited a finely textured and homogenous parenchyma which was hyperechoic to the liver and renal cortical parenchyma. The capsule was smooth and regular without apparent expansion. The splenic vasculature at the hilus was normal in volume with no evidence of congestion or thrombosis. Acute to chronic inflammatory, neoplastic, or benign parenchyma changes were not noted.
HOSPITAL NAME	Liver
Wilvet Salem	The liver was subjectively normal in size, structure, and contour. The liver parenchyma was uniform and hypoechoic to the spleen with a mild coarse echotexture. The hepatic and portal vasculature were normal in appearance without signs of congestion. The gallbladder was non-distended in size with thin walls and primarily anechoic luminal content. The cystic and common bile ducts were normal.
REFERRING VET	Gastrointestinal
Dr. Anna Wepprich	The stomach presented wall thickening secondary to echogenic mucosa hypertrophy. Intact yet mildly prominent wall layering noted. The stomach contained a mild amount of retained anechoic fluid. No overt evidence of shadowing ingesta or foreign material. No evidence of mechanical pyloric outflow obstruction.
INVOICE	
44627	
DATE	
8/13/23	



PATIENT

Daisy Schmidt

The small intestine presented generalized intact wall layering with minor segmental non-obstructive jejunal ileus pattern. Subjective propensity for mildly prominent, hyperechoic intestinal submucosal layer.

SPECIES

Canine

The colon walls presented intact yet mildly prominent wall layering with mild thickened to echogenic submucosa. Generalized soft to nonformed fecal matter noted throughout the colon.

BREED

Poodle x

Pancreas

The parenchyma of the left limb, body and right limb of the pancreas presented isoechoic to the adjacent omental fat. A normal curvilinear capsule contour of the pancreas was present. The visible pancreatic duct was normal. No signs of active inflammation or neoplastic disease was evident.

SEX

Spayed Female

Intermittent, mildly prominent to enlarged mesenteric nodes were present. The lymph nodes were essentially isoechoic to adjacent omentum without evidence of peripheral inflammation and maintaining a normal width: length ratio (<0.5).

AGE

6 Years

Free Abdomen

No evidence of peritoneal effusion.

WEIGHT

4.7 kg

ULTRASONOGRAPHIC FINDINGS

- Acute gastroenterocolitis
- Intermittent mild benign / reactive mesenteric lymph nodes
- Normal liver - consistent with low grade benign hepatopathy

INTERPRETED BY

R. McKenzie Daniel,
DVM, DABVP
(Canine and Feline)

INTERPRETATION OF THE FINDINGS & FURTHER RECOMMENDATIONS

Dietary indiscretion / food intolerance, enterotoxin, infectious disease, emerging inflammatory bowel, occult parasitism, occult Addisons Disease, infiltrative neoplasia (unlikely) possible. No evidence of obstructive pattern or foreign body. Empirical therapy for acute hemorrhagic diarrhea syndrome should be beneficial. A GI panel (PLI/TLI/B12/folate) and resting cortisol level may be considered. Recheck sonogram is suggested if persistent / progressive gastrointestinal signs non responsive to supportive care.

IMAGING PERFORMED BY

Dr. Anna Wepprich

HOSPITAL NAME

Wilvet Salem

REFERRING VET

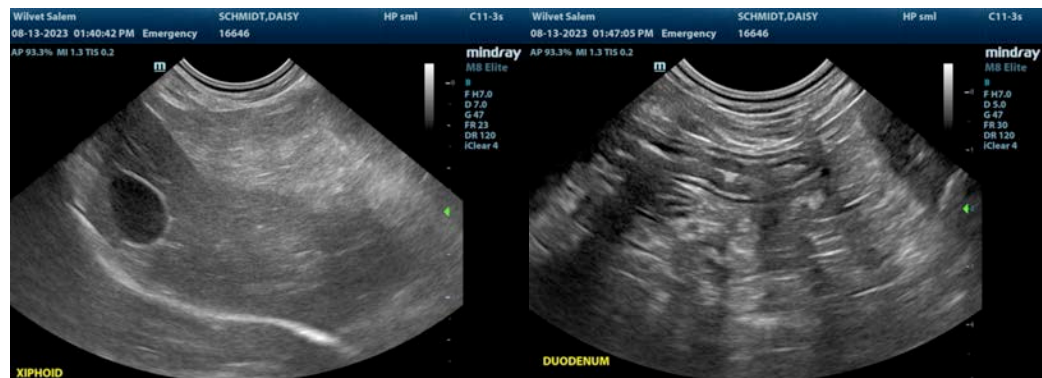Dr. Anna Wepprich

INVOICE

44627

DATE

8/13/23





PATIENT

Daisy Schmidt

SPECIES

Canine

BREED

Poodle x

SEX

Spayed Female

AGE

6 Years

WEIGHT

4.7 kg

INTERPRETED BY

R. McKenzie Daniel,
DVM, DABVP
(Canine and Feline)

IMAGING PERFORMED BY

Dr. Anna Wepprich

HOSPITAL NAME

Wilvet Salem

REFERRING VET

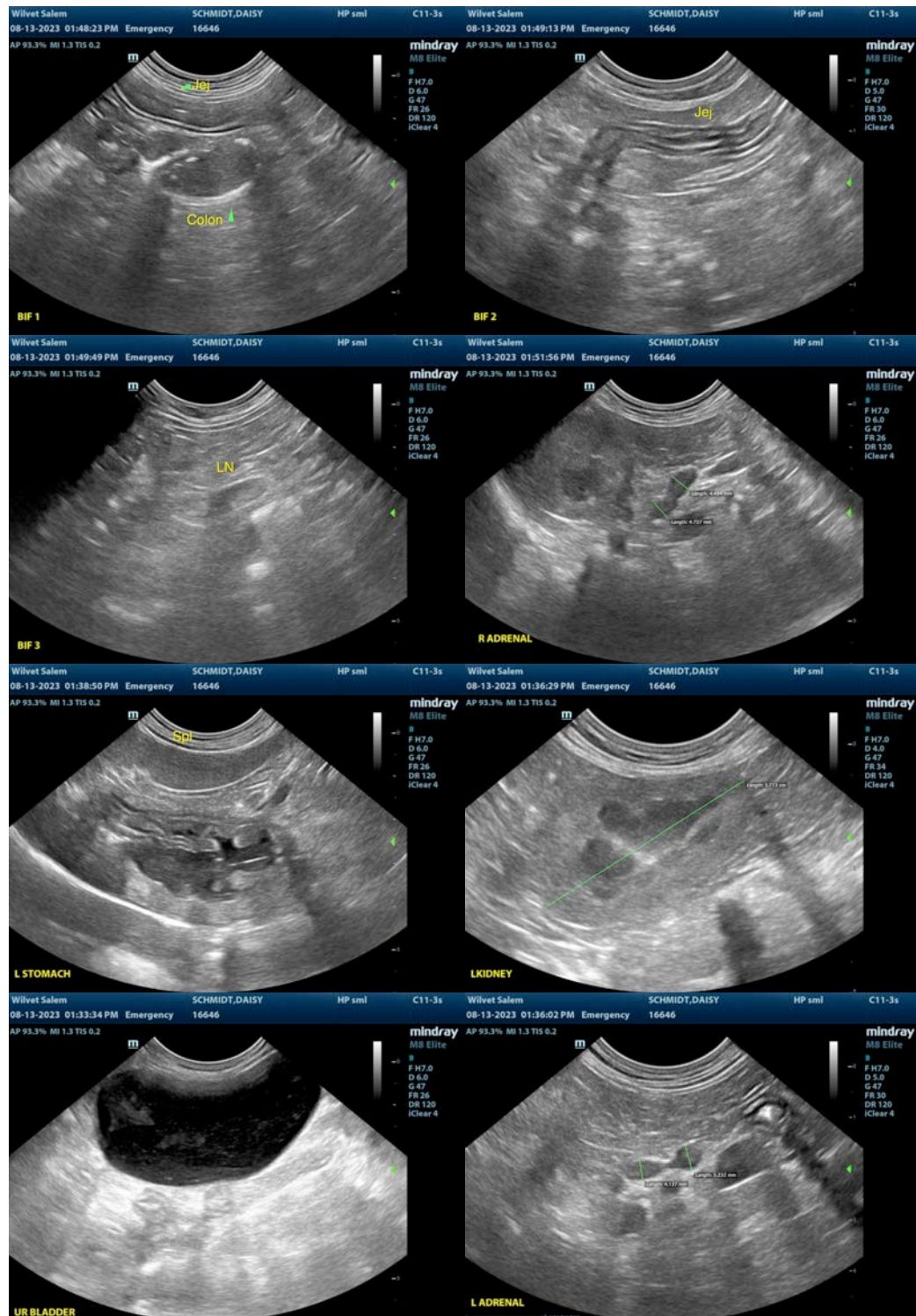
Dr. Anna Wepprich

INVOICE

44627

DATE

8/13/23





PATIENT

Daisy Schmidt

SPECIES

Canine

BREED

Poodle x

SEX

Spayed Female

AGE

6 Years

WEIGHT

4.7 kg

INTERPRETED BY

R. McKenzie Daniel,
DVM, DABVP
(Canine and Feline)

**IMAGING
PERFORMED BY**

Dr. Anna Wepprich

HOSPITAL NAME

Wilvet Salem

REFERRING VET

Dr. Anna Wepprich

INVOICE

44627

DATE

8/13/23

The information and recommendations provided are based on the images presented by the referring veterinarian/sonographer. No evaluation can be communicated regarding pathology that was not visible in the image/video clips provided.

Thank you for this referral. If the clinical or image interpretation does not parallel your findings or if I can be of any further assistance please contact me.

R. McKenzie Daniel, DVM, DABVP (Canine / Feline Practice)

info@SonoPath.com