



**PATIENT**

Gizmo Firth

**SPECIES**

Canine

**BREED**

Pomeranian X

**SEX**

Neutered Male

**AGE**

15.5 Years

**WEIGHT**

9

**INTERPRETED BY**

R. McKenzie Daniel,  
DVM, DABVP  
(Canine and Feline)

**IMAGING PERFORMED BY**

Dr. Robyn Lantz

**HOSPITAL NAME**

Eastgate Vet Clinic

**REFERRING VET**

Dr. Robyn Lantz

**INVOICE**

24677

**DATE**

8/13/21

**PRESENTING CLINICAL SIGNS**

History of weight loss and not eating for several days; was on RC GI Low Fat diet. In the past - intermittent uroliths, intermittent choleliths seen on previous ultrasound, pancreatitis, biliary sludge, gastroenteritis, dietary indiscretion, ivdd, dental disease, allergic dermatitis.

Abnormal PE/Chem/CBC/UA Results: giant platelets, platelet clumping, thrombocytopenia ( $72 \times 10^3/\mu\text{L}$ ); previously elevated liver values, but wnl from yesterday's lab sample. Previously elevated pancreatitis test (spec cPL Idexx), but wnl from yesterday's lab sample to Antech precision PSL. 3.9g/dL globulins; BUN 35mg/dL; rest of senior lab work wnl. Fecal float nps; u/a sample pending.

**ULTRASONOGRAPHIC EXAMINATION OF THE ABDOMEN**

**Urinary System**

The urinary bladder exhibited normal thickness and tone. Mild asymmetrical luminal surface to micropolypliod changes were present likely associated with age related mural changes. Anechoic urine was present in the lumen with no uroliths or sediment. The ureteral papillae were normal. The ureters were not visible which is normal. No evidence of inflammatory or neoplastic changes were noted.

The residual prostate was normal in size and contour with mild non-homogeneous parenchyma, likely indicative of minor age related residual prostate changes. The residual prostate measured 0.76 cm diameter.

The area of the aortic trifurcation was free of pathology.

Normal size and margination were present in the kidneys. A normal 1:3 cortex / medulla ratio was maintained. The medulla and cortices were uniform in texture with some increased echogenicity and loss of corticomedullary symmetry and definition expected for the age of the patient. No evidence of pelvic dilation was present. Non-obstructive dystrophic medullary mineralization was present along with small cortical cysts in both kidneys. The left kidney measured 3.8 cm. The right kidney measured 4.0 cm.

**Adrenal Glands**

The left adrenal gland was mildly enlarged in size. Mild parenchyma heterogeneity and mild capsule asymmetry was present without suspicion for overt neoplasia. The left adrenal gland measured 2.0 cm length x 0.9 cm at the caudal pole. The right adrenal gland was not overtly visualized.

**Spleen**

The spleen exhibited primarily finely textured and homogenous parenchyma which was hyperechoic to the liver and renal cortical parenchyma. Multifocal, well-defined, symmetrical, echogenic nodules were present primarily in the medial parenchyma adjacent to the hilus. Example of splenic nodule measured 1.2 cm diameter. The capsule was smooth and regular without apparent expansion. The splenic vasculature at the hilus was normal in volume with no evidence of congestion or thrombosis. Acute to chronic inflammatory or neoplastic changes were not noted. The echogenic nodules tend to trend benign and are most consistent with benign hyperplasia or myelolipomas.

**Liver**

The liver exhibited mild to moderate generalized enlargement. The liver parenchyma was mildly nonuniform and hypoechoic to the spleen with a moderate coarse echotexture and subjective mild to benign parenchymal remodeling. The hepatic and portal vasculature were normal in appearance without signs of congestion. The gallbladder was non distended in size with moderate, echogenic, non-dependent, non-organized debris. No evidence of associated peripheral inflammation. The common bile duct was normal.



**PATIENT**

Gizmo Firth

**Gastrointestinal**

The stomach presented intact wall layering with a normal wall layer ratio. The lumen of the stomach was empty with no signs of ileus, obstruction or foreign material. Gastric body wall measured 0.30 cm.

**SPECIES**

Canine

The small intestine presented intact wall layering with subjective propensity for mild generalized prominent mucosal layer and intermittent duodenojejunal mucosal speckling. Duodenum wall measured 0.42 cm. Jejunum wall measured 0.44 cm.

**BREED**

Pomeranian X

Normal visible colon wall layers were present with apparent formed feces in lumen.

**SEX**

Neutered Male

**Pancreas**

The parenchyma of the pancreas was heterogeneous to mildly echogenic parenchyma. The capsule of the pancreas was mildly asymmetrical in contour without evidence of peripancreatic inflammation. These changes may suggest chronic inflammation, fibrosis, or saponification if previous history of pancreatitis. No overt signs of pancreatic neoplasia.

**AGE**

15.5 Years

**Free Abdomen**

No overt lymphadenopathy. A small pocket of scant, non-specific free fluid was noted in the caudal abdomen between the colon and urinary bladder. Subtle subjective generalized primarily peri intestinal reactive mesentery was noted.

**WEIGHT**

9

**ULTRASONOGRAPHIC FINDINGS**

- Micropolypoid urinary bladder changes
- Bilateral moderate chronic degenerative kidneys with cortical cysts and non-obstructive medullary dystrophic mineralization
- Mild left adrenomegaly
- Benign splenic nodule – consistent with myelolipomas, nodular hyperplasia, or potential emerging mineralization.
- Hepatomegaly with parenchymal remodeling – subjectively benign.
- Moderate gallbladder debris (non-mucocele)
- Heterogeneous to echogenic pancreas – age related or patient variant, parenchymal remodeling owing to previous inflammation, or low-grade chronic inflammation possible.
- Chronic enteropathy – chronic gastroenteritis or inflammatory bowel suspected.

**INTERPRETED BY**

R. McKenzie Daniel,  
DVM, DABVP  
(Canine and Feline)

**IMAGING PERFORMED BY**

Dr. Robyn Lantz

**HOSPITAL NAME**

Eastgate Vet Clinic

**REFERRING VET**

Dr. Robyn Lantz

**INTERPRETATION OF THE FINDINGS & FURTHER RECOMMENDATIONS**

Further renal staging including pending urinalysis +/- culture and sensitivity and baseline UPC may be considered. The clinical significance of the mild left adrenomegaly is unclear given the patient's clinical signs. This may indicate benign hyperplasia or adenomatous change without overt evidence of neoplastic criteria.

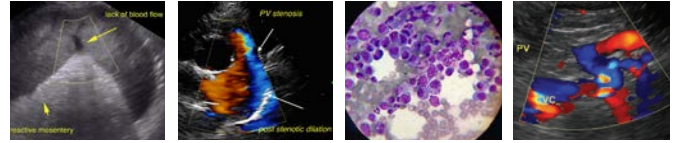
**INVOICE**

24677

Adrenal workup including LDDST may be considered if clinically indicated. Sonographic monitoring of the left adrenal gland would be appropriate. A GI panel to include PLI/TLI/Cobalamin/Folate as well as three view chest radiographs and neurological examination are recommended to assess for or rule out occult disease which may cause weight loss. Empirically, continued gastrointestinal support and therapy for gastroenteritis/chronic inflammatory bowel would be appropriate.

**DATE**

8/13/21



**PATIENT**

Gizmo Firth

**SPECIES**

Canine

**BREED**

Pomeranian X

**SEX**

Neutered Male

**AGE**

15.5 Years

**WEIGHT**

9

**INTERPRETED BY**

R. McKenzie Daniel,  
DVM, DABVP  
(Canine and Feline)

**IMAGING PERFORMED BY**

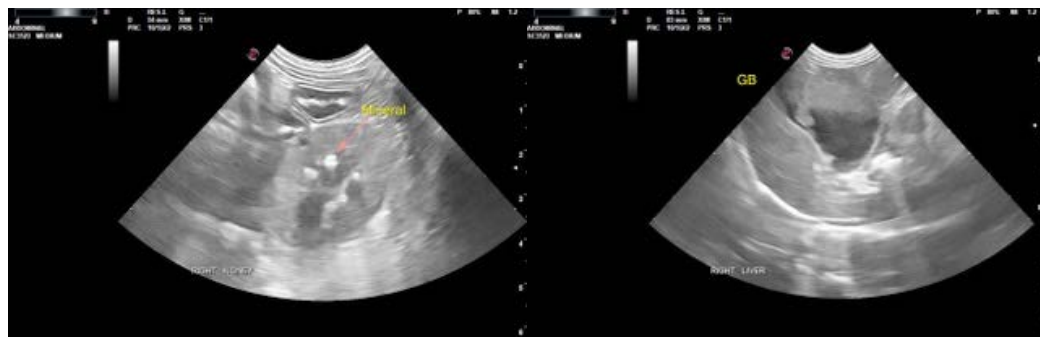
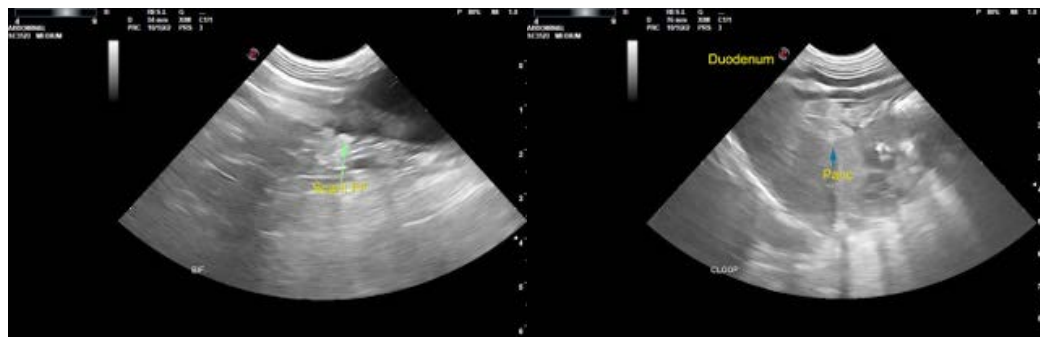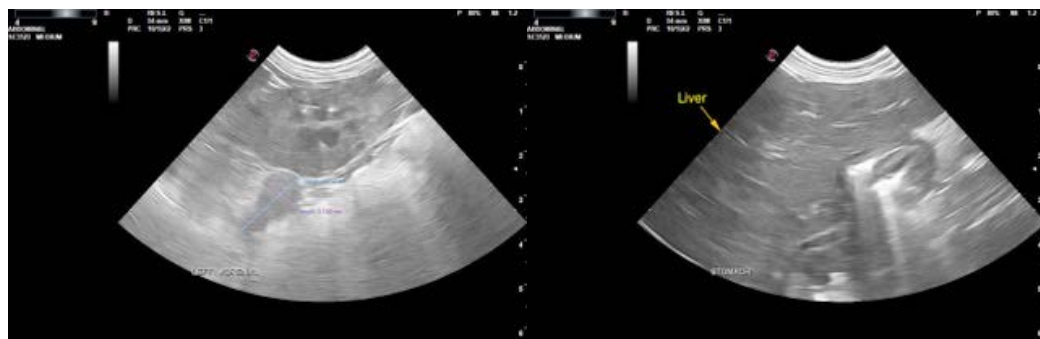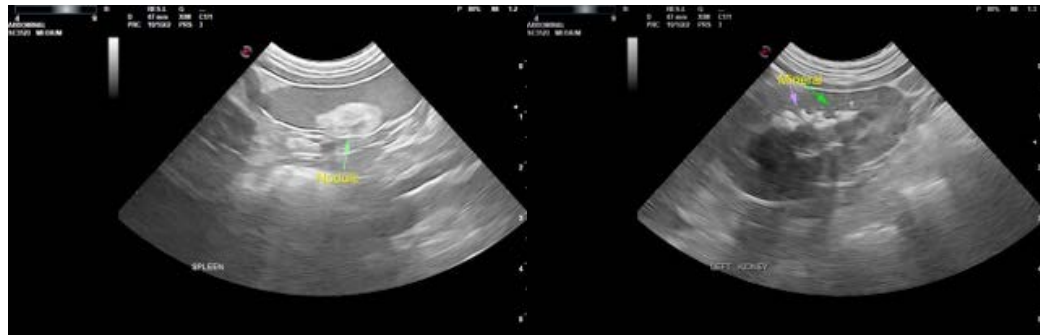Dr. Robyn Lantz

**HOSPITAL NAME**

Eastgate Vet Clinic

**REFERRING VET**

Dr. Robyn Lantz



**INVOICE**

24677

**DATE**

8/13/21



**PATIENT**

Gizmo Firth

**SPECIES**

Canine

**BREED**

Pomeranian X

**SEX**

Neutered Male

**AGE**

15.5 Years

**WEIGHT**

9

**INTERPRETED BY**

R. McKenzie Daniel,  
DVM, DABVP  
(Canine and Feline)

**IMAGING PERFORMED BY**

Dr. Robyn Lantz

**HOSPITAL NAME**

Eastgate Vet Clinic

**REFERRING VET**

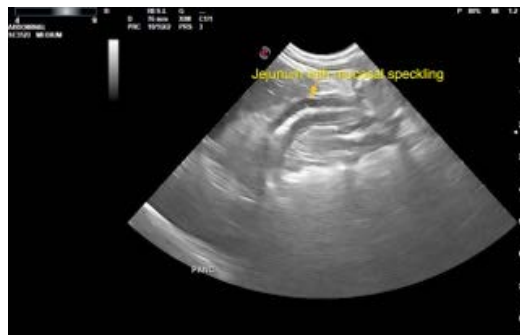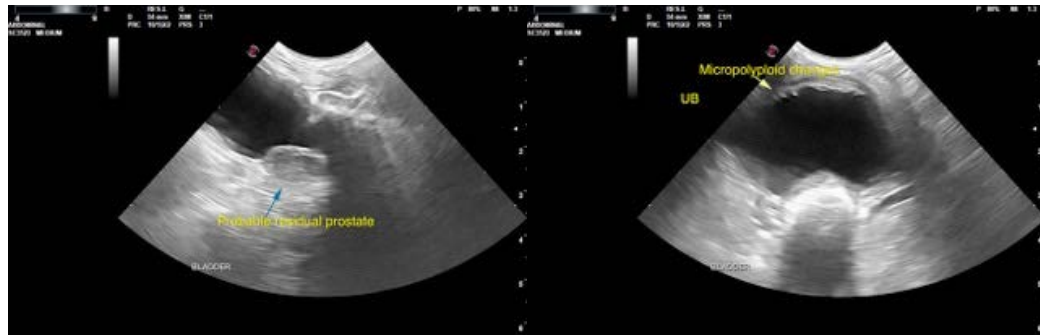
Dr. Robyn Lantz

**INVOICE**

24677

**DATE**

8/13/21



The information and recommendations provided are based on the images presented by the referring veterinarian. No evaluation can be communicated regarding pathology that was not visible in the image/video clips provided.

Thank you for this referral. If the clinical or image interpretation does not parallel your findings or if I can be of any further assistance please contact me.

**R. McKenzie Daniel, DVM, DABVP (Canine / Feline Practice)**  
info@SonoPath.com