



PATIENT

Tug Elkborn

SPECIES

Canine

BREED

Pitbull

SEX

Male

AGE

13 Years

WEIGHT

71 Pounds

INTERPRETED BY

R. McKenzie Daniel,
DVM, DABVP
(Canine and Feline)

IMAGING PERFORMED BY

Chaley Hunt, LVT

HOSPITAL NAME

Relief Scan LLC

REFERRING VET

Dr. Michelle Engel

INVOICE

23873

DATE

8/11/23

PRESENTING CLINICAL SIGNS

Suddenly lethargic, weak, and ataxic. Seemed to recover a little but still lethargic after a couple days. Abnormal PE/Chem/CBC/UA Results: CBC: HCT-22.3 Hemoglobin-8.1 Retic.-226.7 WBC-21,160, neut-15,040, lymph-5220, plat-76 Chemistry-NSF Radiographs- Thoracic mass just cranial to the heart.

ULTRASONOGRAPHIC EXAMINATION OF THE ABDOMEN

Urinary System

The urinary bladder, trigone and cystourethral junction exhibited normal thickness and tone. Anechoic urine was present in the lumen with no uroliths or sediment. The ureteral papillae were normal. The ureters were not visible which is normal. No evidence of inflammatory or neoplastic changes were noted.

The prostate was enlarged in size with intact, symmetrical capsule contour. The margins of the gland were intact and able to be differentiated from the surrounding tissue. The prostatic parenchyma was mildly echogenic to heteroechoic without parenchymal mineralization. The prostate measured 6.2 cm x 5.0 cm.

Anechoic, thinly walled parenchyma cysts were present.

The area of the aortic trifurcation was free of pathology.

Normal size and margination were present in the kidneys. A normal 1:3 cortex / medulla ratio was maintained. The medulla and cortices were uniform in texture with some increased echogenicity and mild loss of corticomedullary symmetry and definition expected for the age of the patient. No evidence of pelvic dilation was present. The left kidney measured 7.8 cm in length. The right kidney measured 7.0 cm in length.

Adrenal Glands

The left adrenal gland was enlarged in size with mild capsule asymmetry and nonhomogenous parenchyma, exhibiting subjective central parenchymal mineralization. The left adrenal gland measured 3.2 cm x 2.4 cm.

The right adrenal gland was overtly normal in size, position and shape, subjectively measuring 0.65 cm at the caudal pole.

Spleen

The spleen exhibited subjective normal size with maintained symmetrical capsule contour. Subtle generalized splenic parenchyma heterogeneity was noted. A solitary nondisruptive hypoechoic splenic nodule was noted, measuring 1.1 cm in diameter in the subjective mid spleen. No splenic masses were noted.

Liver

The liver was subjectively normal in size, structure, and contour. The liver parenchyma was mildly nonuniform and hypoechoic to the spleen with a moderate coarse echotexture and subjective mild to benign parenchymal remodeling. The hepatic and portal vasculature were normal in appearance without signs of congestion.



PATIENT

The gallbladder was non-distended in size with thin walls and primarily anechoic luminal content. The cystic and common bile ducts were normal.

Tug Elkborn

Gastrointestinal

SPECIES

The stomach presented intact wall layering with a normal wall layer ratio. The lumen of the stomach was empty with no signs of ileus, obstruction or foreign material.

Canine

The small intestine presented intact wall layering with 1:3 muscularis/mucosa ratio. The lumen of the small intestine was empty with no signs of ileus, obstruction or foreign material.

BREED

Pitbull

Normal visible colon wall layers were present with apparent formed feces in lumen.

SEX

Pancreas

The pancreas base and right pancreatic limb exhibited mild prominent size with capsule asymmetry. Isoechoic to heterogeneous parenchyma was noted, compared to adjacent omentum. No signs of active inflammation or neoplasia.

Male

AGE

Free Abdomen

No overt lymphadenopathy or peritoneal effusion was present.

13 Years

WEIGHT

ULTRASONOGRAPHIC FINDINGS

71 Pounds

- Enlarged nonhomogenous prostate gland- benign prostatic hyperplasia, potential for prostatitis. Emerging prostatic neoplastic criteria is thought less likely.
- Mild chronic renal changes
- Enlarged left adrenal gland, exhibiting nonhomogenous subjective mild mineralized parenchyma
- Mild hepatic parenchymal remodeling- subjectively benign
- Prominent heterogenous to remodeled pancreas base/right pancreatic limb. Age/patient variant, benign remodeling owing to previous inflammation or chronic pancreatitis is possible.
- Nonspecific splenic nodule- incidental to focal hyperplasia, hematopoiesis, splenitis suspected. Potential for emerging nodular splenic primary or metastatic neoplastic criteria possible.

INTERPRETED BY

R. McKenzie Daniel,
DVM, DABVP
(Canine and Feline)

IMAGING PERFORMED BY

Chaley Hunt, LVT

HOSPITAL NAME

Relief Scan LLC

INTERPRETATION OF THE FINDINGS & FURTHER RECOMMENDATIONS

REFERRING VET

Dr. Michelle Engel

Although potential for benign etiologies, i.e., benign hyperplasia or adenomatous change, the enlarged left adrenal gland is highly likely neoplastic, although no overt evidence of vascular invasion. Primary concern for left. Pheochromocytoma in light of patients clinical signs. Screening blood pressure to assess for evidence of hypertension and urine catecholamine levels are suggested.

INVOICE

Assuming normal clotting status, screening FNA cytology of the splenic nodule, using 25G needle could be considered for further clarification. Sonographic monitoring of the splenic nodule for evidence of progression would be a more conservative approach. Ideally, abdominal CT for further assessment and clarification of the left adrenomegaly and surgical planning, if surgery is a potential in this case, is recommended.

23873

DATE

8/11/23



PATIENT

Tug Elkborn

SPECIES

Canine

BREED

Pitbull

SEX

Male

AGE

13 Years

WEIGHT

71 Pounds

INTERPRETED BY

R. McKenzie Daniel, DVM, DABVP (Canine and Feline)

IMAGING PERFORMED BY

Chaley Hunt, LVT

HOSPITAL NAME

Relief Scan LLC

REFERRING VET

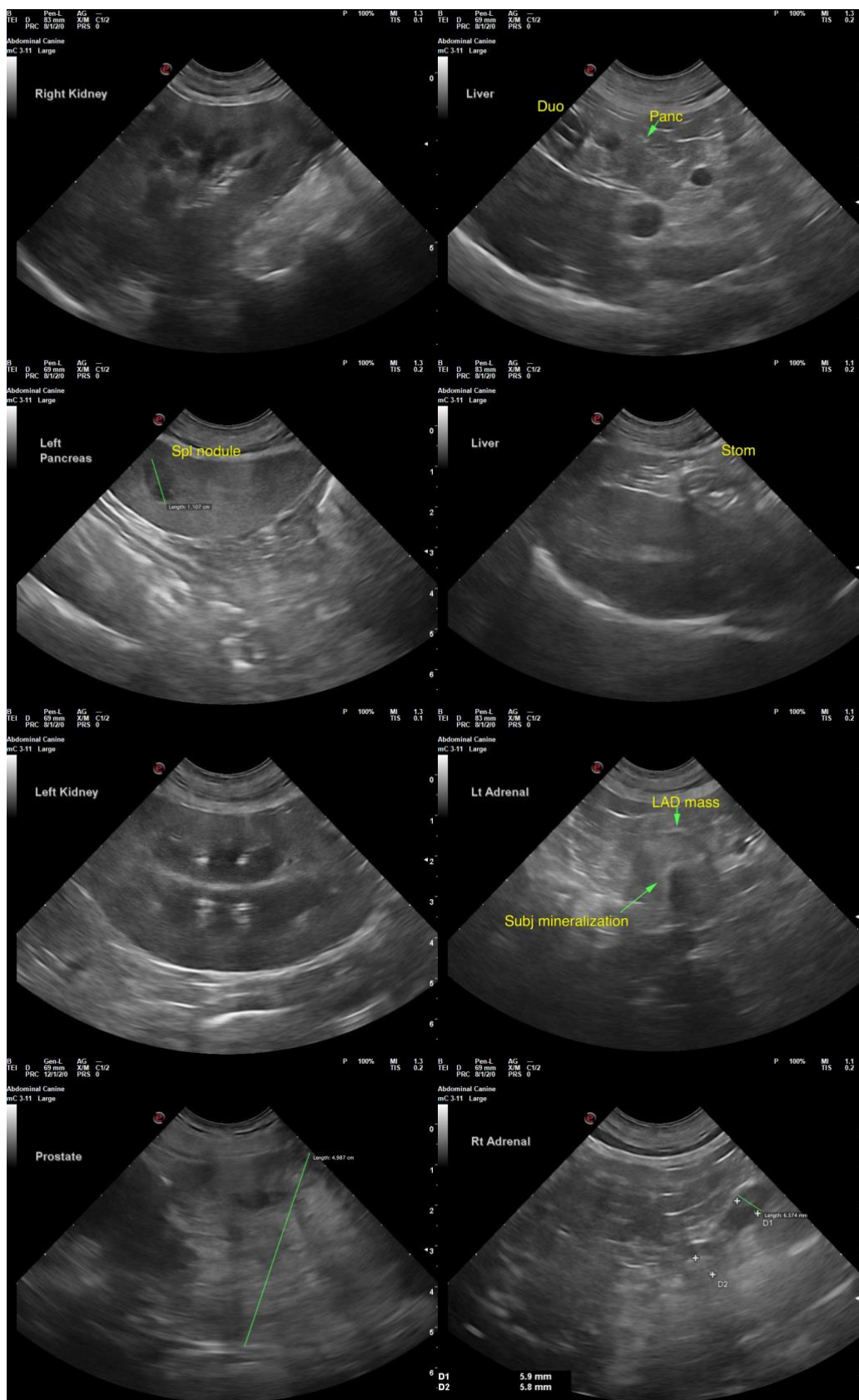
Dr. Michelle Engel

INVOICE

23873

DATE

8/11/23





PATIENT

Tug Elkborn

The information and recommendations provided are based on the images presented by the referring veterinarian. No evaluation can be communicated regarding pathology that was not visible in the image/video clips provided.

SPECIES

Canine

Thank you for this referral. If the clinical or image interpretation does not parallel your findings or if I can be of any further assistance please contact me.

BREED

Pitbull

R. McKenzie Daniel, DVM, DABVP (Canine / Feline Practice)
info@SonoPath.com

SEX

Male

AGE

13 Years

WEIGHT

71 Pounds

INTERPRETED BY

R. McKenzie Daniel,
DVM, DABVP
(Canine and Feline)

**IMAGING
PERFORMED BY**

Chaley Hunt, LVT

HOSPITAL NAME

Relief Scan LLC

REFERRING VET

Dr. Michelle Engel

INVOICE

23873

DATE

8/11/23