

PATIENT

Apollo Vesperino

PRESENTING CLINICAL SIGNS

New murmur noted- Grade 2/6

SPECIES

Feline

SUBJECTIVE CARDIAC PRESENTATION

The left ventricular wall exhibited potential for borderline to mild hypertrophy. Normal overall myocardial echogenicity was present. Subjective mildly prominent papillary muscles were visualized. The right ventricle appears overtly normal. The left and right atrium were subjectively normal in dimension containing anechoic content. No overt arrhythmia noted. No evidence of pericardial or pleural effusion. No cardiac tumors.

BREED

DSH

ULTRASONOGRAPHIC FINDINGS

SEX

MN

- Overtly normal cardiac function
- Possible although not definitive borderline to mild thickened LV.
- Subjectively normal LA/RA.

AGE

5yr

INTERPRETATION OF THE FINDINGS & FURTHER RECOMMENDATIONS

No evidence of significant cardiomyopathy was present in this study including no evidence of clinical issues such as left/right heart chamber enlargement, arrhythmia or LV systolic dysfunction. A definitive cause of the patient's low grade murmur was not evident. Regardless, the lack of left or right heart chamber enlargement indicate that the hemodynamic effects of the murmur are minimal.

WEIGHT

15

The subjective potential for borderline/mild increased LV wall dimension is of unclear clinical significance. Assessment of T4 and systemic BP to rule out potential complicating factors is recommended. Ideally echocardiographic reassessment or referral to a cardiologist for a thorough baseline echocardiogram is recommended.

INTERPRETED BY

R. McKenzie Daniel,
DVM, DABVP
(Canine and Feline)

IMAGING PERFORMED BY

Hope Brossman

HOSPITAL NAME

Animal Mansion
Veterinary Hospital

REFERRING VET

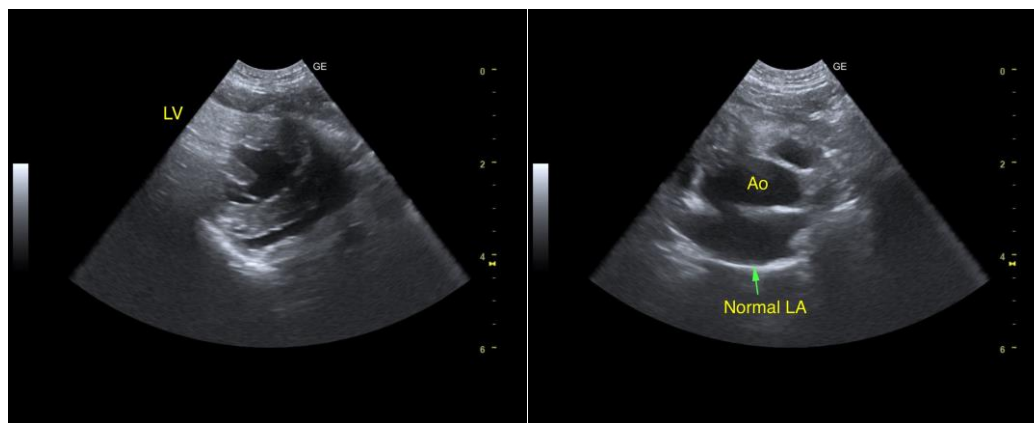
Jon Bertoldo DVM

INVOICE

14567ag

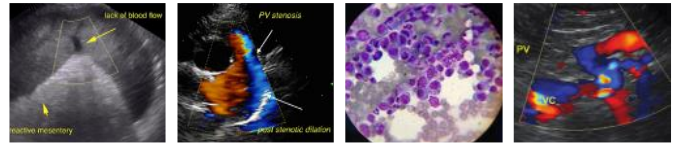
DATE

08/11/2023



The information and recommendations provided are based on the images presented by the referring veterinarian/sonographer. No evaluation can be communicated regarding pathology that was not visible in the image/video clips provided.

Thank you for this referral. If the clinical or image interpretation does not parallel your findings or if I



PATIENT

can be of any further assistance, please contact me.

Apollo Vesperino

SPECIES

R. McKenzie Daniel, DVM, DABVP (Canine/Feline Practice)
info@sonopath.com

Feline

BREED

DSH

SEX

MN

AGE

5yr

WEIGHT

15

INTERPRETED BY

R. McKenzie Daniel,
DVM, DABVP
(Canine and Feline)

**IMAGING
PERFORMED BY**

Hope Brossman

HOSPITAL NAME

Animal Mansion
Veterinary Hospital

REFERRING VET

Jon Bertoldo DVM

INVOICE

14567ag

DATE

08/11/2023