



## PATIENT

Rosie Lombardi

## SPECIES

Canine

## BREED

Poodle Mix

## SEX

FS

## AGE

8yr

## WEIGHT

13.02lb

## PRESENTING CLINICAL SIGNS

New grade III/VI heart murmur. BP 173/102; Hx: Proteinuria (increasingly uncontrolled); seizures; hypertension; obesity; suspected Cushings (tested normal in past) Current Meds: Semintra; Amlodipine; Phenobarb

Abnormal PE/Chem/CBC/UA Results: Retic 118; PLT 665; TT4 1.6; Glu 128; Cl 102; ALP 803; Chol 630; USG 1.018; +8 protein (UPC ratio 5.6)

## ULTRASONOGRAPHIC EXAMINATION OF THE HEART

CANINE CARDIAC PARAMETERS	MR VMAX (m/s)	TR VMAX (m/s)	LA/AO (Boon method)	LA/AO (Heart Base; Swe)	FS (%)	EF (%)	EPSS (cm)
NORMAL PARAMETER	4.5-5.5	<2.7	1.3	<1.6	28-40	40-100	<0.6
PATIENT	5.2	1.5	1.1	1.2	40	74	0.22
CANINE CARDIAC PARAMETERS	HR (BPM)	AV VMAX (m/s)	PV MAX (m/s)	BODY WEIGHT (kg)	LA 2D short axis Base view (cm)	LVIDd Avg; 2D and m-mode short axis (cm)	LVIDs Avg; 2D and m-mode short axis (cm)
NORMAL PARAMETER	50-100	0.7-1.7	0.7-1.6				
PATIENT	167	1.7	1.5		2.2	2.1	

## INTERPRETED BY

R. McKenzie Daniel,  
DVM, DABVP  
(Canine and Feline)

## IMAGING PERFORMED BY

Shari Reffi CVT

## HOSPITAL NAME

Long Valley AH

## REFERRING VET

Dr. Welch

## INVOICE

14563ag

## DATE

08/10/2023

## Cardiac Presentation

The echocardiogram in this patient demonstrated normal left atrial size based on 3 different LA measurement methods. Chamber volumes and echogenicity were normal. The cranial and caudal mitral valve leaflets presented mild thickening consistent with endocardiosis. Doppler indicated measurable mild eccentric insufficiency. The left ventricle presented thicknesses with linear contour and was not dilated nor restricted. The myocardium presented normal echogenicity without subjective evidence of significant fibrotic or ischemic disease. Contractility of the ventricular walls was adequate and in normal range for this patient evidenced by the fractional shortening measurement and subjective evaluation of the different regions of the myocardium. The left ventricular outflow tract demonstrated normal laminar flow and subjective structural integrity. The right atrium and auricle revealed normal size, structure and content. No evidence of masses was noted or chamber overload. Tricuspid valvular assessment demonstrated mild thickening with minor TR on Doppler. The right ventricle was of normal size (1/3 diameter of LV), chordae structure, myocardial echogenicity and thickness. Pulmonic tract assessment revealed normal valve structure, laminar flow, and diameter (approx. 1:1 pa/ao ratio). No visible pericardial or free pleura fluid was noted. No echographically detectable evidence of infiltrative disease was visible. The cranial mediastinum and pericardial regions were free of masses in the visible window. Mild pericardial fat was present.



**PATIENT**

Rosie Lombardi

**SPECIES**

Canine

**BREED**

Poodle Mix

**SEX**

FS

**AGE**

8yr

**WEIGHT**

13.02lb

**INTERPRETED BY**

R. McKenzie Daniel,  
DVM, DABVP  
(Canine and Feline)

**IMAGING PERFORMED BY**

Shari Reffi CVT

**HOSPITAL NAME**

Long Valley AH

**REFERRING VET**

Dr. Welch

**INVOICE**

14563ag

**DATE**

08/10/2023

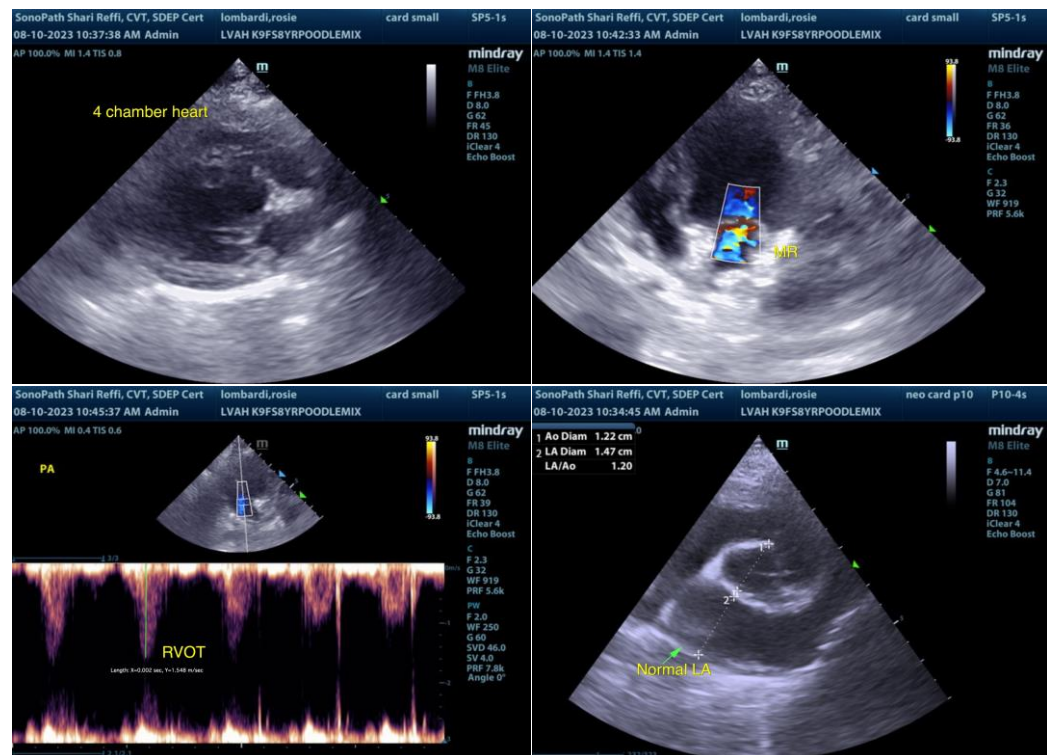
**ULTRASONOGRAPHIC FINDINGS**

- Compensated chronic mitral valve disease (ACVIM B1)
- Minor TR-no evidence of clinical pulmonary hypertension.

**INTERPRETATION OF THE FINDINGS & FURTHER RECOMMENDATIONS**

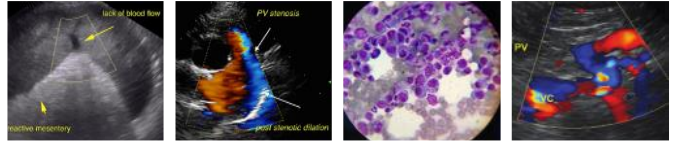
The cause of the murmur is chronic degenerative valvular changes with secondary eccentric mitral valve insufficiency. The lack of left atrial enlargement implies that the risk of complication secondary to mitral valve insufficiency is relatively low at this time and, without current clinical signs, indicates that medical therapy is not required at this stage.

Prognosis at this stage is variable and serial sonographic monitoring is recommended with a recheck echocardiogram in 8-12 months, sooner if clinical signs suggestive of heart disease develop.



The information and recommendations provided are based on the images presented by the referring veterinarian/sonographer. No evaluation can be communicated regarding pathology that was not visible in the image/video clips provided.

Thank you for this referral. If the clinical or image interpretation does not parallel your findings or if I can be of any further assistance, please contact me.



**PATIENT**

R. McKenzie Daniel, DVM, DABVP (Canine/Feline Practice)  
[info@sonopath.com](mailto:info@sonopath.com)

Rosie Lombardi

**SPECIES**

Canine

**BREED**

Poodle Mix

**SEX**

FS

**AGE**

8yr

**WEIGHT**

13.02lb

**INTERPRETED BY**

R. McKenzie Daniel,  
DVM, DABVP  
(Canine and Feline)

**IMAGING  
PERFORMED BY**

Shari Reffi CVT

**HOSPITAL NAME**

Long Valley AH

**REFERRING VET**

Dr. Welch

**INVOICE**

14563ag

**DATE**

08/10/2023