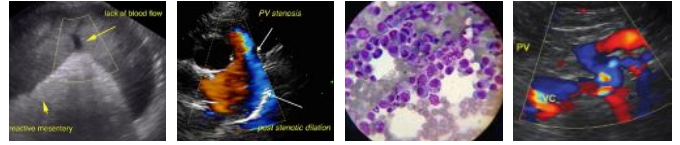




PATIENT	PRESENTING CLINICAL SIGNS
Quistina Phalan	History: Inappetent with episodes of weakness and is lethargic over all. Mass palpated 4-5 cm x 2 cm around and involving one mammary gland left distal thorax.
SPECIES	ULTRASONOGRAPHIC EXAMINATION OF THE ABDOMEN
Canine	Urinary System
BREED	The urinary bladder, trigone, cystourethral junction, and visible pelvic urethra to a depth of 4 cm exhibited normal thickness and tone. Anechoic urine was present in the lumen with no uroliths or sediment. The ureteral papillae were normal. The ureters were not visible which is normal. No evidence of inflammatory or neoplastic changes were noted.
Rottweiler	
SEX	Normal size and margination was present in the kidneys. A normal 1:3 cortex / medulla ratio was maintained. The medulla and cortices were uniform in texture with some increased echogenicity and mild loss of corticomedullary symmetry and definition expected for the age of the patient. No evidence of pelvic dilation was present. The left kidney measured 7.3 cm in length. The right kidney measured 8.0 cm in length.
FS	
AGE	The area of the aortic trifurcation was free of pathology.
10 yr	Adrenal Glands
WEIGHT	The left adrenal gland was uniform in size and contour with a uniformly hypoechoic parenchyma. The left adrenal gland measured 0.76 cm width at the caudal pole and 0.84 cm width at the cranial pole. The right adrenal gland was uniform in size and contour with a uniformly hypoechoic parenchyma. The right adrenal gland measured 0.89 cm width at the caudal pole.
44 kg	
INTERPRETED BY	Spleen
R. McKenzie Daniel, DVM, DABVP (Canine and Feline)	The spleen exhibited generalized parenchymal heterogeneity with intermittent nondisruptive nonhomogeneous to mildly hypoechoic nodules an example measuring 1.3 cm in diameter. The capsule was smooth and regular without apparent expansion. The splenic vasculature at the hilus was normal in volume with no evidence of congestion or thrombosis.
IMAGING PERFORMED BY	Liver
Dr. Belan	The liver was subjectively normal in size, structure, and contour. The liver parenchyma was uniform and hypoechoic to the spleen with a mild coarse echotexture. The hepatic and portal vasculature were normal in appearance without signs of congestion. The gallbladder was non-distended in size with thin walls and primarily anechoic luminal content. The cystic and common bile ducts were normal.
HOSPITAL NAME	Gastrointestinal
McKnight VC	The stomach presented intact yet thickened wall layering with a normal wall layer ratio. The lumen of the stomach contained minor anechoic fluid with no signs of ileus, obstruction or foreign material. The gastric body wall measured 0.69 cm in width.
REFERRING VET	The small intestine presented intact wall layering with 1:3 muscularis/mucosa ratio. The lumen of the small intestine was empty with no signs of ileus, obstruction or foreign material. The duodenum wall measured 0.52 cm in width. The jejunum wall measured 0.32 cm in width.
Dr. Gruffydd	Normal visible colon wall layers were present with apparent formed feces in lumen.
INVOICE	Pancreas
11069ag	
DATE	
07/08/2022	



PATIENT

Quistina Phalan

The parenchyma of the left limb, body and right limb of the pancreas presented isoechoic to the adjacent omental fat. A normal curvilinear capsule contour of the pancreas was present. The visible pancreatic duct was normal. No signs of active inflammation or neoplastic disease was evident.

SPECIES

Canine

Free Abdomen

No omental masses, overt lymphadenopathy or peritoneal effusion was present.

BREED

Rottweiler

A rapid view of the heart revealed subjective normal cardiac structure and function with no overt evidence of pleural effusion. A solid nonhomogeneous mass lesion was present in the caudal thorax directly effacing the cranial aspect of the adjacent diaphragm and surrounded by aerated lung. The lesion exhibited pinpoint to focal hyperechoic foci which may indicate areas of air entrapment vs mineralization. This mass measured approximately 9 cm in diameter.

SEX

FS

ULTRASONOGRAPHIC FINDINGS

- Intact mildly thickened gastric walls with mild gastric hypomotility-suggestive of mild gastritis
- Sonographically normal small bowel/pancreas
- Mild age related kidney changes
- Caudal pulmonary mass lesion
- Generalized mild splenic heterogeneity with intermittent nodules-hyperplasia, hematopoiesis, hematomas, granulomas or emerging primary vs metastatic neoplasia

AGE

10 yr

WEIGHT

44 kg

INTERPRETATION OF THE FINDINGS & FURTHER RECOMMENDATIONS

Empirical therapy for gastritis which may include gastric protectant medication and dietary therapy with as needed GI support is recommended.

INTERPRETED BY

R. McKenzie Daniel,
DVM, DABVP
(Canine and Feline)

The caudal pulmonary mass lesion is suggestive of neoplastic criteria although sampling is needed for further assessment. This may indicate a primary pulmonary neoplastic process vs metastasis given the reported mammary gland pathology. If accessible an ultrasound guided FNA of the caudal pulmonary mass is recommended for screening cytology. A thoracic CT may be required for further assessment.

IMAGING PERFORMED BY

Dr. Belan

Concurrent splenic nodule FNA using a 25g needle as assuming normal clotting status is recommended for further assessment.

HOSPITAL NAME

McKnight VC

REFERRING VET

Dr. Gruffydd

INVOICE

11069ag

DATE

07/08/2022



PATIENT

Quistina Phalan

SPECIES

Canine

BREED

Rottweiler

SEX

FS

AGE

10 yr

WEIGHT

44 kg

INTERPRETED BY

R. McKenzie Daniel,
DVM, DABVP
(Canine and Feline)

IMAGING PERFORMED BY

Dr. Belan

HOSPITAL NAME

McKnight VC

REFERRING VET

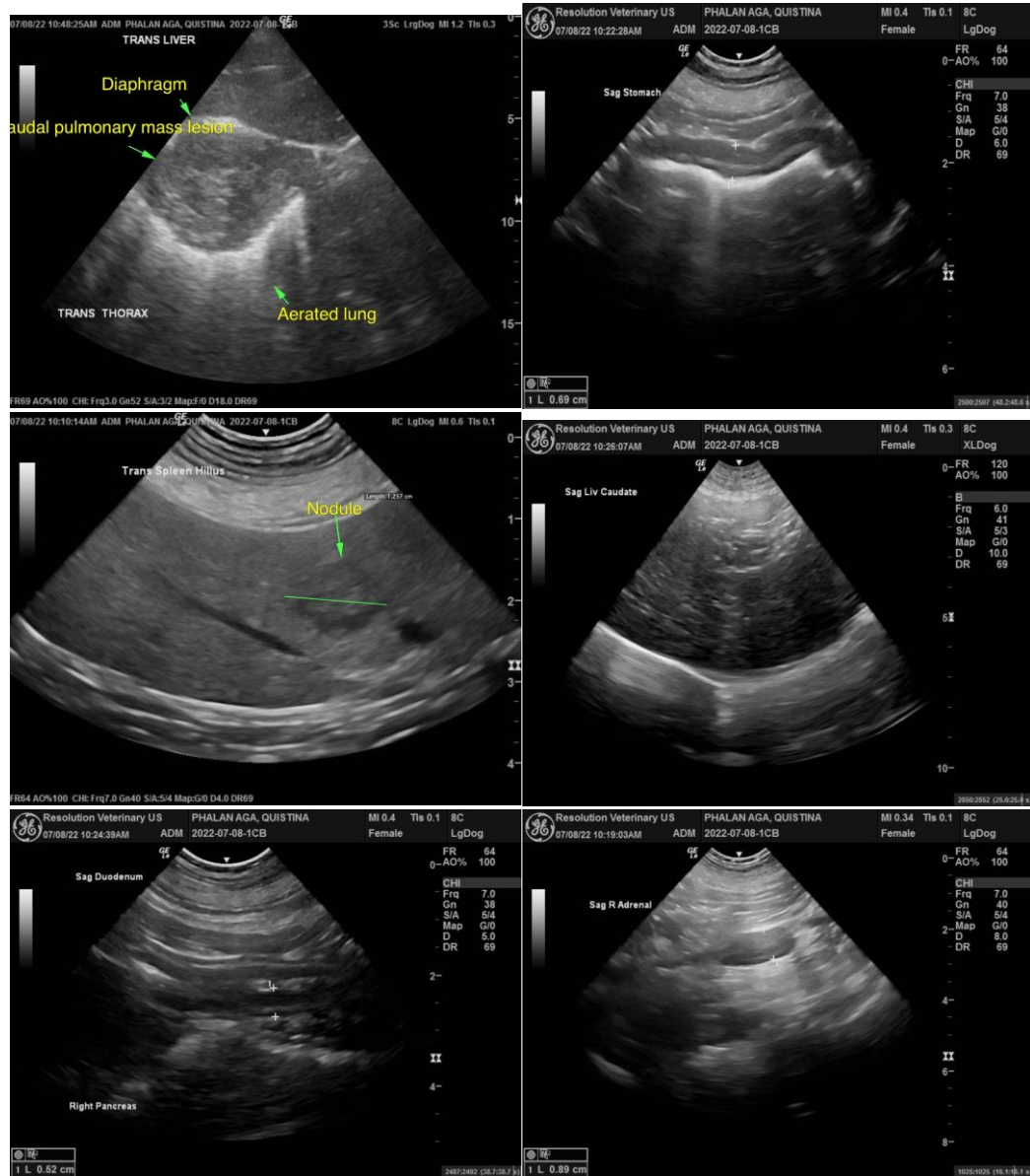
Dr. Gruffydd

INVOICE

11069ag

DATE

07/08/2022





PATIENT

Quistina Phalan

SPECIES

Canine

BREED

Rottweiler

SEX

FS

AGE

10 yr

WEIGHT

44 kg

INTERPRETED BY

R. McKenzie Daniel,
DVM, DABVP
(Canine and Feline)

IMAGING PERFORMED BY

Dr. Belan

HOSPITAL NAME

McKnight VC

REFERRING VET

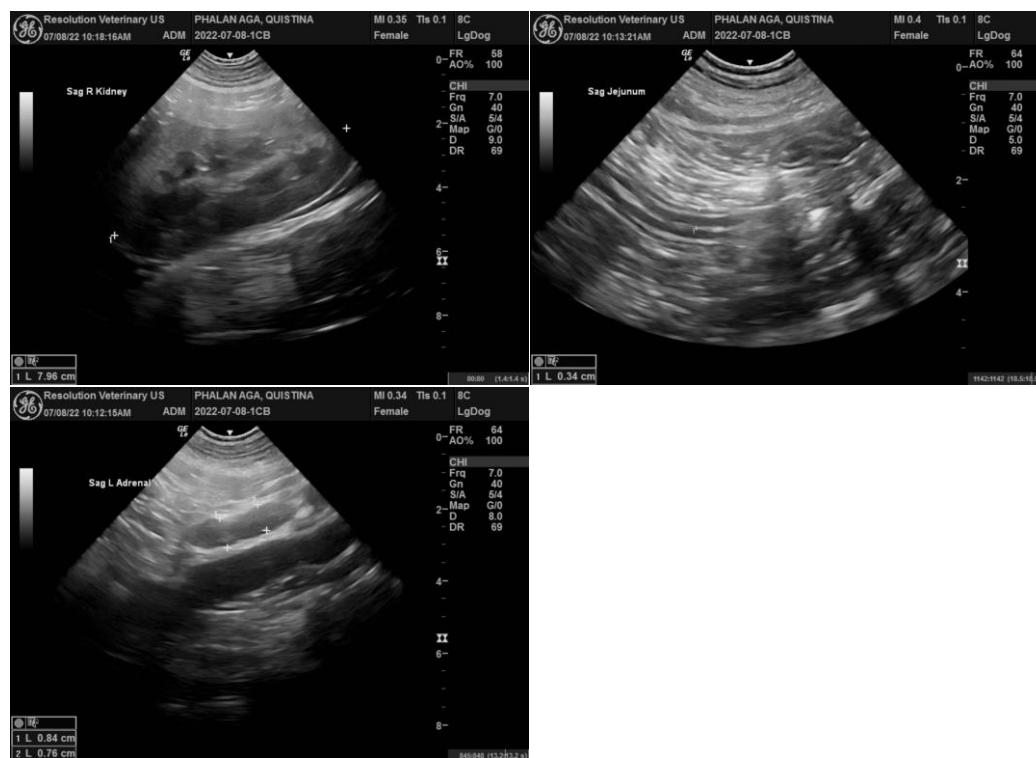Dr. Gruffydd

INVOICE

11069ag

DATE

07/08/2022



The information and recommendations provided are based on the images presented by the referring veterinarian/sonographer. No evaluation can be communicated regarding pathology that was not visible in the image/video clips provided.

Thank you for this referral. If the clinical or image interpretation does not parallel your findings or if I can be of any further assistance please contact me.

R. McKenzie Daniel, DVM, DABVP (Canine / Feline Practice)

info@SonoPath.com