



PATIENT PRESENTING CLINICAL SIGNS

Lexie Howell History: Intermittent episodes of lethargy, vomiting and polydipsia.

SPECIES Abnormal PE/Chem/CBC/UA Results: PCV 30.0 %, hypochromic. Strongly regenerative (Retic 227). Rest of labwork unremarkable.

Canine

ULTRASONOGRAPHIC EXAMINATION OF THE ABDOMEN

BREED
Urinary System

Dachshund The urinary bladder, trigone, cystourethral junction, and visible pelvic urethra to a depth of 2.0 cm exhibited normal thickness and tone. Anechoic urine was present in the lumen with no uroliths or sediment. The ureteral papillae were normal. The ureters were not visible which is normal. No evidence of inflammatory or neoplastic changes were noted.

SEX

Spayed Female

AGE

10 Years

Normal size and margination was present in the kidneys. A normal 1:3 cortex / medulla ratio was maintained. The medulla and cortices were uniform in texture with some increased echogenicity and minor loss of corticomedullary symmetry and definition expected for the age of the patient. No evidence of pelvic dilation was present. The left kidney measured 4.0 cm in length. The right kidney measured 4.5 cm in length.

WEIGHT

10 Pounds

Adrenal Glands

The left adrenal gland was uniform in size and contour with a uniformly hypoechoic parenchyma. The left adrenal gland measured 1.7 cm in length x 0.45 cm width at the caudal pole.

INTERPRETED BY

R. McKenzie Daniel,
DVM, DABVP
(Canine and Feline)

The right adrenal gland was uniform in size and contour with a uniformly hypoechoic parenchyma. The right adrenal gland measured 1.8 cm in length x 0.40 cm width at the caudal pole.

IMAGING PERFORMED BY

Jenna Walsh

Spleen

The spleen exhibited primarily finely textured parenchyma which was hyperechoic to the liver and renal cortical parenchyma. Mild generalized parenchyma heterogeneity was present without evidence of nodular changes. The capsule was smooth and regular without apparent expansion. The splenic vasculature at the hilus was normal in volume with no evidence of congestion or thrombosis. The parenchymal heterogeneity is likely consistent with benign changes such as extramedullary hematopoiesis or age related remodeling with minor potential for inflammatory or primary neoplastic disease.

HOSPITAL NAME

Cottage Grove VC

REFERRING VET

Dr. Damewood

Liver

The liver was subjectively normal in size, structure, and contour. The liver parenchyma was uniform and hypoechoic to the spleen with a mild coarse echotexture. The hepatic and portal vasculature were normal in appearance without signs of congestion. No evidence of hepatic congestion.

INVOICE

16523

The gallbladder was non-distended in size with thin walls and primarily anechoic luminal content. The cystic and common bile ducts were normal.

DATE

7/7/22

Gastrointestinal



PATIENT

The stomach presented intact wall layering with a normal wall layer ratio. The lumen of the stomach contained mild ingesta/chyme without signs of obstruction or foreign material.

Lexie Howell

SPECIES

The small intestine presented intact wall layering with 1:3 muscularis/mucosa ratio. The lumen of the small intestine was empty with no signs of ileus, obstruction or foreign material.

Canine

Normal visible colon wall layers were present with apparent formed feces in lumen.

BREED

Pancreas

Dachshund

The parenchyma of the left limb, body and right limb of the pancreas presented isoechoic to the adjacent omental fat. A normal curvilinear capsule contour of the pancreas was present. The visible pancreatic duct was normal. No signs of active inflammation or neoplastic disease was evident.

SEX

Free Abdomen

Spayed Female

No omental masses, lymphadenopathy or evidence of peritoneal effusion was present.

AGE

Other

10 Years

Heart

WEIGHT

A brief sonographic assessment of the heart revealed moderate to significant volume pericardial effusion with large nonhomogeneous mass in the area of the heart base and right atrium/auricle, measuring approximately 5.0 cm in diameter. No overt evidence of left or right chamber enlargement.

10 Pounds

INTERPRETED BY

ULTRASONOGRAPHIC FINDINGS

R. McKenzie Daniel,
DVM, DABVP
(Canine and Feline)

- Large nonhomogeneous heart base mass in the area of the right atrium and auricle with secondary pericardial effusion.
- Minor chronic renal changes
- Sonographically unremarkable spleen- no evidence of primary splenic neoplastic criteria
- Sonographically unremarkable liver- no evidence of hepatic neoplastic criteria or congestion

IMAGING PERFORMED BY

Jenna Walsh

HOSPITAL NAME

INTERPRETATION OF THE FINDINGS & FURTHER RECOMMENDATIONS

Cottage Grove VC

The most likely tumor type given this location is hemangiosarcoma with other tumor types considered less likely, including chemodectoma, ectopic parathyroid tumor or other. No overt evidence of current cardiac tamponade yet potential for future cardiac tamponade is high.

REFERRING VET

Dr. Damewood

Referral for emergency pericardiocentesis with cytology of the pericardial fluid for further assessment and potential definitive diagnosis is warranted. Oncology consult recommended to discuss chemotherapy and/or radiation could be considered.

INVOICE

16523

Long term prognosis is unfortunately poor with high potential for recurrent pericardial effusion, development of cardiac tamponade, malignant arrhythmias and/or sudden death is very possible.

DATE

7/7/22



PATIENT

Lexie Howell

SPECIES

Canine

BREED

Dachshund

SEX

Spayed Female

AGE

10 Years

WEIGHT

10 Pounds

INTERPRETED BY

R. McKenzie Daniel,
DVM, DABVP
(Canine and Feline)

IMAGING PERFORMED BY

Jenna Walsh

HOSPITAL NAME

Cottage Grove VC

REFERRING VET

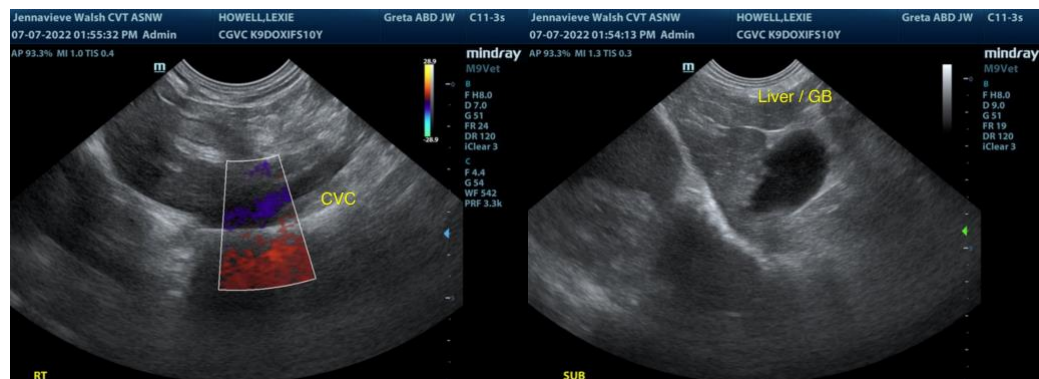
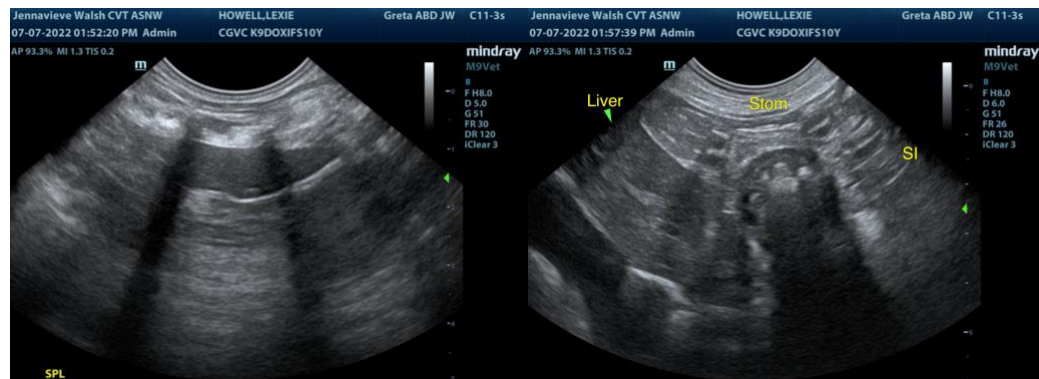
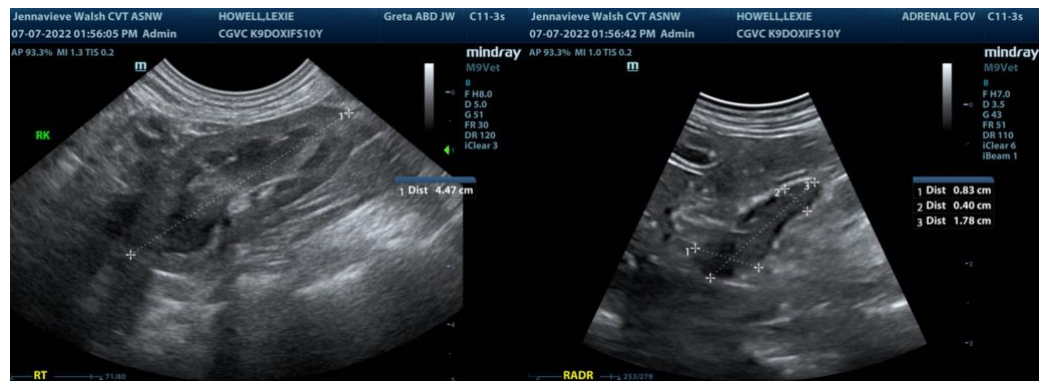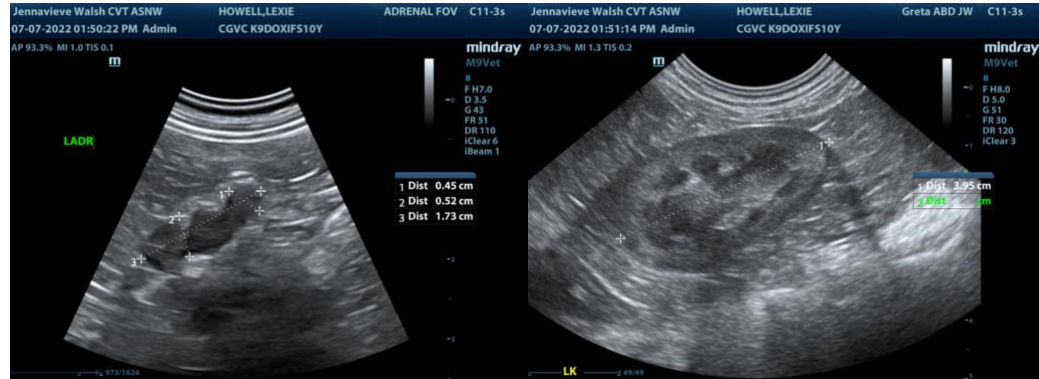
Dr. Damewood

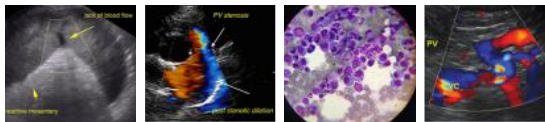
INVOICE

16523

DATE

7/7/22





PATIENT

Lexie Howell

SPECIES

Canine

BREED

Dachshund

SEX

Spayed Female

AGE

10 Years

WEIGHT

10 Pounds

INTERPRETED BY

R. McKenzie Daniel,
DVM, DABVP
(Canine and Feline)

IMAGING PERFORMED BY

Jenna Walsh

HOSPITAL NAME

Cottage Grove VC

REFERRING VET

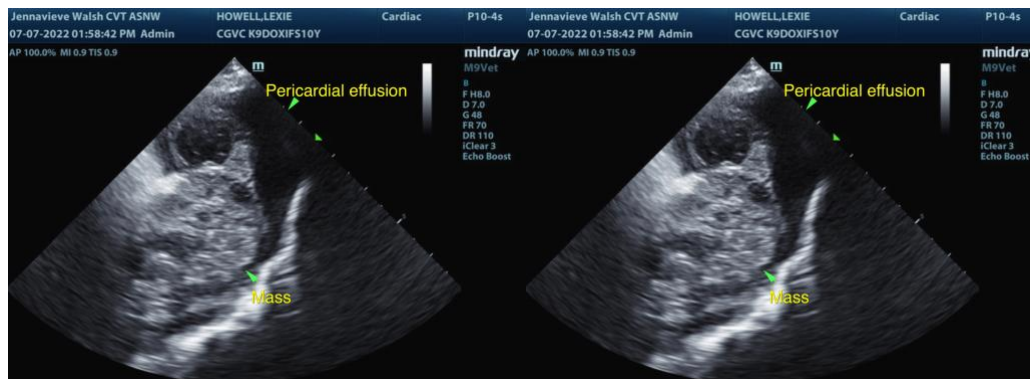
Dr. Damewood

INVOICE

16523

DATE

7/7/22



The information and recommendations provided are based on the images presented by the referring veterinarian. No evaluation can be communicated regarding pathology that was not visible in the image/video clips provided.

Thank you for this referral. If the clinical or image interpretation does not parallel your findings or if I can be of any further assistance please contact me.

R. McKenzie Daniel, DVM, DABVP (Canine / Feline Practice)
info@SonoPath.com