



PATIENT

Murphy Granatell

SPECIES

Canine

BREED

Golden Retriever

SEX

MN

AGE

10 yr

WEIGHT

85 lb

INTERPRETED BY

R. McKenzie Daniel,
DVM, DABVP
(Canine and Feline)

IMAGING PERFORMED BY

Kelly Vazquez

HOSPITAL NAME

Ramapo Valley
Animal Hospital

REFERRING VET

Dr. Gary Duhr

INVOICE

11037ag

DATE

07/05/2022

PRESENTING CLINICAL SIGNS

History: Patient presents for an 8lbs weight loss since 3/22. Splenomegaly on radiographs.

Abnormal PE/Chem/CBC/UA Results: In-house PCV 30, TP 7.0, glucose 94, 4D snap (neg_ - 7/5/22. U/A: pending.

ULTRASONOGRAPHIC EXAMINATION OF THE ABDOMEN

Urinary System

The urinary bladder, trigone, cystourethral junction, and visible pelvic urethra to a depth of 3 cm exhibited normal thickness and tone. Anechoic urine was present in the lumen with no uroliths or sediment. The ureteral papillae were normal. The ureters were not visible which is normal. No evidence of inflammatory or neoplastic changes were noted.

Normal size and margination was present in the kidneys. A normal 1:3 cortex / medulla ratio was maintained. The medulla and cortices were uniform in texture with some increased echogenicity and mild loss of corticomedullary symmetry and definition expected for the age of the patient. No evidence of pelvic dilation was present. The left kidney measured 7.4 cm in length. The right kidney measured 6.8 cm in length.

The area of the aortic trifurcation was free of pathology.

No overt pathology in the area of the residual prostate. The residual prostate measured 1.2 cm in diameter.

Adrenal Glands

The left adrenal gland was uniform in size and contour with a uniformly hypoechoic parenchyma. The left adrenal gland measured 0.58 cm width at the caudal pole and 1.8 cm length. The right adrenal gland was uniform in size and contour with a uniformly hypoechoic parenchyma. The right adrenal gland measured 0.93 cm width at the caudal pole and 2.5 cm length.

Spleen

The spleen was enlarged in size with mild asymmetrical medial capsule contour and diffuse hypoechoic nodular parenchyma. An example of a nodule measured 1.1 cm in diameter. No evidence of parenchymal escape was noted. The splenic vasculature at the hilus was normal in volume with no evidence of congestion or thrombosis.

Liver

The liver was subjectively normal in size, structure, and contour. The liver parenchyma was mildly nonuniform and hypoechoic to the spleen with a moderate coarse echotexture and subjective mild to benign parenchymal remodeling. The hepatic and portal vasculature were normal in appearance without signs of congestion.

The gallbladder was non-distended in size with thin walls and primarily anechoic luminal content with mild to moderate nondependent nonorganized debris. The cystic and common bile ducts were normal.

Gastrointestinal

The stomach presented intact wall layering with a normal wall layer ratio. The lumen of the stomach contained mild ingesta exhibiting subtle progressive distal acoustic shadowing with no signs of ileus, obstruction or foreign material. The gastric body wall measured 0.46 cm in width.



PATIENT

Murphy Granatell

The small intestine presented intact wall layering with 1:3 muscularis/mucosa ratio. The lumen of the small intestine was empty with no signs of ileus, obstruction, mural lesions/tumors or foreign material. The small intestine wall measured 0.55 cm in width.

SPECIES

Canine

Normal visible colon wall layers were present with apparent formed feces in lumen.

Pancreas

The parenchyma of the left limb, body and right limb of the pancreas presented isoechoic to the adjacent omental fat. A normal curvilinear capsule contour of the pancreas was present. The visible pancreatic duct was normal. No signs of active inflammation or neoplastic disease was evident.

BREED

Golder Retriever

Free Abdomen

Multiple enlarged, hypoechoic mid abdominal and medial iliac lymph nodes were present. The lymph nodes exhibited symmetrical to rounded margination with abnormal width: length ratio (>0.5). The enlarged lymph nodes were bordered by echogenic to reactive mesentery. An example of a mid-abdominal lymph node measured 3.6 cm length and 2.1 cm width.

SEX

MN

AGE

10 yr

Rapid view of the heart revealed no evidence of pericardial masses or effusion in the visible window.

WEIGHT

85 lb

ULTRASONOGRAPHIC FINDINGS

- Splenomegaly with diffuse hypoechoic parenchymal nodules
- Multifocal hypoechoic to swollen intra-abdominal and medial iliac lymphadenopathy
- Minor hepatic parenchymal remodeling
- Mild chronic renal changes
- Mild to moderate gallbladder debris (non-mucocele)

INTERPRETED BY

R. McKenzie Daniel,
DVM, DABVP
(Canine and Feline)

INTERPRETATION OF THE FINDINGS & FURTHER RECOMMENDATIONS

Although sampling is required for further clarification, the honeycomb splenic pattern and concurrent intra-abdominal and medial iliac lymphadenopathy is most consistent with multicentric splenic and lymphatic neoplasia such as multicentric lymphoma. Benign changes such as splenic lymphoid hyperplasia or non-neoplastic lymphadenopathy are considered less likely. Assuming normal clotting status, splenic and lymph node FNA using a 25g needle is warranted for screening cytology and potential oncology consult. Three view chest radiographs are recommended if not already done.

IMAGING PERFORMED BY

Kelly Vazquez

HOSPITAL NAME

Ramapo Valley
Animal Hospital

REFERRING VET

Dr. Gary Duhr

INVOICE

11037ag

DATE

07/05/2022



PATIENT

Murphy Granatell

SPECIES

Canine

BREED

Golden Retriever

SEX

MN

AGE

10 yr

WEIGHT

85 lb

INTERPRETED BY

R. McKenzie Daniel,
DVM, DABVP
(Canine and Feline)

IMAGING PERFORMED BY

Kelly Vazquez

HOSPITAL NAME

Ramapo Valley
Animal Hospital

REFERRING VET

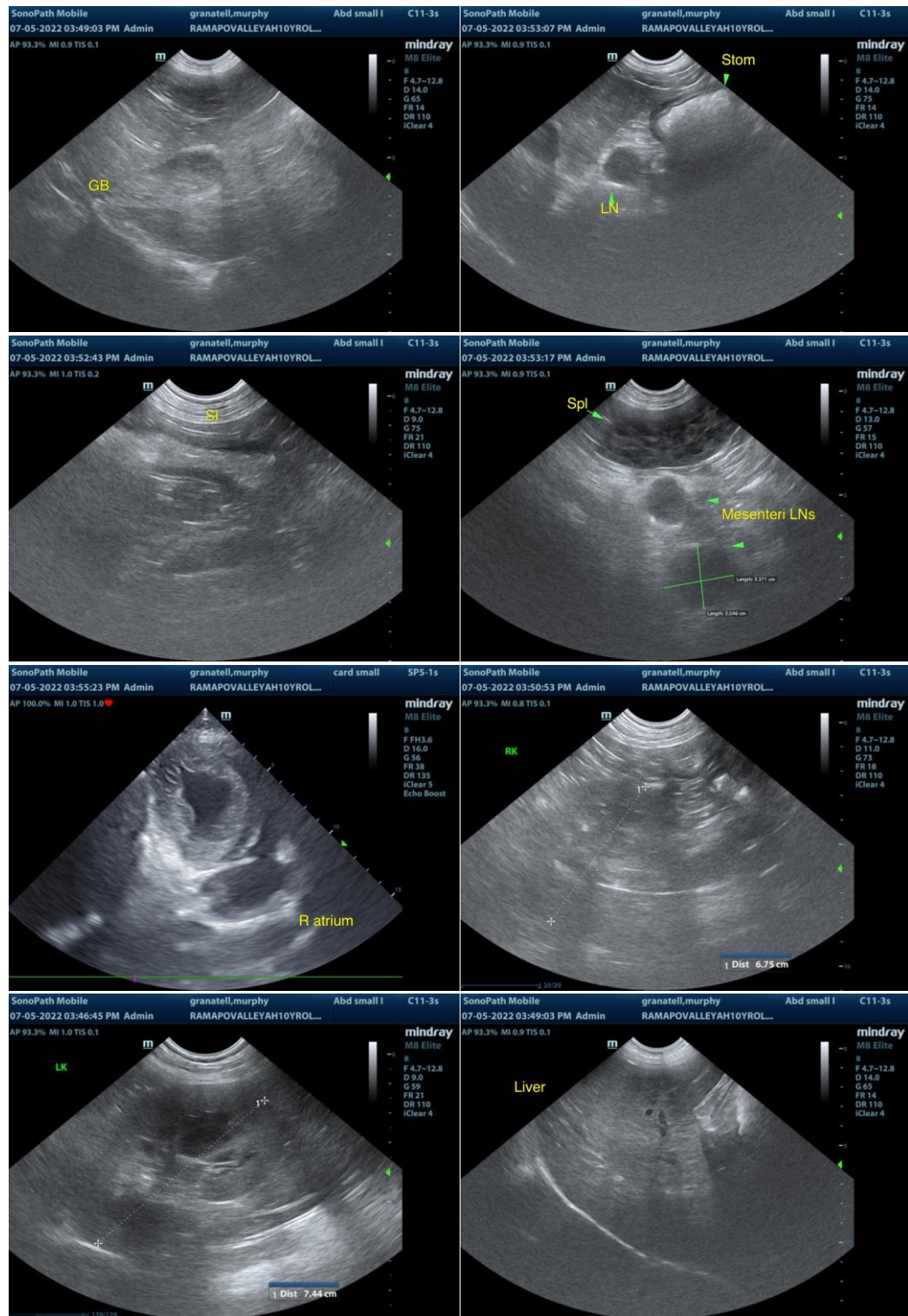
Dr. Gary Duhr

INVOICE

11037ag

DATE

07/05/2022





PATIENT

Murphy Granatell

SPECIES

Canine

BREED

Golden Retriever

SEX

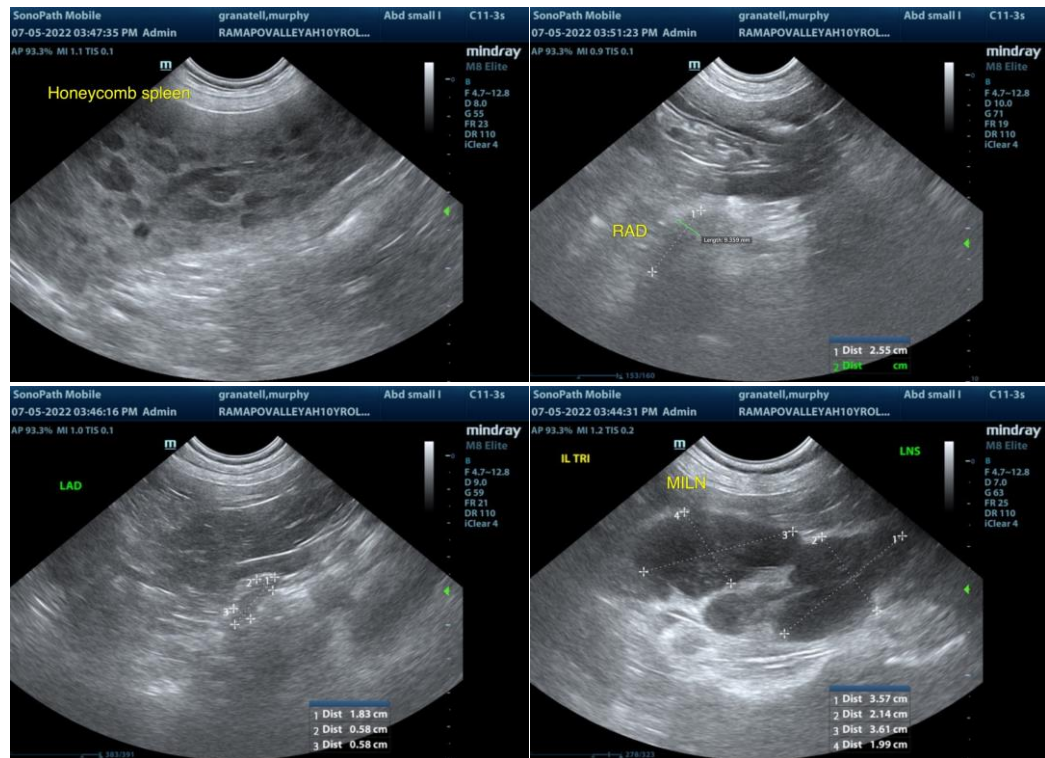
MN

AGE

10 yr

WEIGHT

85 lb



INTERPRETED BY

R. McKenzie Daniel,
DVM, DABVP
(Canine and Feline)

IMAGING PERFORMED BY

Kelly Vazquez

HOSPITAL NAME

Ramapo Valley
Animal Hospital

REFERRING VET

Dr. Gary Duhr

INVOICE

11037ag

DATE

07/05/2022

The information and recommendations provided are based on the images presented by the referring veterinarian/sonographer. No evaluation can be communicated regarding pathology that was not visible in the image/video clips provided.

Thank you for this referral. If the clinical or image interpretation does not parallel your findings or if I can be of any further assistance please contact me.

R. McKenzie Daniel, DVM, DABVP (Canine / Feline Practice)

info@SonoPath.com