



**PATIENT**

**PRESENTING CLINICAL SIGNS**

Mang Roche

History: Hx of PU sx/ pos PU hx of UTI, for the past few weeks Owner been noticed, loosing weight, on/off vomiting, loss stool. decreased appetite.

**SPECIES**

Abnormal PE/Chem/CBC/UA Results: Possible mass on mid abdomen, loss weight, muscle waste. BW/UA not performed.

Feline

**ULTRASONOGRAPHIC EXAMINATION OF THE ABDOMEN**

**BREED**

**Urinary System**

DSH

The urinary bladder, trigone, cystourethral junction, and visible pelvic urethra exhibited normal thickness and tone. Primarily anechoic urine was present in the lumen. Mild nondependent particulate sediment was present without evidence of calculus formation. The ureteral papillae were normal. The ureters were not visible which is normal. No evidence of inflammatory or neoplastic mural changes were noted.

**SEX**

MN

**AGE**

11 yr

Normal size and margination were present in the kidneys. A normal 1:3 cortex / medulla ratio and normal corticomedullary definition were maintained. Uniform increased cortex echogenicity with mild loss of corticomedullary border demarcation was noted. The left kidney measured 4.0 cm in length. The right kidney measured 3.9 cm in length.

The area of the aortic trifurcation was free of pathology.

**WEIGHT**

7.5 lb

**Adrenal Glands**

The left adrenal gland was uniform in size and contour with a uniformly hypoechoic parenchyma. The left adrenal gland measured 0.34 cm width. The right adrenal gland was uniform in size and contour with a uniformly hypoechoic parenchyma. The right adrenal gland measured 0.34 cm width.

**INTERPRETED BY**

R. McKenzie Daniel,  
DVM, DABVP  
(Canine and Feline)

**Spleen**

The spleen exhibited mildly subnormal size measuring 0.49 cm in width at the level of the hilus with a mild heterogeneous parenchyma. The capsule was smooth and regular without apparent expansion. The splenic vasculature at the hilus was normal in volume with no evidence of congestion or thrombosis. No masses or nodules were noted.

**IMAGING PERFORMED BY**

Jose

**Liver**

**HOSPITAL NAME**

Animal Clinic of  
Queens

The liver was subjectively normal in size, structure, and contour. The liver parenchyma was mildly nonuniform and hypoechoic to the spleen with a moderate coarse echotexture and subjective mild to benign parenchymal remodeling. The hepatic and portal vasculature were normal in appearance without signs of congestion.

**REFERRING VET**

Dr. Mucera

The gallbladder was non-distended in size with thin walls and primarily anechoic luminal content with mild luminal debris. The cystic and common bile ducts were normal.

**Gastrointestinal**

**INVOICE**

11018ag

The stomach exhibited moderate distention with retained nonshadowing echogenic fluid and chyme. No overt evidence of mechanical pyloric outflow obstruction was noted yet potential for mechanical obstruction cannot be definitively excluded.

**DATE**

07/03/2022

The small intestine presented segmental variable yet moderate hypoechoic mural hypertrophy with loss of discernable wall layering. The thickened intestinal wall measured up to 0.66 cm in width.



**PATIENT**

Normal visible colon wall layers were present with apparent formed feces in lumen.

Mang Roche

**Pancreas**

**SPECIES**

The parenchyma of the left limb, body and right limb of the pancreas presented isoechoic to the adjacent omental fat. A normal curvilinear capsule contour of the pancreas was present. The visible pancreatic duct was normal. No signs of active inflammation or neoplastic disease was evident.

Feline

**Free Abdomen**

**BREED**

Large asymmetrical nonhomogeneous hypoechoic mass present in the mid abdomen measuring approximately 6 cm x 5 cm. Concurrent hypoechoic to swollen regional mesenteric lymphadenopathy was observed, an example of a swollen mesenteric node measured 2.2 cm x 1.9 cm. Small pockets of scant peritoneal free fluid were noted.

DSH

**SEX**

MN

**ULTRASONOGRAPHIC FINDINGS**

**AGE**

- Nonhomogeneous hypoechoic mid abdominal mass with regional hypoechoic to swollen peripheral mesenteric lymphadenopathy
- Segmentally thickened small intestine exhibiting decreased mural echogenicity and loss of wall layering
- Moderate retained gastric fluid/chyme
- Bilateral mild chronic renal changes
- Mild urinary bladder sediment

11 yr

**WEIGHT**

7.5 lb

**INTERPRETATION OF THE FINDINGS & FURTHER RECOMMENDATIONS**

**INTERPRETED BY**

R. McKenzie Daniel,  
DVM, DABVP  
(Canine and Feline)

The mid abdominal mass is suspected to be of lymphatic origin given the concurrent regional hypoechoic mesenteric lymphadenopathy although potential for nonspecific omental or nonobvious intestinal origin of the mass cannot be definitively excluded. High grade lymphoma is considered a top differential with segmental small intestinal involvement. Potential for dry form FIP or granulomatous lymphadenopathy/enteropathy is considered less likely. Assuming normal clotting status, an ultrasound guided FNA of the mass +/- peripheral lymph node is warranted for screening cytology and potential oncology consult.

**IMAGING PERFORMED BY**

Jose

A GI panel to include PLI/TLI/Cobalamin/Folate is recommended as well as three view chest radiographs if not already done.

**HOSPITAL NAME**

Animal Clinic of  
Queens

This case does not appear to be surgical.

**REFERRING VET**

Dr. Mucera

**INVOICE**

11018ag

**DATE**

07/03/2022



**PATIENT**

Mang Roche

**SPECIES**

Feline

**BREED**

DSH

**SEX**

MN

**AGE**

11 yr

**WEIGHT**

7.5 lb

**INTERPRETED BY**

R. McKenzie Daniel,  
DVM, DABVP  
(Canine and Feline)

**IMAGING PERFORMED BY**

Jose

**HOSPITAL NAME**

Animal Clinic of  
Queens

**REFERRING VET**

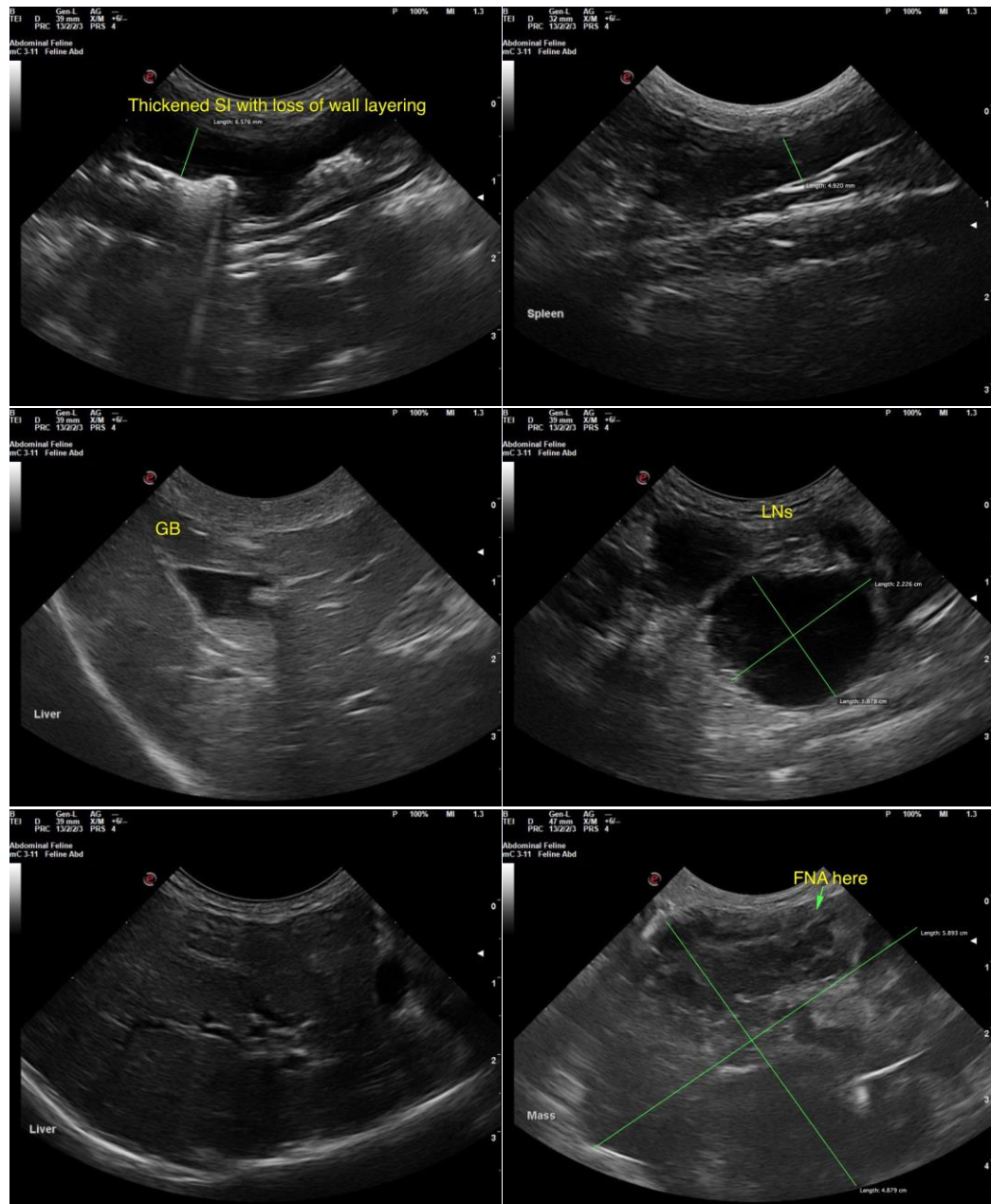
Dr. Mucera

**INVOICE**

11018ag

**DATE**

07/03/2022





**PATIENT**

Mang Roche

**SPECIES**

Feline

**BREED**

DSH

**SEX**

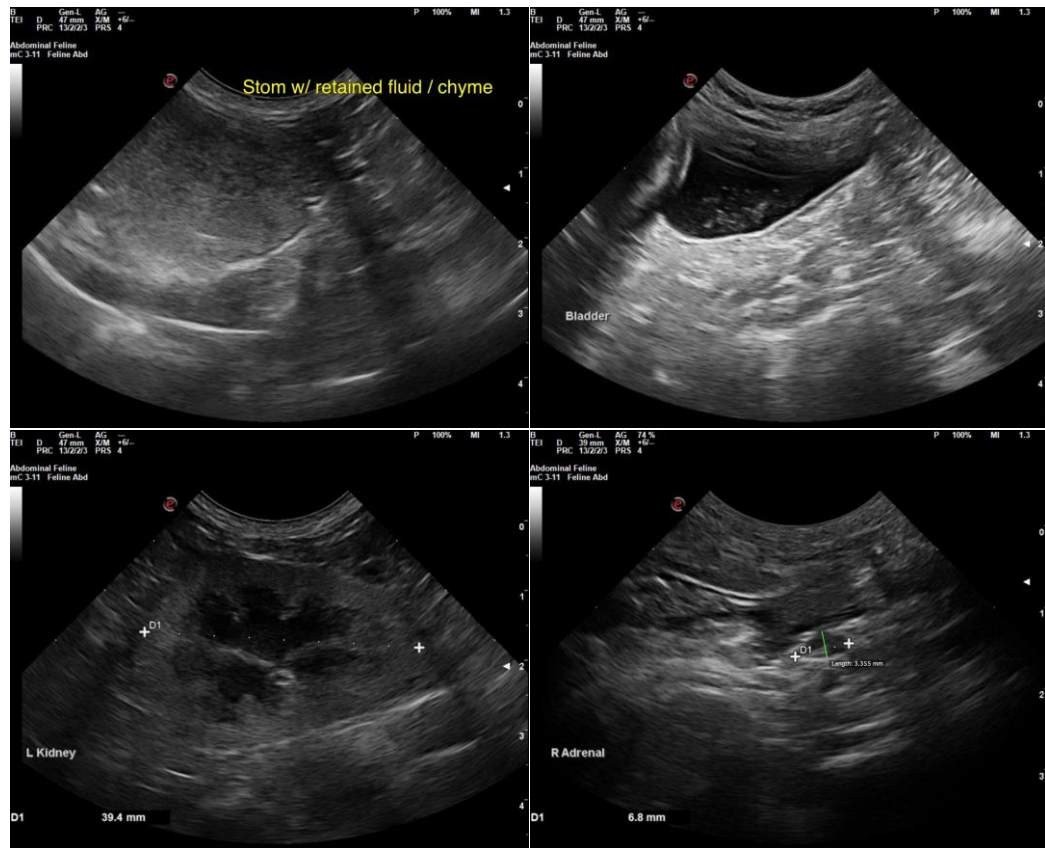
MN

**AGE**

11 yr

**WEIGHT**

7.5 lb



**INTERPRETED BY**

R. McKenzie Daniel,  
DVM, DABVP  
(Canine and Feline)

**IMAGING PERFORMED BY**

Jose

**HOSPITAL NAME**

Animal Clinic of  
Queens

**REFERRING VET**

Dr. Mucera

**INVOICE**

11018ag

**DATE**

07/03/2022

The information and recommendations provided are based on the images presented by the referring veterinarian/sonographer. No evaluation can be communicated regarding pathology that was not visible in the image/video clips provided.

Thank you for this referral. If the clinical or image interpretation does not parallel your findings or if I can be of any further assistance please contact me.

R. McKenzie Daniel, DVM, DABVP (Canine / Feline Practice)

info@SonoPath.com