


**PATIENT**

Jasper Qassis

**PRESENTING CLINICAL SIGNS**

History: Patient with history of heart murmur presents for echo. Needs lumpectomy under general anesthesia for hind toe/foot mass.

**SPECIES**

Feline

**ULTRASONOGRAPHIC EXAMINATION OF THE HEART**
**BREED**

DSH

**SEX**

MN

**AGE**

8yr

**WEIGHT**

16lb

FELINE CARDIAC PARAMETERS	BODY WEIGHT (kg)	HR (BPM)	IVSd (cm)	LVIDd (cm)	LVWd (cm)	FS (%)	EF (%)
NORMAL PARAMETER	-----	150-240	0.3-0.6	1.0-2.1	0.25-0.6	35-67	80-100
PATIENT		127	0.46	1.67	0.46	49.7	84.7
FELINE CARDIAC PARAMETERS	LA/AO (Boon)	LA/AO HEART BASE (Sisson)	LA 2D 4-chamber long axis AS to FW (Sisson) (cm)	LVOT VEL. (m/s)	RVOT VEL. (m/s)	IVRT (m/)	
NORMAL PARAMETER	<1.5	0.88-1.79	0.7-1.7	<1.6	<1.3	40-60	
PATIENT	1.2	1.2	1.2	1.1	0.77		
Adapted from June Boon, Veterinary Echocardiography, 1998 Sisson D et al. JVIM 1991; 5: 232, Jacobs et al. Am J Vet Res 1985; 46:1705							

**Cardiac Presentation**

The echocardiogram in this patient demonstrated normal left atrial size based on 3 separate LA measurements. The cranial and caudal mitral valve leaflets presented normal linear structure and kinetics. The left ventricle presented normal thicknesses with linear contour and was not dilated nor restricted. The myocardium presented normal echogenicity without subjective evidence of significant fibrotic or ischemic disease. Contractility of the ventricular walls was adequate and in normal range for this patient evidenced by the fractional shortening measurement and subjective evaluation of the different regions and angles of the myocardium. The left ventricular outflow tract demonstrated normal laminar flow and subjective structural integrity. The right atrium and auricle revealed normal size, structure and content. No evidence of masses was noted or chamber overload. Tricuspid valvular assessment demonstrated adequate linear morphology and kinetics. The right ventricle was of normal size (1/3 diameter of LV), chordae structure, myocardial echogenicity and thickness. Pulmonic tract assessment revealed normal valve structure, laminar flow, and diameter (approx. 1:1 pa/ao ratio). No visible pericardial or free pleura fluid was noted or extra cardiac pathology in the visible planes. The cranial mediastinum and pericardial regions were free of masses in the visible window.

**INTERPRETED BY**

 R. McKenzie Daniel,  
 DVM, DABVP  
 (Canine and Feline)

**IMAGING PERFORMED BY**

Kelly Vazquez

**HOSPITAL NAME**

 Bergen Passaic  
 Animal Hospital

**REFERRING VET**

Dr. Spitz

**ULTRASONOGRAPHIC FINDINGS**

- Normal echocardiogram

**INVOICE**

11225ag

**INTERPRETATION OF THE FINDINGS & FURTHER RECOMMENDATIONS**

No evidence of structural or functional cardiomyopathy in this study. Assuming no evidence of volume changes i.e. dehydration or anemia, a benign physiologic or flow murmur is likely. The hemodynamic effects of the murmur appear to be minimal. No indication for cardiac medications. No anesthetic

**DATE**

07/29/2022



**PATIENT**

Jasper Qassis

contraindications based on this study. Conservative monitoring of the murmur is recommended with recheck echocardiogram suggested in 6-12 months, sooner if clinical signs arise or if murmur intensity increases.

**SPECIES**

Feline

**BREED**

DSH

**SEX**

MN

**AGE**

8yr

**WEIGHT**

16lb

**INTERPRETED BY**

R. McKenzie Daniel,  
DVM, DABVP  
(Canine and Feline)

**IMAGING PERFORMED BY**

Kelly Vazquez

**HOSPITAL NAME**

Bergen Passaic  
Animal Hospital

**REFERRING VET**

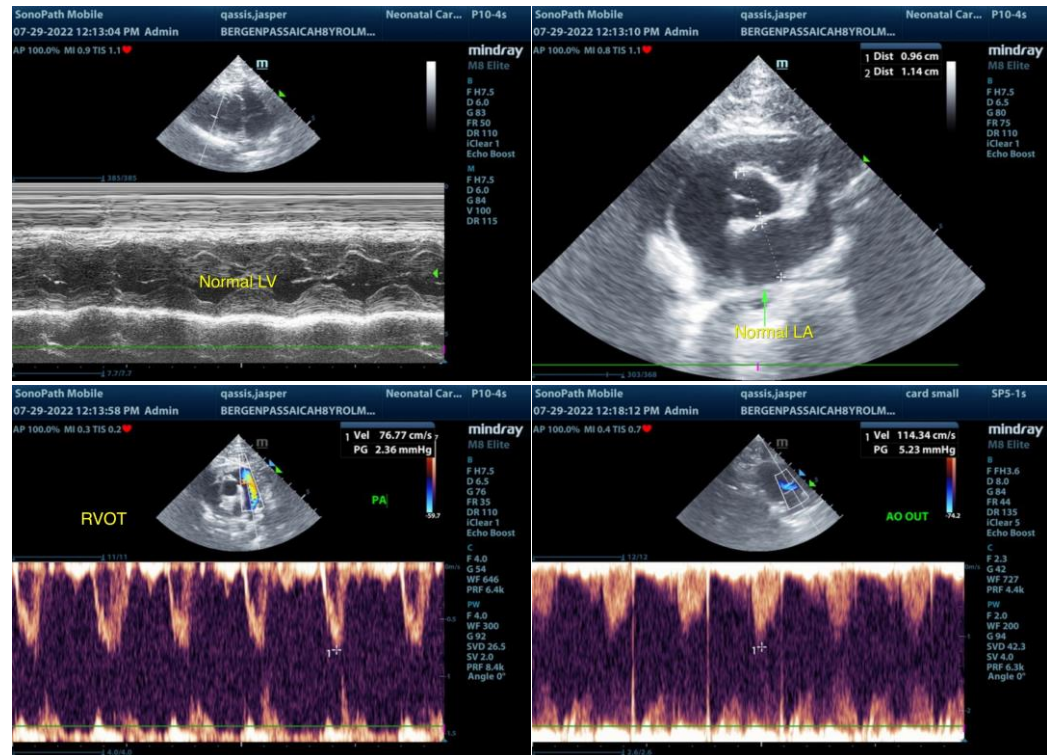
Dr. Spitz

**INVOICE**

11225ag

**DATE**

07/29/2022



The information and recommendations provided are based on the images presented by the referring veterinarian/sonographer. No evaluation can be communicated regarding pathology that was not visible in the image/video clips provided.

Thank you for this referral. If the clinical or image interpretation does not parallel your findings or if I can be of any further assistance please contact me.

R. McKenzie Daniel, DVM, DABVP (Canine / Feline Practice)

info@SonoPath.com