



PATIENT

Pearl Zuniga

PRESENTING CLINICAL SIGNS

MCT on L hip. Discussed removal +/- staging. O elects for staging prior to removal. Has been present for 6 years.

SPECIES

Canine

Abnormal PE/Chem/CBC/UA Results: CBC/Chem/T4/UA 5/2/23 - NSF

ULTRASONOGRAPHIC EXAMINATION OF THE ABDOMEN

BREED

Catahoula Leopard Dog Mix

Urinary System

The urinary bladder presented uniformly mildly thickened urinary bladder wall isoechoic to the adjacent normal urinary bladder wall. The luminal margin of the thickened urinary bladder wall was mildly asymmetrical in contour. Urinary bladder wall thickness measured 0.46 cm. Mineralization or echogenic foci within the thickened areas of urinary bladder wall was not present. The urinary bladder, trigone, cystourethral junction, and visible pelvic urethra exhibited normal tone. Anechoic urine was present in the lumen with moderate to marked non-dependent to dependent variably hyperechoic sediment and sand. The ureteral papillae were normal. The ureters were not visible which is normal.

SEX

FS

AGE

8yr

Normal size and margination were present in the kidneys. A normal 1:3 cortex / medulla ratio and normal corticomedullary definition were maintained. The echogenicity of the cortex was similar to or slightly less than normal liver parenchyma while the medulla echogenicity was hypoechoic to the cortex with no evidence of pelvic dilation. The left kidney measured 5.6 cm in length. The right kidney measured 5.7 cm in length.

WEIGHT

32.6

The area of the iliac trifurcation was free of pathology including no evidence of medial, iliac or sublumbar lymphadenopathy or masses.

INTERPRETED BY

R. McKenzie Daniel,
DVM, DABVP
(Canine and Feline)

Adrenal Glands

The left adrenal gland was uniform in size and contour with a uniformly hypoechoic parenchyma. The left adrenal gland measured 0.43 cm width at the caudal pole and 1.9 cm length. The right adrenal gland was uniform in size and contour with a uniformly hypoechoic parenchyma. The right adrenal gland measured 0.41 cm width at the caudal pole and 2.0 cm length.

IMAGING PERFORMED BY

Graham Sager-Gellerman, DVM

Spleen

The spleen exhibited a finely textured and homogenous parenchyma which was hyperechoic to the liver and renal cortical parenchyma. The capsule was smooth and regular without apparent expansion. The splenic vasculature at the hilus was normal in volume with no evidence of congestion or thrombosis. Acute to chronic inflammatory, neoplastic, or benign parenchyma changes were not noted.

HOSPITAL NAME

Back Bay Veterinary Clinic

Liver/Gallbladder

REFERRING VET

Katherine Wheeler,
DVM

The liver was subjectively normal in size, structure, and contour. The liver parenchyma was uniform and hypoechoic to the spleen with a mild coarse echotexture. Normal vascular volume. The hepatic and portal vasculature were normal in appearance without signs of congestion. The gallbladder was non-distended in size with thin walls and primarily anechoic luminal content. The cystic and common bile ducts were normal.

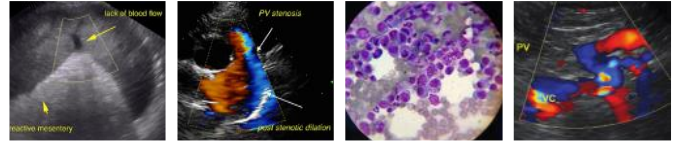
INVOICE

14431ag

Gastrointestinal

DATE

07/28/2023



PATIENT

Pearl Zuniga

The stomach presented intact wall layering with a normal wall layer ratio. The lumen of the stomach contained mild to moderate echogenic non-shadowing ingesta with no signs of ileus, obstruction or foreign material.

SPECIES

Canine

The small intestine presented intact wall layering with 1:3 muscularis/mucosa ratio. The lumen of the small intestine was empty with no signs of ileus, obstruction or foreign material.

Normal visible colon wall layers were present with apparent formed feces in lumen.

BREED

Catahoula Leopard
Dog Mix

Pancreas

The parenchyma of the left limb, body and right limb of the pancreas presented isoechoic to the adjacent omental fat. A normal curvilinear capsule contour of the pancreas was present. The visible pancreatic duct was normal. No signs of active inflammation or neoplastic disease was evident.

SEX

FS

Free Abdomen

No omental masses, overt lymphadenopathy or peritoneal effusion was present.

AGE

8yr

ULTRASONOGRAPHIC FINDINGS

- Mild cystitis pattern with moderate to marked urine sediment/sand.
- Normal bilateral kidneys.
- Sonographically normal liver and spleen.
- Normal GI tract with mild gastric ingesta-ingesta sonographically consistent with food.

WEIGHT

32.6

INTERPRETATION OF THE FINDINGS & FURTHER RECOMMENDATIONS

No evidence of intra-abdominal primary neoplastic or metastatic criteria. Recheck UA and C/S on a sterile urine sample is recommended. A urinary diet may be considered. No contraindications to surgery. Sonographic monitoring of the abdominal cavity based on oncology recommendations is suggested.

INTERPRETED BY

R. McKenzie Daniel,
DVM, DABVP
(Canine and Feline)

**IMAGING
PERFORMED BY**

Graham Sager-
Gellerman, DVM

HOSPITAL NAME

Back Bay Veterinary
Clinic

REFERRING VET

Katherine Wheeler,
DVM

INVOICE

14431ag

DATE

07/28/2023



PATIENT

Pearl Zuniga

SPECIES

Canine

BREED

Catahoula Leopard
Dog Mix

SEX

FS

AGE

8yr

WEIGHT

32.6

INTERPRETED BY

R. McKenzie Daniel,
DVM, DABVP
(Canine and Feline)

**IMAGING
PERFORMED BY**

Graham Sager-
Gellerman, DVM

HOSPITAL NAME

Back Bay Veterinary
Clinic

REFERRING VET

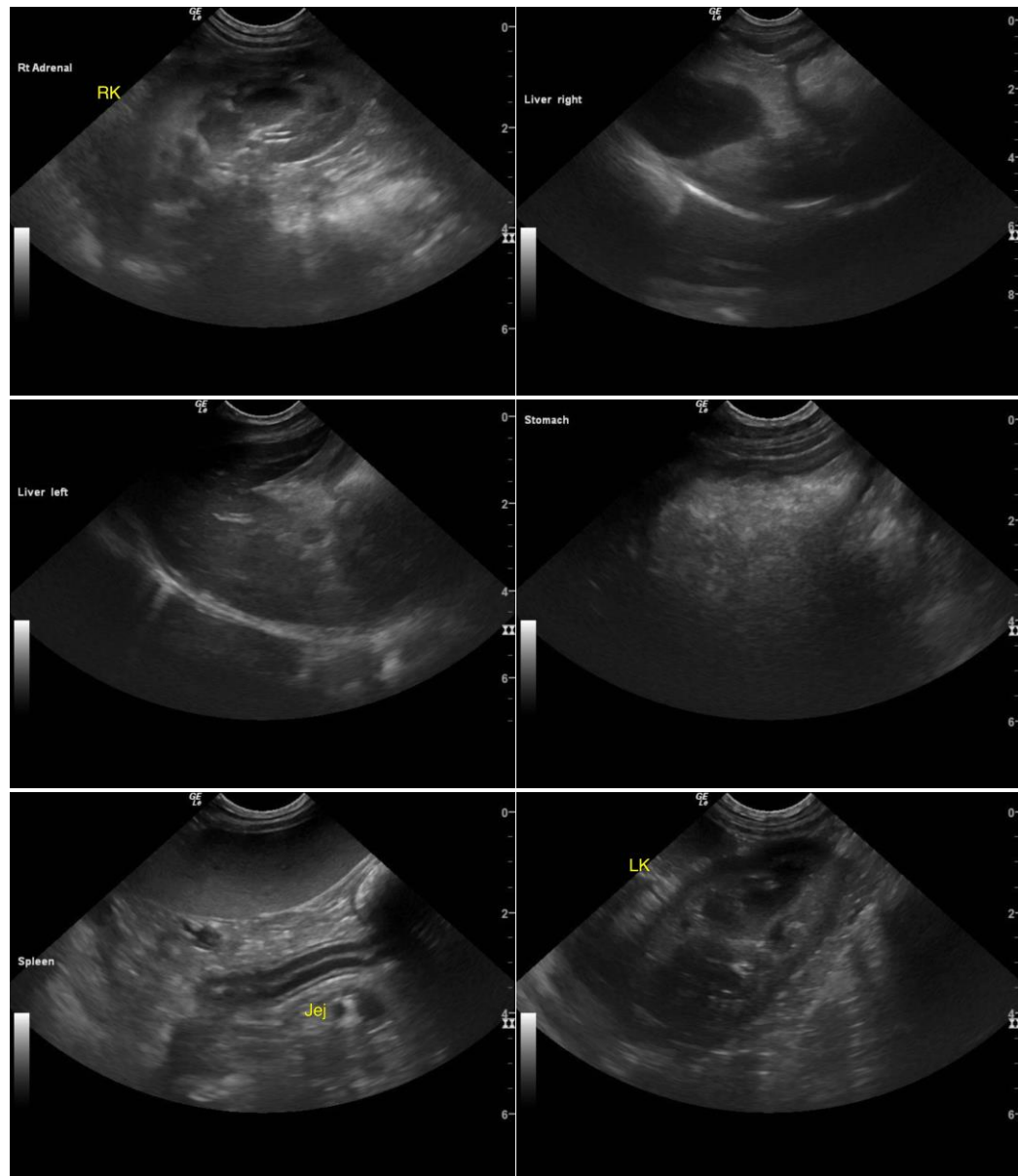
Katherine Wheeler,
DVM

INVOICE

14431ag

DATE

07/28/2023





PATIENT

Pearl Zuniga

SPECIES

Canine

BREED

Catahoula Leopard
Dog Mix

SEX

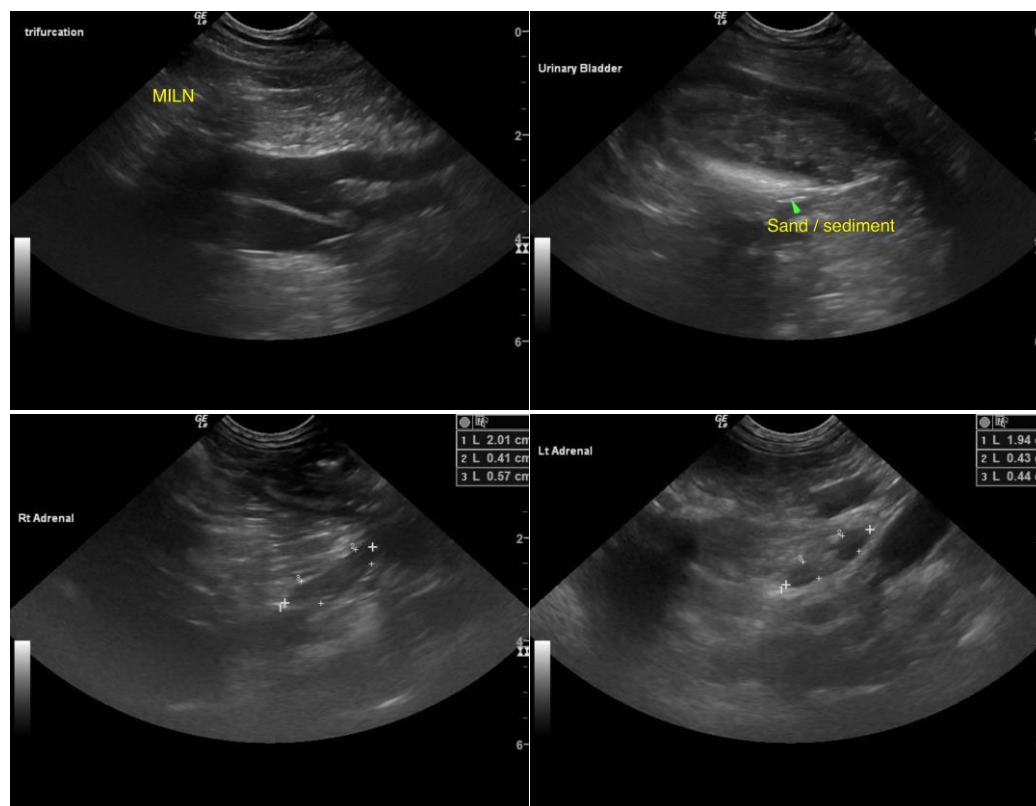
FS

AGE

8yr

WEIGHT

32.6



INTERPRETED BY

R. McKenzie Daniel,
DVM, DABVP
(Canine and Feline)

**IMAGING
PERFORMED BY**

Graham Sager-
Gellerman, DVM

HOSPITAL NAME

Back Bay Veterinary
Clinic

REFERRING VET

Katherine Wheeler,
DVM

INVOICE

14431ag

DATE

07/28/2023

The information and recommendations provided are based on the images presented by the referring veterinarian/sonographer. No evaluation can be communicated regarding pathology that was not visible in the image/video clips provided.

Thank you for this referral. If the clinical or image interpretation does not parallel your findings or if I can be of any further assistance, please contact me.

R. McKenzie Daniel, DVM, DABVP (Canine/Feline Practice)
info@sonopath.com