



PATIENT

Shadow Fax Lloyd

SPECIES

Feline

BREED

Ragdoll

SEX

MN

AGE

10

WEIGHT

11.8

INTERPRETED BY

R. McKenzie Daniel,
DVM, DABVP
(Canine and Feline)

IMAGING PERFORMED BY

Sr. Saum Hadi

HOSPITAL NAME

Bethany Family Pet
Clinic

REFERRING VET

Dr. Saum Hadi

INVOICE

16574

DATE

7/27/22

PRESENTING CLINICAL SIGNS

P has been vomiting with increased frequency in the last few months. Mild weight loss from 12.2- >11.8 lbs.

Abnormal PE/Chem/CBC/UA Results: NSF on Chem 10/CBC/PE.

ULTRASONOGRAPHIC EXAMINATION OF THE ABDOMEN

Urinary System

The urinary bladder, trigone, cystourethral junction, and visible pelvic urethra to a depth of 2.0 cm exhibited normal thickness and tone. Primarily anechoic urine was present in the lumen. Mild nondependent particulate sediment was present without evidence of calculus formation. The ureteral papillae were normal. The ureters were not visible which is normal. No evidence of inflammatory or neoplastic mural changes were noted.

The residual prostate was symmetrically normal in size with uniform parenchyma and slight coarse echotexture measuring – cm in diameter.

The area of the aortic trifurcation was free of pathology.

Normal size and margination were present in the kidneys. A normal 1:3 cortex / medulla ratio was maintained. The medulla and cortices were uniform in texture with some increased echogenicity and mild loss of corticomedullary symmetry and definition expected for the age of the patient. No evidence of pelvic dilation was present. The left kidney measured 3.9 cm in length. The right kidney measured 4.4 cm in length.

Adrenal Glands

The left adrenal gland was uniform in size and contour with a uniformly hypoechoic parenchyma. The left adrenal gland measured – cm width at the caudal pole and – cm width at the cranial pole. The right adrenal gland was uniform in size and contour with a uniformly hypoechoic parenchyma. The right adrenal gland measured – cm width at the caudal pole and – cm width at the cranial pole.

Spleen

The spleen exhibited a finely textured and homogenous parenchyma which was hyperechoic to the liver and renal cortical parenchyma. The capsule was smooth and regular without apparent expansion. The splenic vasculature at the hilus was normal in volume with no evidence of congestion or thrombosis. Acute to chronic inflammatory, neoplastic, or benign parenchyma changes were not noted.

Liver/ Gallbladder

The liver was subjectively normal in size, structure, and contour. The liver parenchyma was uniform and hypoechoic to the spleen with a mild coarse echotexture. The hepatic and portal vasculature were normal in appearance without signs of congestion. The gallbladder was non-distended in size with thin walls and primarily anechoic luminal content. The cystic and common bile ducts were normal.

Gastrointestinal



PATIENT

Shadow Fax Lloyd

The stomach presented intact wall layering with a normal wall layer ratio. The lumen of the stomach was nondistended with mild luminal gas and without evidence of retained ingesta, fluid or foreign material. The pylorus wall measured 0.26 cm. No evidence of obstructive pyloric mural pathology.

SPECIES

Feline

The small intestine presented intact wall layering with 1:3 muscularis/mucosa ratio. The lumen of the small intestine was empty with no signs of ileus, obstruction, or foreign material. The jejunum wall measured 0.20 cm. The ileocolic wall measured 0.33 cm.

BREED

Ragdoll

Normal visible colon wall layers were present with apparent formed feces in lumen.

SEX

MN

The left pancreatic limb, caudal to the gastric body, exhibited normal size and contour with subtle hypoechoic parenchyma compared to adjacent omentum.

AGE

10

Free Abdomen

No omental masses, lymphadenopathy or peritoneal free fluid was present.

WEIGHT

11.8

ULTRASONOGRAPHIC FINDINGS

- Sonographically unremarkable GI tract
- Mildly hypoechoic left pancreas
- Age-related kidneys
- Mild urinary bladder sediment

INTERPRETED BY

R. McKenzie Daniel,
DVM, DABVP
(Canine and Feline)

INTERPRETATION OF THE FINDINGS & FURTHER RECOMMENDATIONS

No evidence of significant abdominal visceral pathology, specifically GI or pancreatic pathology, as an overt cause of the patients increased vomiting. The pancreatic presentation may suggest some degree of low grade to mild pancreatitis. This potential may be considered, if evidence of cranial abdominal or subxiphoid discomfort on palpation. Potential for dietary intolerance/food hypersensitivity, occult parasitism (if the patient is indoor/outdoor) or structurally insignificant GI disease possible. Further assessment may include a GI panel to include PLI/TLI/Cobalamin/Folate is recommended. Three view chest radiographs are suggested to rule out occult thoracic or esophageal pathology, as a contributing factor to the clinical signs and patients mild weight loss.

IMAGING PERFORMED BY

Sr. Saum Hadi

HOSPITAL NAME

Bethany Family Pet
Clinic

REFERRING VET

Dr. Saum Hadi

Empirical GI supportive care with potential for prophylactic deworming if clinically indicated, as well as hydrolyzed diet trial would be reasonable.

INVOICE

16574

DATE

7/27/22



PATIENT

Shadow Fax Lloyd

SPECIES

Feline

BREED

Ragdoll

SEX

MN

AGE

10

WEIGHT

11.8

INTERPRETED BY

R. McKenzie Daniel,
DVM, DABVP
(Canine and Feline)

IMAGING PERFORMED BY

Sr. Saum Hadi

HOSPITAL NAME

Bethany Family Pet
Clinic

REFERRING VET

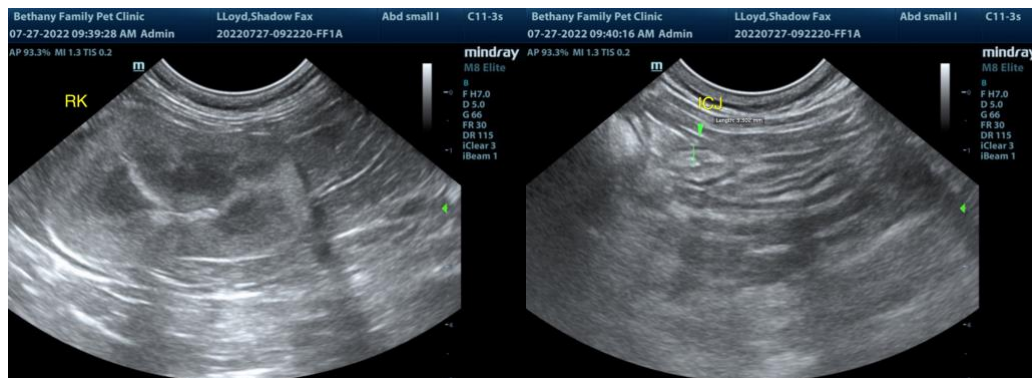
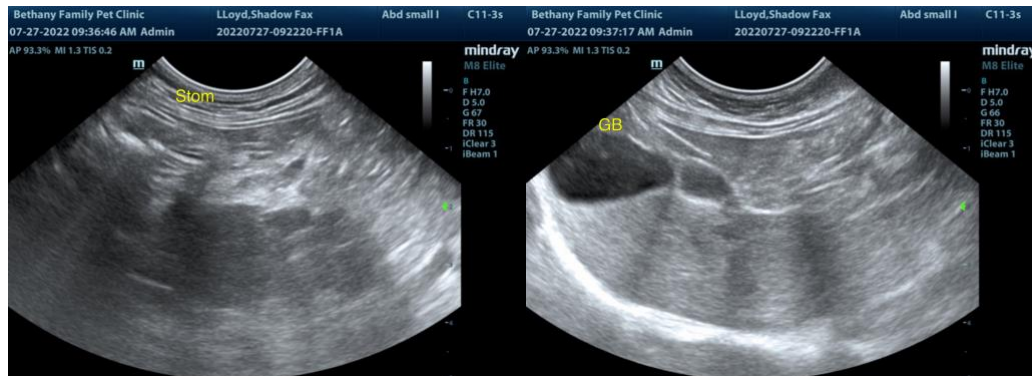
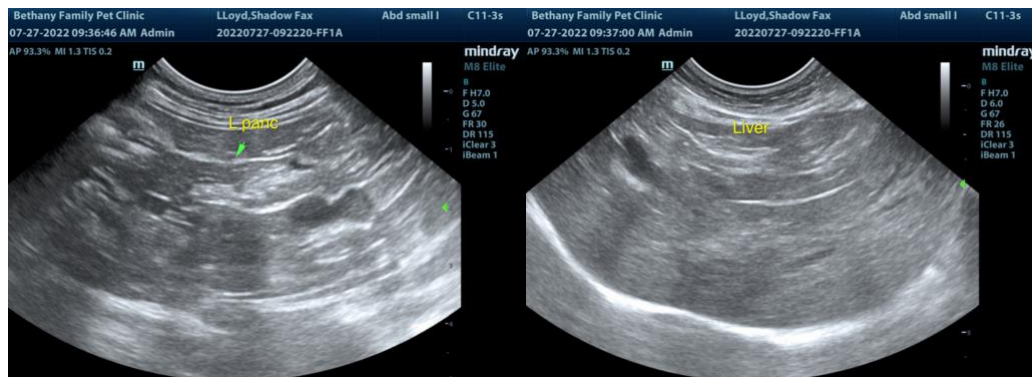
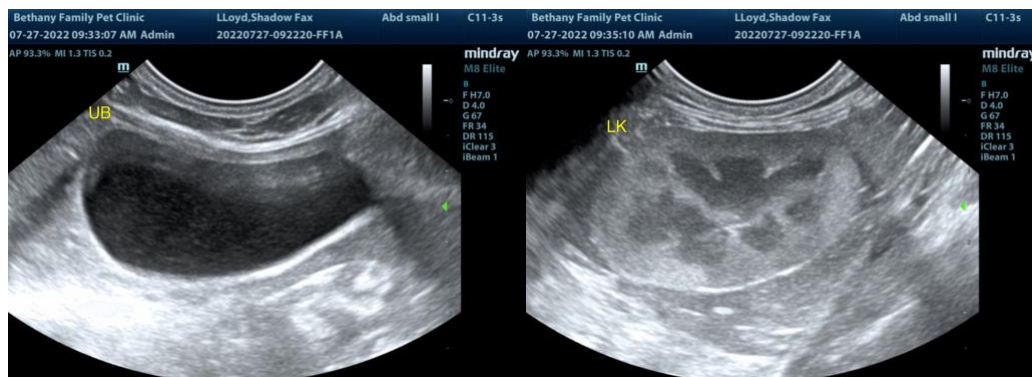
Dr. Saum Hadi

INVOICE

16574

DATE

7/27/22





PATIENT

Shadow Fax Lloyd

SPECIES

Feline

BREED

Ragdoll

SEX

MN

AGE

10

WEIGHT

11.8

INTERPRETED BY

R. McKenzie Daniel,
DVM, DABVP
(Canine and Feline)

IMAGING PERFORMED BY

Sr. Saum Hadi

HOSPITAL NAME

Bethany Family Pet
Clinic

REFERRING VET

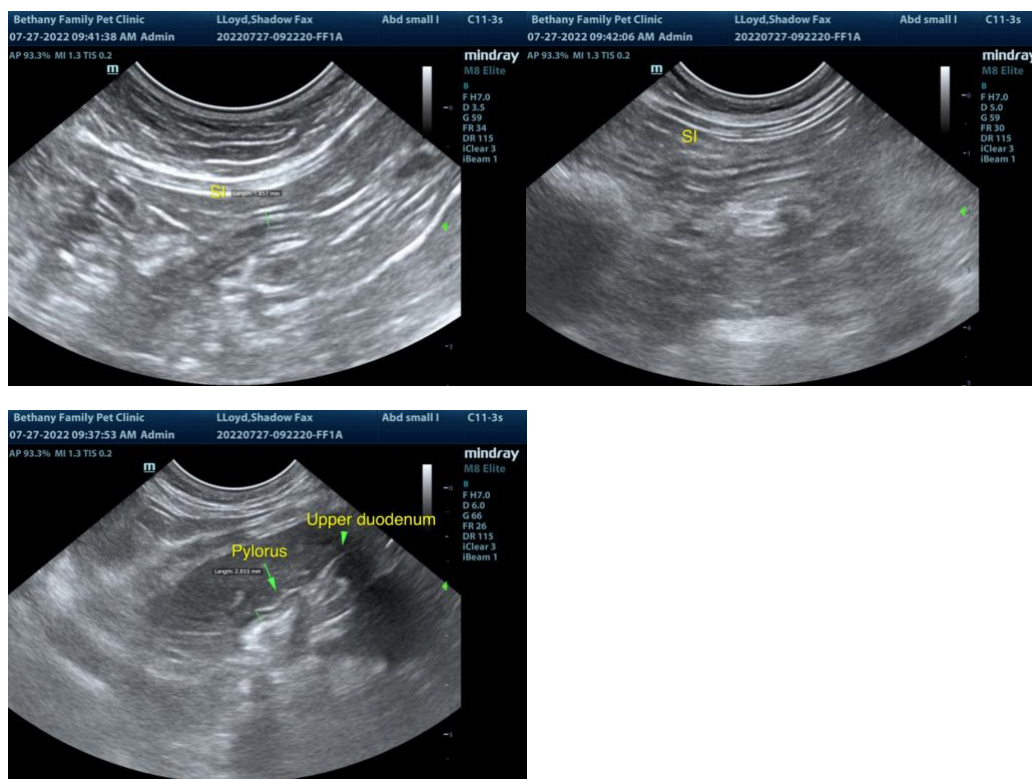
Dr. Saum Hadi

INVOICE

16574

DATE

7/27/22



The information and recommendations provided are based on the images presented by the referring veterinarian/sonographer. No evaluation can be communicated regarding pathology that was not visible in the image/video clips provided.

Thank you for this referral. If the clinical or image interpretation does not parallel your findings or if I can be of any further assistance please contact me.

R. McKenzie Daniel, DVM, DABVP (Canine / Feline Practice)
info@SonoPath.com