



PATIENT

Milo Facciola

SPECIES

Feline

BREED

Siberian

SEX

M/N

AGE

3

WEIGHT

13.2

INTERPRETED BY

R. McKenzie Daniel,
DVM, DABVP
(Canine and Feline)

IMAGING PERFORMED BY

Dr. Sharkaway

HOSPITAL NAME

Kew Gardens AH

REFERRING VET

Dr. Sharkaway

INVOICE

17405

DATE

7/26/23

PRESENTING CLINICAL SIGNS

Heart murmur 1 out of 6

Abnormal PE/Chem/CBC/UA Results: Previous echocardiogram -trace tricuspid regurgitation

ULTRASONOGRAPHIC EXAMINATION OF THE HEART

FELINE CARDIAC PARAMETERS	BODY WEIGHT (kg)	HR (BPM)	IVSd (cm)	LVIDd (cm)	LVWd (cm)	FS (%)	EF (%)
NORMAL PARAMETER	-----	150-240	0.3-0.6	1.0-2.1	0.25-0.6	35-67	80-100
PATIENT		NM	0.5	1.53	0.5	50	85
FELINE CARDIAC PARAMETERS	LA/AO (Boon)	LA/AO HEART BASE (Sisson)	LA 2D 4-chamber long axis AS to FW (Sisson) (cm)	LVOT VEL. (m/s)	RVOT VEL. (m/s)	IVRT (m/)	
NORMAL PARAMETER	<1.5	0.88-1.79	0.7-1.7	<1.6	<1.3	40-60	
PATIENT		1.3	1.2		0.78	NM	
Adapted from June Boon, Veterinary Echocardiography, 1998 Sisson D et al. JVIM 1991; 5: 232, Jacobs et al. Am J Vet Res 1985; 46:1705							

Cardiac Presentation

The echocardiogram in this patient demonstrated normal **left atrial** size based on 3 separate LA measurements. The cranial and caudal **mitral** valve leaflets presented normal linear structure and kinetics. No overt MR was noted on Doppler. The **left ventricle** presented normal thicknesses with linear contour and was not dilated nor restricted. The **myocardium** presented normal echogenicity without subjective evidence of significant fibrotic or ischemic disease. **Contractility** of the ventricular walls was adequate and in normal range for this patient evidenced by the fractional shortening measurement and subjective evaluation of the different regions and angles of the myocardium. The **left ventricular outflow** tract demonstrated normal laminar flow and subjective structural integrity. The **right atrium** and auricle revealed normal size, structure and content. No evidence of masses was noted or chamber overload. **Tricuspid** valvular assessment demonstrated adequate linear morphology and kinetics. Minor TR was present on Doppler. The **right ventricle** was of normal size (1/3 diameter of LV), chordae structure, myocardial echogenicity and thickness. **Pulmonic** tract assessment revealed normal valve structure, laminar flow, and diameter (approx. 1:1 pa/ao ratio). No visible **pericardial** or free pleura fluid was noted or extra cardiac pathology in the visible planes. The cranial **mediastinum and pericardial regions** were free of masses in the visible window.

ULTRASONOGRAPHIC FINDINGS

- Normal echocardiogram
- Mild TR



PATIENT

Milo Facciola

SPECIES

Feline

BREED

Siberian

SEX

M/N

AGE

3

WEIGHT

13.2

INTERPRETED BY

R. McKenzie Daniel,
DVM, DABVP
(Canine and Feline)

IMAGING PERFORMED BY

Dr. Sharkaway

HOSPITAL NAME

Kew Gardens AH

REFERRING VET

Dr. Sharkaway

INVOICE

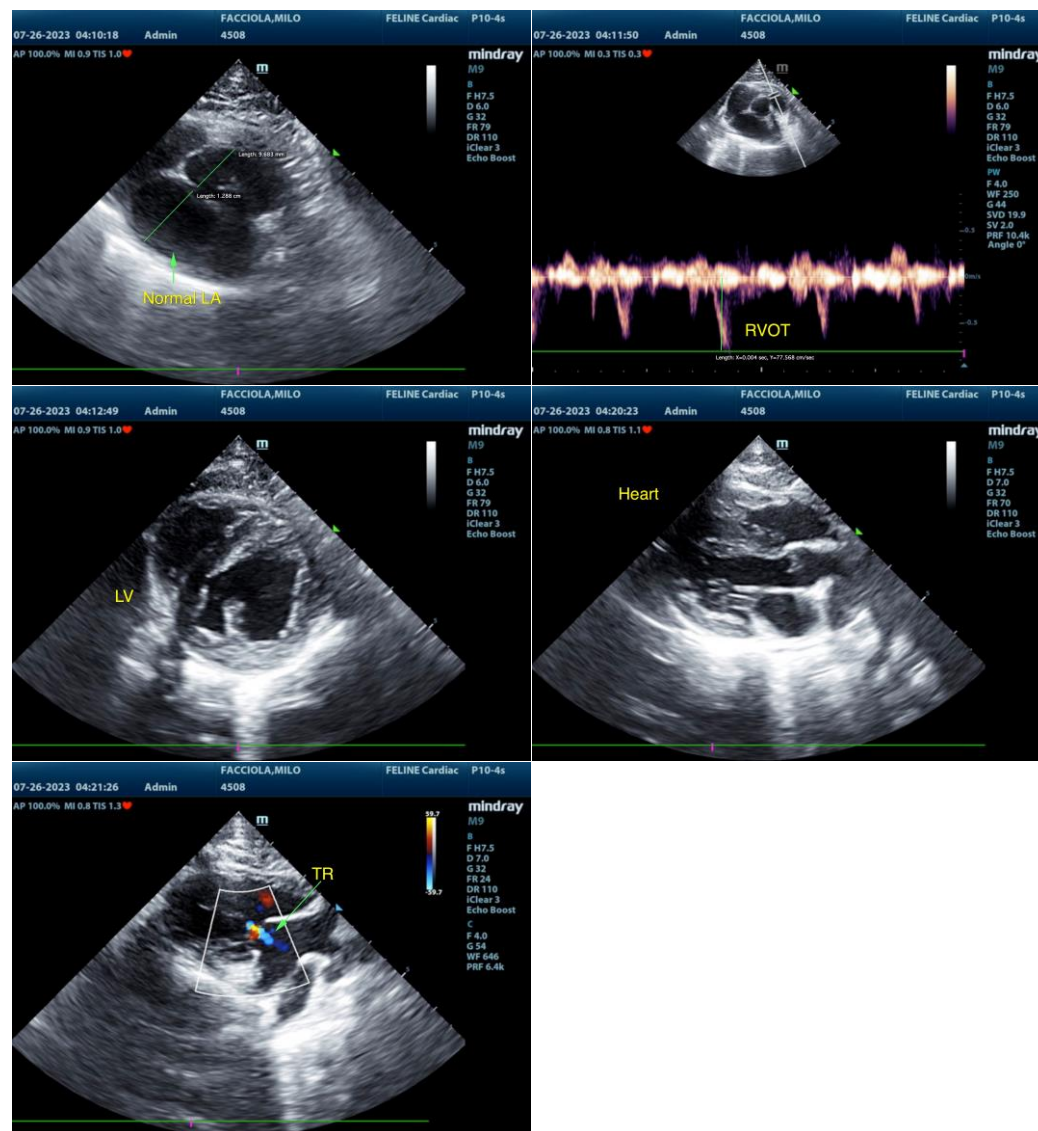
17405

DATE

7/26/23

INTERPRETATION OF THE FINDINGS & FURTHER RECOMMENDATIONS

There was no evidence of structural or functional cardiomyopathy, including no clinical issues such as HCM criteria, clinical pulmonary hypertension, left or right heart chamber enlargement, or LV systolic dysfunction. There is no indication for cardiac medications.



The information and recommendations provided are based on the images presented by the referring veterinarian/sonographer. No evaluation can be communicated regarding pathology that was not visible in the image/video clips provided.

Thank you for this referral. If the clinical or image interpretation does not parallel your findings or if I can be of any further assistance, please contact me.



PATIENT

Milo Facciola

R. McKenzie Daniel, DVM, DABVP (Canine/Feline Practice)

info@sonopath.com

SPECIES

Feline

BREED

Siberian

SEX

M/N

AGE

3

WEIGHT

13.2

INTERPRETED BY

R. McKenzie Daniel,
DVM, DABVP
(Canine and Feline)

**IMAGING
PERFORMED BY**

Dr. Sharkaway

HOSPITAL NAME

Kew Gardens AH

REFERRING VET

Dr. Sharkaway

INVOICE

17405

DATE

7/26/23