



**PATIENT**

Jasmine Finch

**SPECIES**

Feline

**BREED**

Domestic Long Hair

**SEX**

FS

**AGE**

12.5 years

**WEIGHT**

5.5 kg

**INTERPRETED BY**

R. McKenzie Daniel,  
DVM, DABVP  
(Canine and Feline)

**IMAGING PERFORMED BY**

Jolee Stegemoller,  
DVM

**HOSPITAL NAME**

North Idaho Animal  
Hospital (VCA)

**REFERRING VET**

Jolee Stegemoller,  
DVM

**INVOICE**

17407

**DATE**

7/26/23

**PRESENTING CLINICAL SIGNS**

Owner was out of town 7/21 to 7/24 and started new bag of food 7/21. When owner returned on 7/24, patient was lethargic, barely eating, and vomiting. No diarrhea. Had I-131 therapy for HT4 in May 2023 and recheck bloodwork in June 2023 was unremarkable (T4 was 1.9). Has been feeling well after therapy, usually very enthusiastic eater. Patient is indoor only, goes outside on patio while supervised by the owner. Had rhinoscopy as a younger cat to remove a nasopharyngeal polyp, but will still occasionally have a sneeze and nasal discharge (none present at this time).

Abnormal PE/Chem/CBC/UA Results: Patient examined 7/25 and 7/26. BCS 7/9, mild dental disease. 7/25 normal TPR, very painful on palpation of thoracic and TL spine, non-painful abdomen, mild dental disease. Leukocytosis characterized by neutrophilia with left shift and monocytosis. Mild pre-renal azotemia. Radiographs unremarkable. 7/26 104.4 fever, pain along cervical and lumbar spine, performed abdominal ultrasound without sedation and no pain noted on abdominal pressure.

**ULTRASONOGRAPHIC EXAMINATION OF THE ABDOMEN**

**Urinary System**

The urinary bladder was normal in size and tone containing anechoic urine primarily with mild, dependent, particulate sediment. There was no evidence of urinary bladder tumors or calculi. The urethra exhibited normal structure and tone to a depth of 2.0 cm.

No evidence of pathology in the area of the aortic trifurcation.

The left kidney was mildly enlarged in size yet maintained a symmetrical contour. A 1:3 cortex / medulla ratio was maintained with mild loss of corticomedullary border demarcation. There was no evidence of left kidney pyelectasia. The left kidney measured 4.8 cm in length.

Mildly enlarged size and asymmetrical margination were present in the right kidney. Mild loss of corticomedullary border demarcation was noted in the right kidney with no evidence of pyelectasia. Right retroperitoneal hyperechogenicity with scant right retroperitoneal effusion was noted. The right kidney measured 4.7 cm in length.

**Adrenal Glands**

The left and right adrenal glands were uniform in size and contour with a uniformly hypoechoic parenchyma. The left adrenal gland measured 0.38 cm width and the right adrenal gland measured 0.30 cm width.

**Spleen**

The spleen exhibited a finely textured and homogenous parenchyma which was hyperechoic to the liver and renal cortical parenchyma. The capsule was smooth and regular without apparent expansion. The splenic vasculature at the hilus was normal in volume with no evidence of congestion or thrombosis. Acute to chronic inflammatory, neoplastic, or benign parenchyma changes were not noted. The spleen exhibited borderline enlargement measuring 1.1 cm in width at the level of the mid-spleen. No splenic masses or nodules were noted. Normal splenic vascularity was present.



**PATIENT**

***Liver/ Gallbladder***

Jasmine Finch

The liver was subjectively normal in size, structure, and contour. The liver parenchyma was uniform and hypoechoic to the spleen with a mild coarse echotexture. The hepatic and portal vasculature were normal in appearance without signs of congestion. The gallbladder was non-distended in size with thin walls and primarily anechoic luminal content. The cystic and common bile ducts were normal.

**SPECIES**

Feline

**BREED**

Domestic Long Hair

***Gastrointestinal***

The stomach presented intact wall layering with a normal wall layer ratio. The lumen of the stomach was empty with no signs of ileus, obstruction, or foreign material.

**SEX**

FS

The small intestine presented intact wall layering with 1:3 muscularis/mucosa ratio. The lumen of the small intestine was empty with no signs of ileus, obstruction, or foreign material.

**AGE**

12.5 years

Normal visible colon wall layers were present with apparent formed feces in lumen.

**WEIGHT**

5.5 kg

***Pancreas***

The left pancreatic limb was normal in size and contour with isoechoic to heterogeneous parenchyma compared to adjacent omentum. No signs of active inflammation or neoplasia.

***Free Abdomen***

**INTERPRETED BY**

No omental masses or overt lymphadenopathy were noted.

R. McKenzie Daniel,  
DVM, DABVP  
(Canine and Feline)

**ULTRASONOGRAPHIC FINDINGS**

**IMAGING PERFORMED BY**

Jolee Stegemoller,  
DVM

- Mild dependent urinary bladder sediment - potential pyuria
- Bilateral mild renomegaly with suspect right kidney nonspecific nephritis
- Mild right retroperitoneal hyperechogenicity and scant retroperitoneal free fluid
- Borderline splenomegaly - nonspecific
- Sonographically unremarkable gastrointestinal tract
- Mild heterogeneous left pancreas

**HOSPITAL NAME**

North Idaho Animal  
Hospital (VCA)

**INTERPRETATION OF THE FINDINGS & FURTHER RECOMMENDATIONS**

**REFERRING VET**

Jolee Stegemoller,  
DVM

The bilateral renal presentation, specifically the right kidney, is suggestive of nonspecific nephritis. Potential for early unilateral or bilateral renal neoplastic criteria is considered less likely yet cannot be excluded. Correlation with recheck CBC/Chemistry panel, and full urinary workup to include UA, as well as urine C/S on a sterile urine sample is recommended.

**INVOICE**

17407

**DATE**

7/26/23

The reported pain, assuming no evidence of spinal abnormalities on radiographs, may be associated with the bilateral kidneys. Potential for low-grade pancreatitis may be suspected if cranial abdominal or subxiphoid discomfort on palpation or abnormal Spec fPL. Correlation with pending CBC pathology review and FUO panel is suggested. Pending additional diagnostics, gastrointestinal and renal support, assessment of clinical response, and monitoring of fever with potential sonographic reassessment, if progressive clinical signs or azotemia, is suggested.



**PATIENT**

Jasmine Finch

**SPECIES**

Feline

**BREED**

Domestic Long Hair

**SEX**

FS

**AGE**

12.5 years

**WEIGHT**

5.5 kg

**INTERPRETED BY**

R. McKenzie Daniel,  
DVM, DABVP  
(Canine and Feline)

**IMAGING PERFORMED BY**

Jolee Stegemoller,  
DVM

**HOSPITAL NAME**

North Idaho Animal  
Hospital (VCA)

**REFERRING VET**

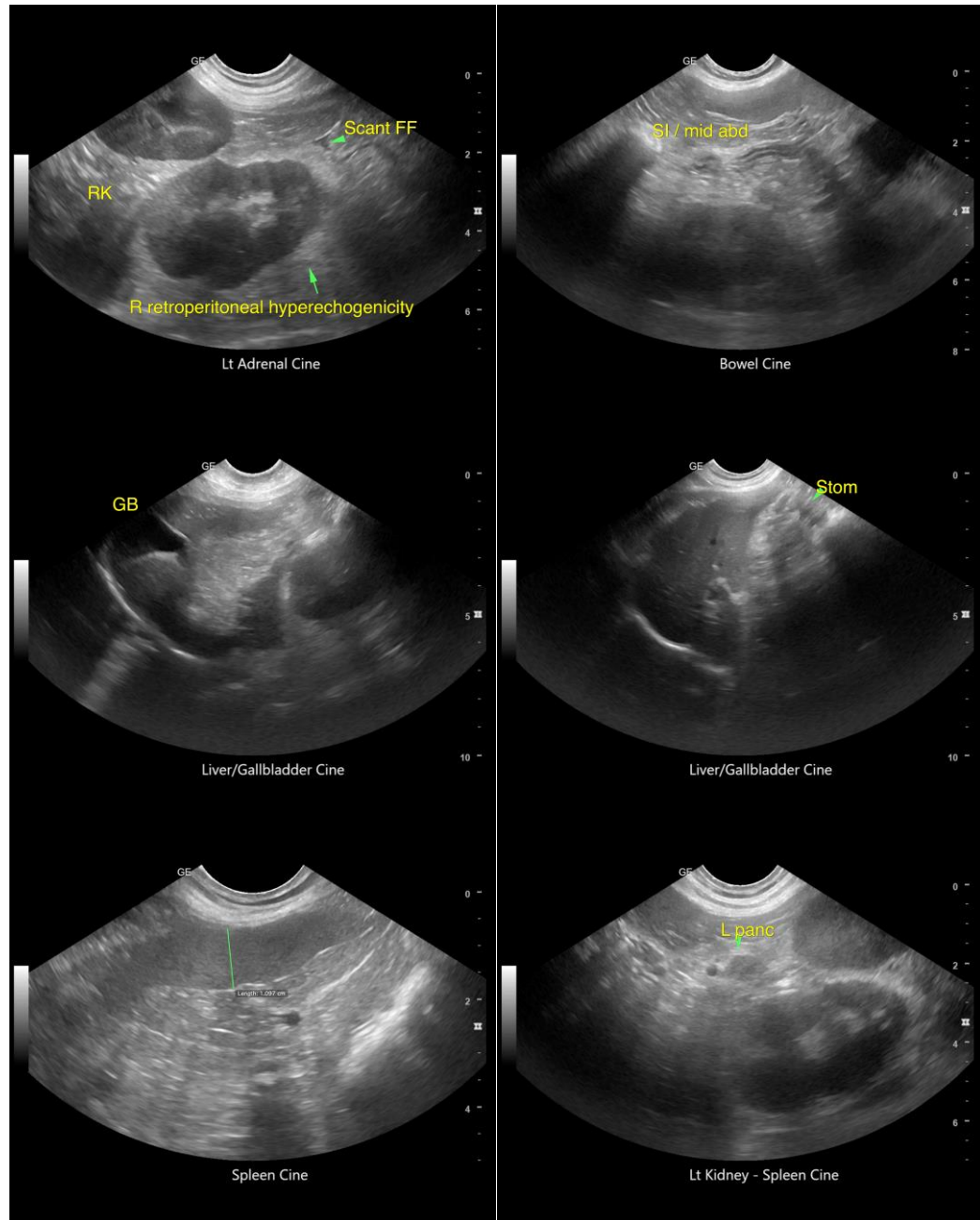
Jolee Stegemoller,  
DVM

**INVOICE**

17407

**DATE**

7/26/23





**PATIENT**

Jasmine Finch

**SPECIES**

Feline

**BREED**

Domestic Long Hair

**SEX**

FS

**AGE**

12.5 years

**WEIGHT**

5.5 kg

**INTERPRETED BY**

R. McKenzie Daniel,  
DVM, DABVP  
(Canine and Feline)

**IMAGING  
PERFORMED BY**

Jolee Stegemoller,  
DVM

**HOSPITAL NAME**

North Idaho Animal  
Hospital (VCA)

**REFERRING VET**

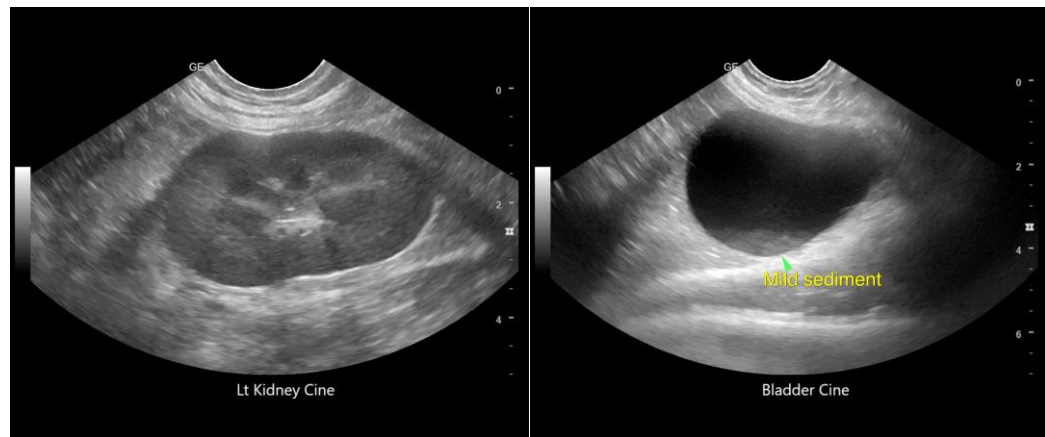
Jolee Stegemoller,  
DVM

**INVOICE**

17407

**DATE**

7/26/23



The information and recommendations provided are based on the images presented by the referring veterinarian/sonographer. No evaluation can be communicated regarding pathology that was not visible in the image/video clips provided.

Thank you for this referral. If the clinical or image interpretation does not parallel your findings or if I can be of any further assistance, please contact me.

**R. McKenzie Daniel, DVM, DABVP (Canine/Feline Practice)**

[info@sonopath.com](mailto:info@sonopath.com)