



**PATIENT PRESENTING CLINICAL SIGNS**

Ruger Fucei Follow up - oncology

**SPECIES ULTRASONOGRAPHIC EXAMINATION OF THE ABDOMEN**

**Canine Urinary System**

The urinary bladder, trigone, cystourethral junction, and visible pelvic urethra to a depth of 5.0 cm exhibited normal thickness and tone. Anechoic urine was present in the lumen with no uroliths or sediment. The ureteral papillae were normal. The ureters were not visible which is normal. No evidence of inflammatory or neoplastic changes was noted.

Lab Mix The residual prostate was free of pathology.

**SEX** The area of the aortic trifurcation was free of pathology including no evidence of medial Iliac or  
 MN sublumbar lymphadenopathy.

**AGE** Normal size and margination were present in the kidneys. A normal 1:3 cortex / medulla ratio and  
 2014 normal corticomedullary definition were maintained. The echogenicity of the cortex was similar to or slightly less than normal liver parenchyma while the medulla echogenicity was hypoechoic to the cortex with no evidence of pelvic dilation. The left kidney measured 6.6 cm in length. The right kidney measured 6.8 cm in length.

**WEIGHT Adrenal Glands**

101.5 The left adrenal gland was uniform in size and contour with a uniformly hypoechoic parenchyma. The left adrenal gland measured 2.5 cm length x 0.44 cm width at the caudal pole. The right adrenal gland was uniform in size and contour with a uniformly hypoechoic parenchyma. The right adrenal gland measured 2.3 cm length x 0.75 cm width at the caudal pole.

**INTERPRETED BY**

R. McKenzie Daniel,  
 DVM, DABVP  
 (Canine and Feline)

**Spleen**

The spleen exhibited a finely textured and homogenous parenchyma which was hyperechoic to the liver and renal cortical parenchyma. The capsule was smooth and regular without apparent expansion. The splenic vasculature at the hilus was normal in volume with no evidence of congestion or thrombosis. Acute to chronic inflammatory, neoplastic, or benign parenchyma changes were not noted.

**IMAGING PERFORMED BY**

Rebekah Jakum, CVT  
 ARDMS/RVT

**HOSPITAL NAME**

Community VP

**Liver/ Gallbladder**

The liver was subjectively normal in size, structure, and contour. The liver parenchyma was uniform and hypoechoic to the spleen with a mild coarse echotexture. The hepatic and portal vasculature were normal in appearance without signs of congestion. The gallbladder was non-distended in size with thin walls and primarily anechoic luminal content. The cystic and common bile ducts were normal.

**REFERRING VET**

Dr. Hulshizer

**Gastrointestinal**

**INVOICE**

14402

The stomach presented intact wall layering with a normal wall layer ratio. The lumen of the stomach was empty with no signs of ileus, obstruction, or foreign material.

**DATE**

7/26/22

The small intestine presented intact wall layering with 1:3 muscularis/mucosa ratio. The lumen of the small intestine was empty with no signs of ileus, obstruction, or foreign material.



**PATIENT**

Normal visible colon wall layers were present with apparent formed feces in lumen.

Ruger Fucei

**Pancreas**

**SPECIES**

The parenchyma of the left limb, body, and right limb of the pancreas presented isoechoic to the adjacent omental fat. A normal curvilinear capsule contour of the pancreas was present. The visible pancreatic duct was normal. No signs of active inflammation or neoplastic disease were evident.

Canine

**Free Abdomen**

**BREED**

No omental masses, lymphadenopathy, or peritoneal effusion were noted.

Lab Mix

**ULTRASONOGRAPHIC FINDINGS**

**SEX**

- Sonographically unremarkable abdomen

MN

**AGE**

**INTERPRETATION OF THE FINDINGS & FURTHER RECOMMENDATIONS**

2014

No evidence of abdominal visceral pathology or intraabdominal metastasis was noted. Sonographic monitoring based on oncology recommendations is recommended.

**WEIGHT**

101.5

**INTERPRETED BY**

R. McKenzie Daniel,  
DVM, DABVP  
(Canine and Feline)

**IMAGING PERFORMED BY**

Rebekah Jakum, CVT  
ARDMS/RVT

**HOSPITAL NAME**

Community VP

**REFERRING VET**

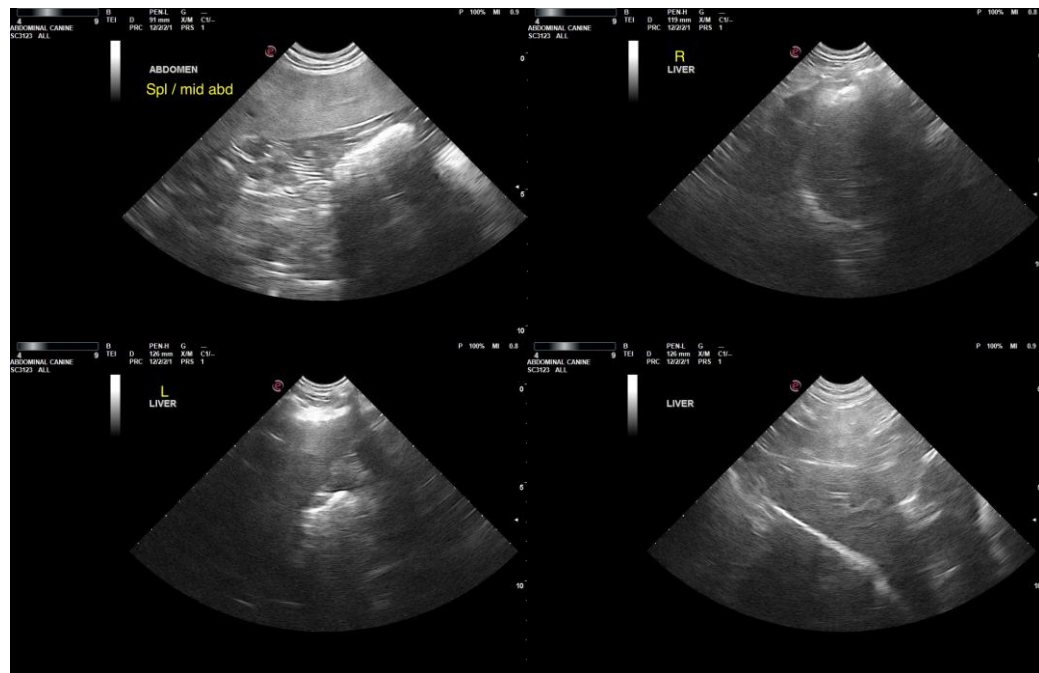Dr. Hulshizer

**INVOICE**

14402

**DATE**

7/26/22





**PATIENT**

Ruger Fucei

**SPECIES**

Canine

**BREED**

Lab Mix

**SEX**

MN

**AGE**

2014

**WEIGHT**

101.5

**INTERPRETED BY**

R. McKenzie Daniel,  
DVM, DABVP  
(Canine and Feline)

**IMAGING PERFORMED BY**

Rebekah Jakum, CVT  
ARDMS/RVT

**HOSPITAL NAME**

Community VP

**REFERRING VET**

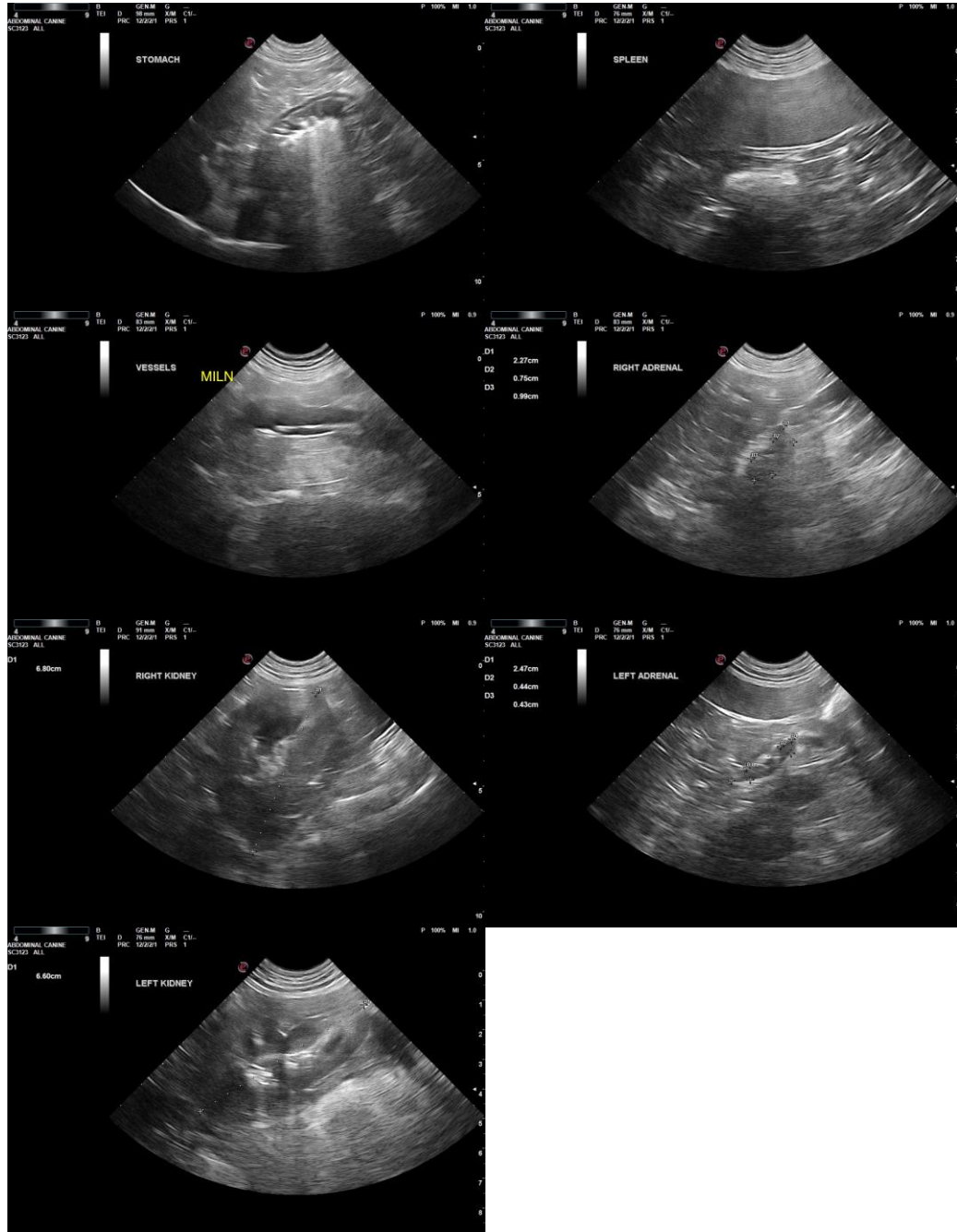
Dr. Hulshizer

**INVOICE**

14402

**DATE**

7/26/22



The information and recommendations provided are based on the images presented by the referring veterinarian/sonographer. No evaluation can be communicated regarding pathology that was not visible in the image/video clips provided.

Thank you for this referral. If the clinical or image interpretation does not parallel your findings or if I can be of any further assistance, please contact me.

**R. McKenzie Daniel, DVM, DABVP (Canine/Feline Practice)**  
[mac.daniel@sonopath.com](mailto:mac.daniel@sonopath.com)