



PATIENT

Echo Vazquez

SPECIES

Canine

BREED

Chihuahua

SEX

M-Intact

AGE

2 years 4 months

WEIGHT

8.1 lbs.

INTERPRETED BY

R. McKenzie Daniel,
DVM, DABVP
(Canine and Feline)

IMAGING PERFORMED BY

Shari Reffi, CVT

HOSPITAL NAME

Newton Vet

REFERRING VET

Dr. Wyman-
Greenwald

INVOICE

14385

DATE

7/26/22

PRESENTING CLINICAL SIGNS

Elevated ALT
Abnormal PE/Chem/CBC/UA Results: ALT 263

ULTRASONOGRAPHIC EXAMINATION OF THE ABDOMEN

Urinary System

The urinary bladder, trigone, cystourethral junction, and visible pelvic urethra to a depth of 3.0 cm exhibited normal thickness and tone. Anechoic urine was present in the lumen with no uroliths or sediment. The ureteral papillae were normal. The ureters were not visible which is normal. No evidence of inflammatory or neoplastic changes was noted.

The prostate exhibited the expected size and presentation for a young intact male canine, measuring 1.7 cm in diameter.

The area of the aortic trifurcation was free of pathology.

Normal size and margination were present in the kidneys. A normal 1:3 cortex / medulla ratio and normal corticomedullary definition were maintained. The echogenicity of the cortex was similar to or slightly less than normal liver parenchyma while the medulla echogenicity was hypoechoic to the cortex with no evidence of pyelectasia. Focal minor areas of medullary mineralization were noted. The left kidney measured 3.7 cm in length. The right kidney measured 3.7 cm in length.

Adrenal Glands

The left adrenal gland was uniform in size and contour with a uniformly hypoechoic parenchyma. The left adrenal gland measured 1.3 cm length x 0.35 cm width at the caudal pole. The right adrenal gland was uniform in size and contour with a uniformly hypoechoic parenchyma. The right adrenal gland measured 1.4 cm length x 0.35 cm width at the caudal pole.

Spleen

The spleen exhibited a finely textured and homogenous parenchyma which was hyperechoic to the liver and renal cortical parenchyma. The capsule was smooth and regular without apparent expansion. The splenic vasculature at the hilus was normal in volume with no evidence of congestion or thrombosis. Acute to chronic inflammatory, neoplastic, or benign parenchyma changes were not noted.

Liver/ Gallbladder

The liver was subjectively normal in size, structure, and contour. The liver parenchyma was uniform and hypoechoic to the spleen with a mild coarse echotexture. The hepatic and portal vasculature were normal in appearance without signs of congestion. Subjective normal hepatportal vasculature volume was noted. The gallbladder was non-distended in size with thin walls and primarily anechoic luminal content. The cystic and common bile ducts were normal.

Gastrointestinal

The stomach presented intact wall layering with a normal wall layer ratio. Minor nonshadowing ingesta/chyme was present.



PATIENT

Echo Vazquez

The small intestine presented intact wall layering with 1:3 muscularis/mucosa ratio. The lumen of the small intestine was empty with no signs of ileus, obstruction, or foreign material.

SPECIES

Canine

Normal visible colon wall layers were present with apparent formed feces in lumen.

BREED

Chihuahua

Pancreas

The parenchyma of the left limb, body, and right limb of the pancreas presented isoechoic to the adjacent omental fat. A normal curvilinear capsule contour of the pancreas was present. The visible pancreatic duct was normal. No signs of active inflammation or neoplastic disease were evident.

SEX

M-Intact

Free Abdomen

No overt lymphadenopathy or peritoneal effusion was present.

AGE

2 years 4 months

The left and right testicles were sonographically normal.

ULTRASONOGRAPHIC FINDINGS

WEIGHT

8.1 lbs.

Primary Findings

- Low-grade hepatopathy - primary parenchymal disease i.e., inflammatory hepatopathy, microvascular dysplasia / portal hypoplasia possible, portosystemic shunt is considered a less likely differential diagnosis
- Minor renal medullary mineralization

INTERPRETED BY

R. McKenzie Daniel,
DVM, DABVP
(Canine and Feline)

INTERPRETATION OF THE FINDINGS & FURTHER RECOMMENDATIONS

Assuming normal clotting status, FNA of the liver could be considered for screening cytology and potential assessment for evidence of inflammatory cells. Fasting and post prandial bile acids are warranted in this patient. Core surgical biopsy may be necessary for further definition as to whether primary parenchymal disease vs. portal hypoplasia / microvascular dysplasia is present.

IMAGING PERFORMED BY

Shari Reffi, CVT

If significant elevation of post prandial bile acids, advanced imaging with Gold Standard CT with contrast may be indicated to rule out portosystemic shunt, although this differential is considered less likely based on normal hepatic vascular volume, as well as lack of additional clinical findings such as urinary bladder calculi or significant renal chanted.

HOSPITAL NAME

Newton Vet

REFERRING VET

Dr. Wyman-
Greenwald

Hepatosupportive medications including Denamarin and Ursodiol empirically with continued monitoring of ALT levels would be reasonable.

INVOICE

14385

DATE

7/26/22



PATIENT

Echo Vazquez

SPECIES

Canine

BREED

Chihuahua

SEX

M-Intact

AGE

2 years 4 months

WEIGHT

8.1 lbs.

INTERPRETED BY

R. McKenzie Daniel,
DVM, DABVP
(Canine and Feline)

IMAGING PERFORMED BY

Shari Reffi, CVT

HOSPITAL NAME

Newton Vet

REFERRING VET

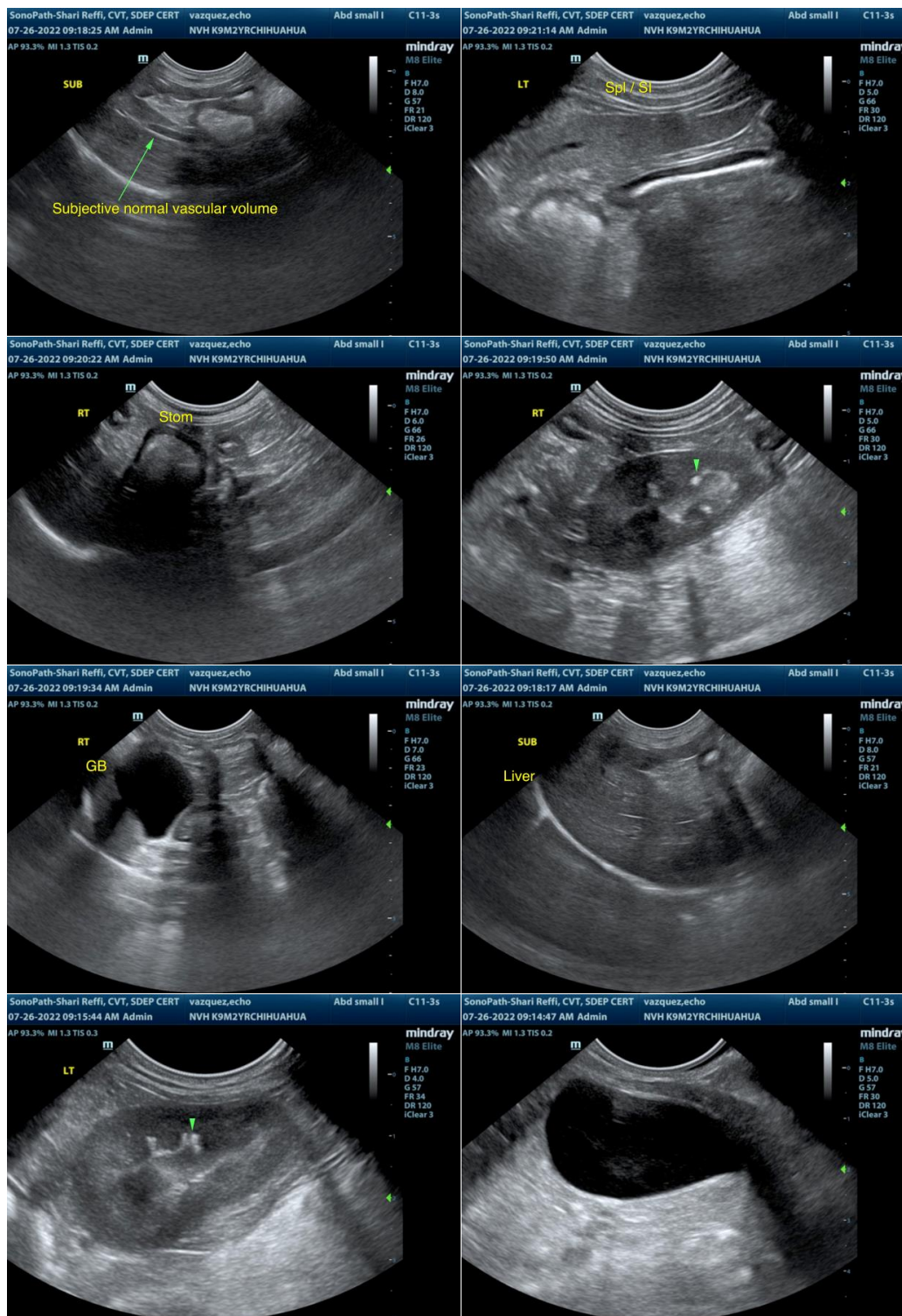
Dr. Wyman-Greenwald

INVOICE

14385

DATE

7/26/22





PATIENT

Echo Vazquez

SPECIES

Canine

BREED

Chihuahua

SEX

M-Intact

AGE

2 years 4 months

WEIGHT

8.1 lbs.

INTERPRETED BY

R. McKenzie Daniel, DVM, DABVP
(Canine and Feline)

IMAGING PERFORMED BY

Shari Reffi, CVT

HOSPITAL NAME

Newton Vet

REFERRING VET

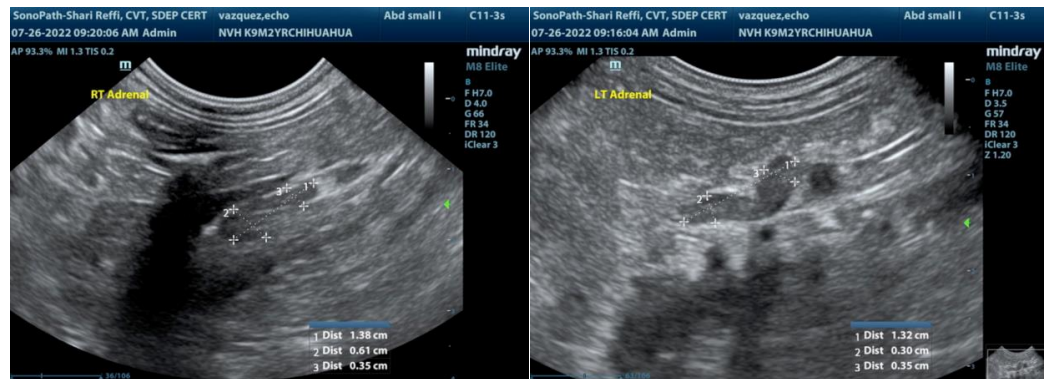
Dr. Wyman-Greenwald

INVOICE

14385

DATE

7/26/22



The information and recommendations provided are based on the images presented by the referring veterinarian/sonographer. No evaluation can be communicated regarding pathology that was not visible in the image/video clips provided.

Thank you for this referral. If the clinical or image interpretation does not parallel your findings or if I can be of any further assistance please contact me.

R. McKenzie Daniel, DVM, DABVP (Canine / Feline Practice)
info@SonoPath.com