SonoPath
Clinical Sonography & Telecytology

EDUCATIONAL TELECONSULTATION SERVICES™

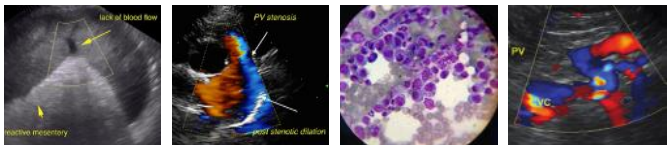

SonoPath.com
1-800-838-4268 info@sonopath.com

PATIENT
Suzie Hiller

SPECIES
Feline

BREED
DSH

SEX
FS

AGE
16yr

WEIGHT
6lb

INTERPRETED BY
R. McKenzie Daniel, DVM, DABVP (Canine and Feline)

IMAGING PERFORMED BY
Jessica Miller

HOSPITAL NAME
Mt. Olive VH

REFERRING VET
Dr. Logan

INVOICE
11193ag

DATE
07/25/2022

PRESENTING CLINICAL SIGNS

History: Hematuria, no stones on radiographs. Current mds: Metronidazole liquid 5mg PO BID

Abnormal PE/Chem/CBC/UA Results: No recent CBC/Chem UA: pH 5.0, pro 2+, blood 3+, RBC 21-50HPF SG: 1.014

ULTRASONOGRAPHIC EXAMINATION OF THE ABDOMEN

Urinary System

The urinary bladder, trigone, cystourethral junction, and visible pelvic urethra to a depth of 2 cm exhibited normal thickness and tone. Anechoic urine was present in the lumen with nondependent to congealed particulate nonmineralized sediment in the mid to cranial lumen. The ureteral papillae were normal. The ureters were not visible which is normal. No evidence of inflammatory or neoplastic changes were noted.

Normal size and margination was present in the kidneys. A normal 1:3 cortex / medulla ratio was maintained. The medulla and cortices were uniform in texture with some increased echogenicity and moderate loss of corticomedullary symmetry and definition expected for the age of the patient. Focal areas of medullary mineral were present. No evidence of pelvic dilation was present. The left kidney measured 3.1 cm in length. The right kidney measured 3.0 cm in length.

The area of the aortic trifurcation was free of pathology.

Adrenal Glands

The left adrenal gland was uniform in size and contour with a uniformly hypoechoic parenchyma. The left adrenal gland measured 0.36 cm. The right adrenal gland was uniform in size and contour with a uniformly hypoechoic parenchyma. The right adrenal gland measured 0.40.

Spleen

The spleen exhibited primarily finely textured parenchyma which was hyperechoic to the liver and renal cortical parenchyma. Mild generalized parenchyma heterogeneity was present without evidence of nodular changes. The capsule was smooth and regular without apparent expansion. The splenic vasculature at the hilus was normal in volume with no evidence of congestion or thrombosis. The parenchymal heterogeneity is likely consistent with benign changes such as extramedullary hematopoiesis or age related remodeling with minor potential for inflammatory or neoplastic disease.

Liver

The liver was subjectively normal in size, structure, and contour. The liver parenchyma was mildly nonuniform and hypoechoic to the spleen with a moderate coarse echotexture and subjective mild to benign parenchymal remodeling. The hepatic and portal vasculature were normal in appearance without signs of congestion.

The gallbladder was non-distended in size with thin walls and primarily anechoic luminal content with very minor luminal debris. The cystic and common bile ducts were normal.

Gastrointestinal

The stomach presented intact wall layering with a normal wall layer ratio. The lumen of the stomach was empty with no signs of ileus, obstruction or foreign material.

The small intestine presented intact wall layering with 1:3 muscularis/mucosa ratio. The lumen of the small intestine was empty with no signs of ileus, obstruction or foreign material.

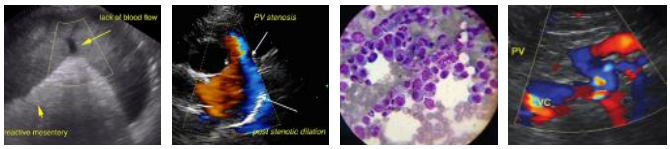

SonoPath.com
1-800-838-4268 info@sonopath.com

PATIENT
Suzie Hiller

SPECIES
Feline

BREED
DSH

SEX
FS

AGE
16yr

WEIGHT
6lb

INTERPRETED BY
R. McKenzie Daniel, DVM, DABVP (Canine and Feline)

IMAGING PERFORMED BY
Jessica Miller

HOSPITAL NAME
Mt. Olive VH

REFERRING VET
Dr. Logan

INVOICE
11193ag

DATE
07/25/2022

Normal visible colon wall layers were present with apparent formed feces in lumen.

Pancreas

The pancreas exhibited normal to mild prominent size with areas of minor capsule asymmetry and a nonhomogeneous to mildly hypoechoic parenchyma along with mild pancreatic duct dilation. Subtle evidence of peripancreatic reactive mesentery was present.

Free Abdomen

No omental masses or overt lymphadenopathy was present. Mild volume peritoneal free fluid was present. in the caudal abdomen around the urinary bladder and in the cranial abdomen around the liver.

ULTRASONOGRAPHIC FINDINGS

- Moderate chronic renal changes with focal medullary mineral
- Normal urinary bladder with probable mild cellular debris
- Mild hepatic parenchymal remodeling
- Mildly prominent pancreas with pancreatic duct dilation-potential for mild chronic to chronic active pancreatitis
- Mild volume nonspecific peritoneal free fluid

INTERPRETATION OF THE FINDINGS & FURTHER RECOMMENDATIONS

No obvious evidence of urinary bladder neoplastic or inflammatory criteria with suspect cellular debris consistent with reported hematuria. Potentially the hematuria may be originating from the level of the kidneys. Correlation with a urine C/S to rule out underlying infection is suggested.

Potential for low grade chronic active pancreatitis may be suspected if evidence of cranial abdominal or subxiphoid discomfort on palpation. Correlation with a spec fPL could be considered.

The free fluid may indicate non-septic (increased vascular permeability, decreased hydrostatic pressure) or septic effusion. Further assessment including effusion analysis, cytology +/- C/S if evidence of inflammatory cells is recommended.

SonoPath

Clinical Sonography & Telecytology

EDUCATIONAL TELECONSULTATION SERVICES™

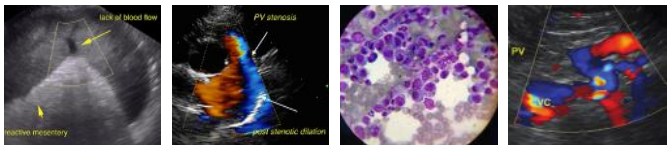

SonoPath.com
1-800-838-4268 info@sonopath.com

PATIENT

Suzie Hiller

SPECIES

Feline

BREED

DSH

SEX

FS

AGE

16yr

WEIGHT

6lb

INTERPRETED BY

R. McKenzie Daniel, DVM, DABVP (Canine and Feline)

IMAGING PERFORMED BY

Jessica Miller

HOSPITAL NAME

Mt. Olive VH

REFERRING VET

Dr. Logan

INVOICE

11193ag

DATE

07/25/2022

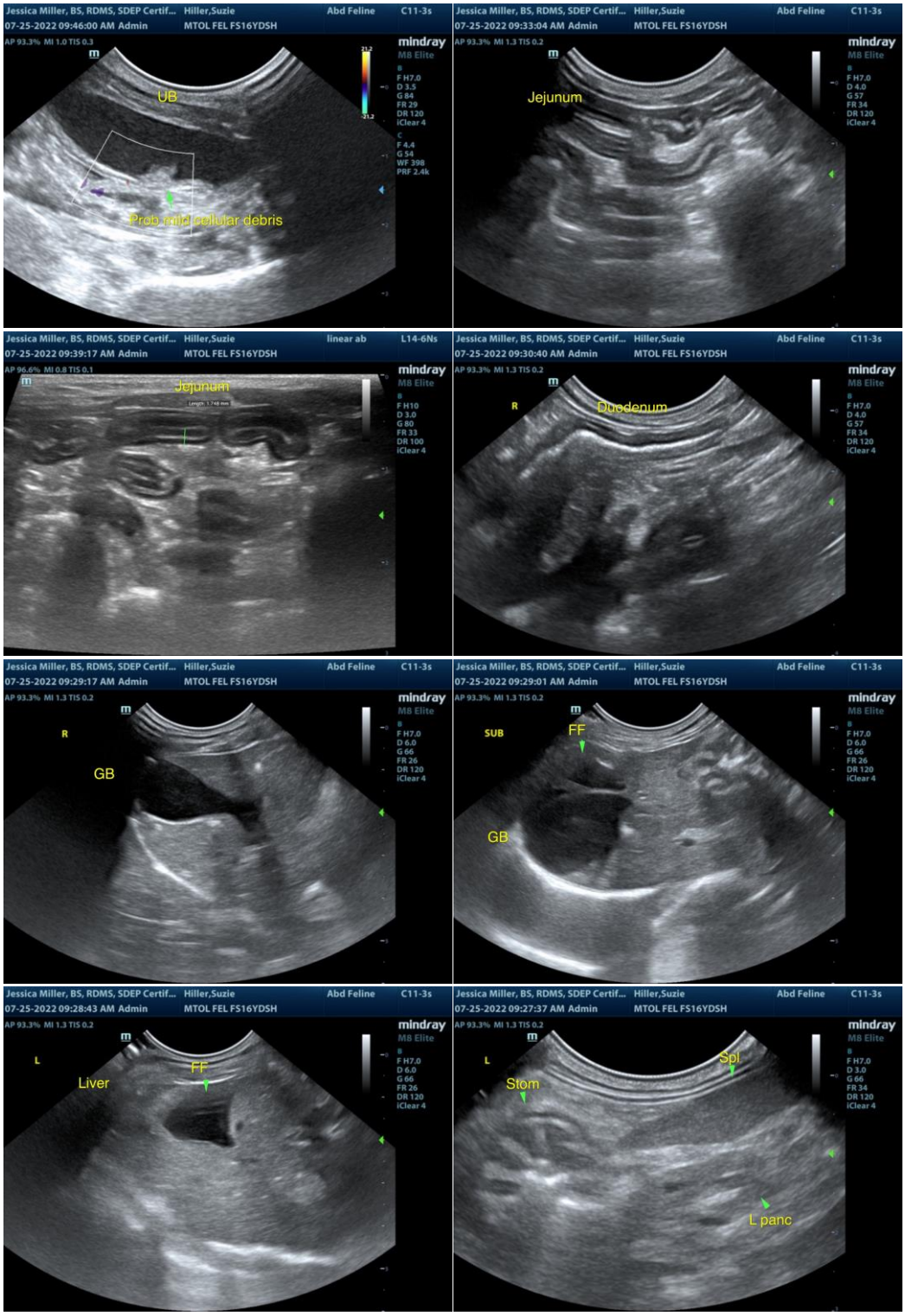

SonoPath

Clinical Sonography & Telecytology

EDUCATIONAL TELECONSULTATION SERVICES™

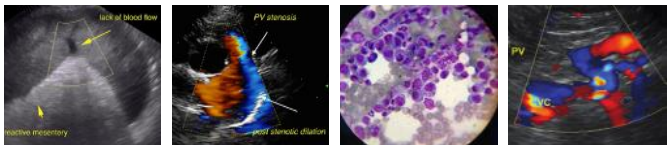

SonoPath.com™
1-800-838-4268 info@sonopath.com

PATIENT

Suzie Hiller

SPECIES

Feline

BREED

DSH

SEX

FS

AGE

16yr

WEIGHT

6lb

INTERPRETED BY

R. McKenzie Daniel, DVM, DABVP (Canine and Feline)

IMAGING PERFORMED BY

Jessica Miller

HOSPITAL NAME

Mt. Olive VH

REFERRING VET

Dr. Logan

INVOICE

11193ag

DATE

07/25/2022

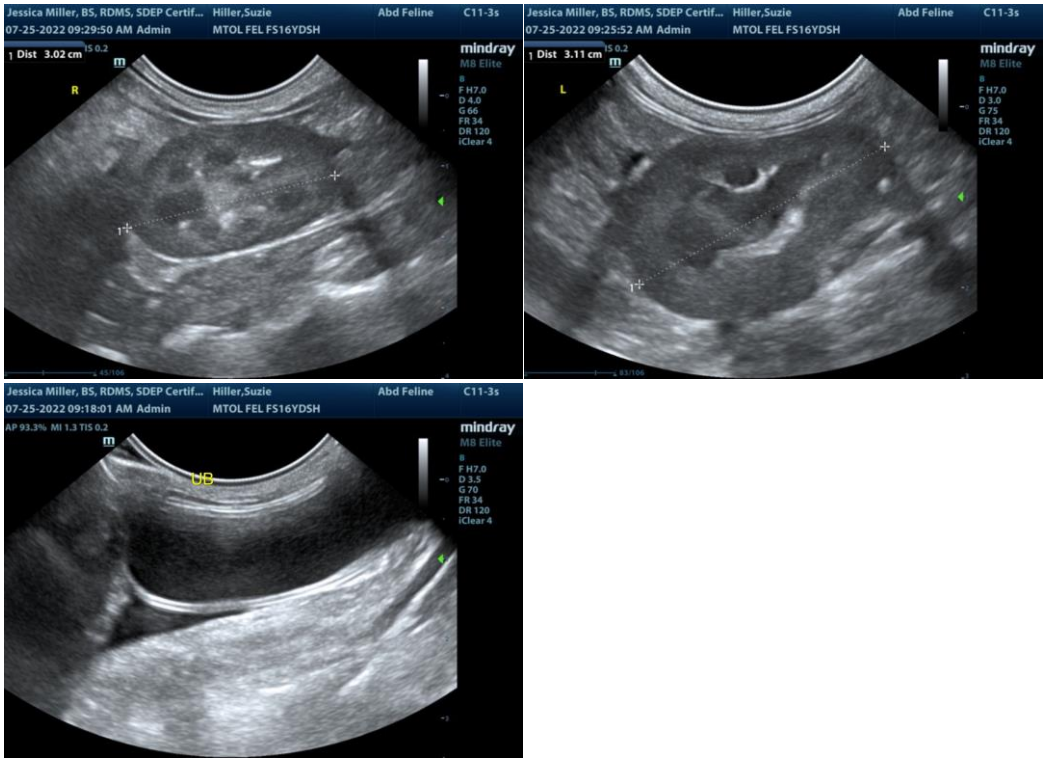

The information and recommendations provided are based on the images presented by the referring veterinarian/sonographer. No evaluation can be communicated regarding pathology that was not visible in the image/video clips provided.

Thank you for this referral. If the clinical or image interpretation does not parallel your findings or if I can be of any further assistance please contact me.

R. McKenzie Daniel, DVM, DABVP (Canine / Feline Practice)

info@SonoPath.com