



PATIENT PRESENTING CLINICAL SIGNS

Willow OKeefe History: Elevated liver values. ALP 590; GGTP 22. Currently on SO, Soloxine 0.15 mg in AM, 0.1 mg PM. *Sedated with torb/dex *FNA of liver taken at time of ultrasound

SPECIES ULTRASONOGRAPHIC EXAMINATION OF THE ABDOMEN

Canine **Urinary System**

BREED

Chihuahua

The urinary bladder, trigone, cystourethral junction, and visible pelvic urethra to a depth of 2 cm exhibited normal thickness and tone. Mild asymmetrical luminal surface to micropolyploid changes were present likely associated with age related mural changes. Anechoic urine was present in the lumen with focal areas of dependent mineral. The ureteral papillae were normal. The ureters were not visible which is normal. No evidence of inflammatory or neoplastic changes were noted.

SEX

FS

Normal size and margination was present in the kidneys. A normal 1:3 cortex / medulla ratio was maintained. The medulla and cortices were uniform in texture with some increased echogenicity and mild loss of corticomedullary symmetry and definition expected for the age of the patient. Bilateral areas of minor medullary mineral and minor pyelectasia were present. The left kidney measured 5.1 cm in length. The right kidney measured 4.6 cm in length.

AGE

10yr

The area of the aortic trifurcation was free of pathology.

Adrenal Glands

WEIGHT

18lb

The left adrenal gland was uniform in size and contour with a uniformly hypoechoic parenchyma. The left adrenal gland measured 0.59 cm width at the caudal pole and 0.39 cm width at the cranial pole. The right adrenal gland was uniform in size and contour with a uniformly hypoechoic parenchyma. The right adrenal gland measured 0.47 cm width at the caudal pole and 0.45 cm width at the cranial pole.

INTERPRETED BY

R. McKenzie Daniel, DVM, DABVP (Canine and Feline)

Spleen

The spleen exhibited primarily finely textured parenchyma which was hyperechoic to the liver and renal cortical parenchyma. Mild generalized parenchyma heterogeneity was present without evidence of nodular changes. The capsule was smooth and regular without apparent expansion. The splenic vasculature at the hilus was normal in volume with no evidence of congestion or thrombosis. The parenchymal heterogeneity is likely consistent with benign changes such as extramedullary hematopoiesis or age related remodeling with minor potential for inflammatory or neoplastic disease.

IMAGING PERFORMED BY

Pamela Harrigan, RDCS

HOSPITAL NAME

Pine Banks Animal Hospital

Liver

The liver presented mild to moderately enlarged in size. A moderately expansive solid to mixed echogenic mass appearing to arise from the mid ventrocaudal liver measuring approximately 5 cm in diameter. The liver parenchyma was uniform with a mildly coarse echotexture. The capsule of the liver was symmetrically rounded to mildly swollen in margination. The hepatic and portal vasculature were normal in appearance without signs of congestion. The gallbladder was non-distended in size with primarily anechoic luminal content and moderate congealed yet nonorganized hyperechoic debris. The cystic and common bile ducts were normal.

REFERRING VET

Dr. Syed

INVOICE

11162ag

Gastrointestinal

The stomach presented intact wall layering with a normal wall layer ratio. The lumen of the stomach was empty with no signs of ileus, obstruction or foreign material.

DATE

07/24/2022

The small intestine presented intact wall layering with 1:3 muscularis/mucosa ratio. The lumen of the small intestine was empty with no signs of ileus, obstruction or foreign material.



PATIENT Normal visible colon wall layers were present with apparent formed feces in lumen.

Willow OKeefe **Pancreas**

SPECIES The pancreas was normal in size and contour with isoechoic to heterogeneous parenchyma compared to adjacent omentum. No signs of active inflammation or neoplasia.

Canine **ULTRASONOGRAPHIC FINDINGS**

- BREED**
- Minor dependent urinary bladder mineral
 - Mild chronic renal changes with pinpoint focal minor medullary mineral and bilateral pyelectasia
 - Hepatopathy with ventrocaudal mixed echogenic mass
 - Moderate gallbladder debris (non mucocele)
- Chihuahua

INTERPRETATION OF THE FINDINGS & FURTHER RECOMMENDATIONS

SEX The majority of the liver is likely consistent with benign hepatopathy such as vacuolar hepatopathy or other. Multiple etiologies possible for the mixed echogenic mass including nodular hyperplasia, granuloma, hematopoiesis or neoplasia. Correlation with pending cytology is suggested. No overt evidence of intra-abdominal metastasis was observed.

AGE The hepatic mass appears to be amendable to surgical resection if clinically indicated. Three view chest radiographs are suggested if not recently done. Empirically hepatosupportive medications including Denamarin and Ursodiol may prove beneficial.

WEIGHT This patient may be passing small amounts of mineral from the kidneys into the urinary bladder. The pyelectasia may be owing to chronic renal changes, potential pelvic scarring possibly owing to previous calculi passage, IV fluid therapy (if applicable). Urine C/S and protein: creatinine ratio on sterile urine sample is recommended.

INTERPRETED BY

R. McKenzie Daniel, DVM,
 DABVP (Canine and Feline)

IMAGING PERFORMED BY

Pamela Harrigan, RDCS

HOSPITAL NAME

Pine Banks Animal Hospital

REFERRING VET

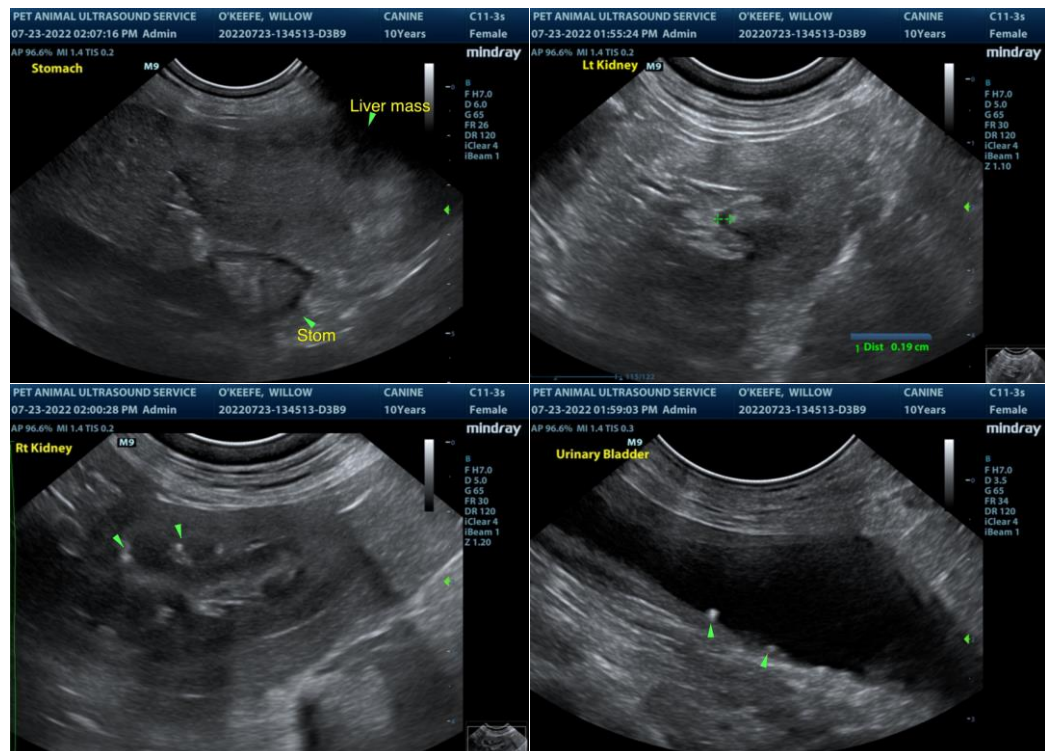
Dr. Syed

INVOICE

11162ag

DATE

07/24/2022





PATIENT

Willow OKeefe

SPECIES

Canine

BREED

Chihuahua

SEX

FS

AGE

10yr

WEIGHT

18lb

INTERPRETED BY

R. McKenzie Daniel, DVM,
 DABVP (Canine and Feline)

IMAGING PERFORMED BY

Pamela Harrigan, RDCS

HOSPITAL NAME

Pine Banks Animal
 Hospital

REFERRING VET

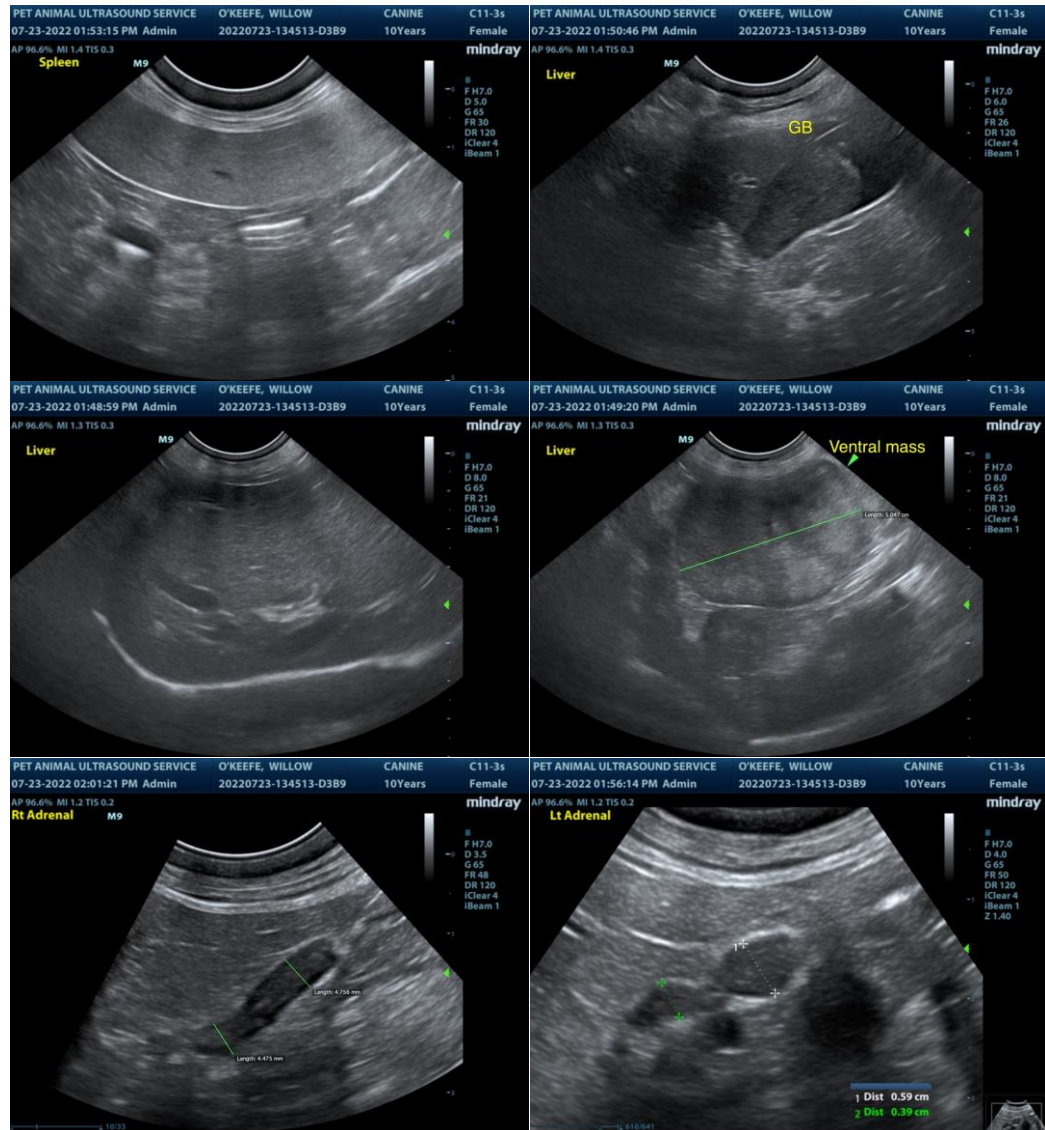
Dr. Syed

INVOICE

11162ag

DATE

07/24/2022



The information and recommendations provided are based on the images presented by the referring veterinarian. No evaluation can be communicated regarding pathology that was not visible in the image/video clips provided.

Thank you for this referral. If the clinical or image interpretation does not parallel your findings or if I can be of any further assistance please contact me.

R. McKenzie Daniel, DVM, DABVP (Canine / Feline Practice)
 info@SonoPath.com