



PATIENT	PRESENTING CLINICAL SIGNS
Brontie Traverse	All seems normal on exam. Bloodwork all within normal limits. No medications. Abnormal PE/Chem/CBC/UA Results: Rads:mid abdomen mass effect, poss in liver
SPECIES	ULTRASONOGRAPHIC EXAMINATION OF THE ABDOMEN
Canine	Urinary System The urinary bladder, trigone, cystourethral junction, and visible pelvic urethra to a depth of 3.0 cm exhibited normal thickness and tone. Anechoic urine was present in the lumen with no uroliths or sediment. The ureteral papillae were normal. The ureters were not visible which is normal. No evidence of inflammatory or neoplastic changes was noted.
BREED	
German Shep	The area of the aortic trifurcation was free of pathology.
SEX	No overt pathology was noted in the area of the uterine remnant.
FS	
AGE	Normal size and margination were present in the kidneys. A normal 1:3 cortex / medulla ratio and normal corticomedullary definition were maintained. The echogenicity of the cortex was similar to or slightly less than normal liver parenchyma while the medulla echogenicity was hypoechoic to the cortex with no evidence of pelvic dilation. The left kidney measured 6.5 cm in length. The right kidney measured 7.0 cm in length.
1.5 yr	
WEIGHT	Adrenal Glands The left and right adrenal s were indistinctly visualized yet without overt pathology. The left adrenal gland subjectively measured 0.95 cm width at the caudal pole. The right adrenal gland subjectively measured 0.74 cm width at the caudal pole.
36.2 kg	
INTERPRETED BY	Spleen The spleen was mildly enlarged with lateral folding of the caudal spleen and medial folding of the cranial spleen. Normal splenic vascularity was noted. The spleen maintained symmetrical capsule contour and a finely textured homogeneous splenic parenchyma. No splenic masses or nodules were noted.
R. McKenzie Daniel, DVM, DABVP	
IMAGING PERFORMED BY	Liver/ Gallbladder The liver was subjectively normal in size, structure, and contour. The liver parenchyma was uniform and hypoechoic to the spleen with a mild coarse echotexture. The hepatic and portal vasculature were normal in appearance without signs of congestion. The gallbladder was non-distended in size with thin walls and primarily anechoic luminal content. The cystic and common bile ducts were normal.
Crystal Hill	
HOSPITAL NAME	Gastrointestinal The stomach presented intact wall layering with a normal wall layer ratio. The lumen of the stomach was empty with no signs of ileus, obstruction, or foreign material.
Governors Road Animal Hospital	
REFERRING VET	DATE The small intestine presented intact wall layering with 1:3 muscularis/mucosa ratio. The lumen of the small intestine was empty with no signs of ileus, obstruction, or foreign material.
Dr. Dogar	
INVOICE	
14365	
DATE	
7/22/22	



PATIENT

Normal visible colon wall layers were present with apparent formed feces in lumen.

Brontie Traverse

Pancreas

SPECIES

The parenchyma of the left limb, body, and right limb of the pancreas presented isoechoic to the adjacent omental fat. A normal curvilinear capsule contour of the pancreas was present. The visible pancreatic duct was normal. No signs of active inflammation or neoplastic disease were evident.

Canine

Free Abdomen

BREED

No omental masses, lymphadenopathy or evidence of peritoneal effusion was present.

German Shep

ULTRASONOGRAPHIC FINDINGS

SEX

- Mild splenomegaly with cranial and caudal folding
- Sonographically unremarkable liver

FS

INTERPRETATION OF THE FINDINGS & FURTHER RECOMMENDATIONS

AGE

No evidence of intraabdominal pathology including no evidence of intraabdominal masses. The mass effect noted on the radiographs likely correlates with the mild splenomegaly exhibiting cranial and caudal folding. This is likely a patient variant and not indicative of underlying splenic pathology and potential for benign splenic hyperplasia, hematopoiesis, breed-associated hypersplenism, or incidental splenitis, is possible.

1.5 yr

WEIGHT

36.2 kg

INTERPRETED BY

Radiographic monitoring of the spleen for evidence of persistent / progressive enlargement would be reasonable. Assuming normal clotting status, ultrasound-guided FNA of the spleen using a 25-gauge needle could also be considered for screening cytology primarily to ensure only benign changes are present. However, no evidence of hepatosplenic pathology was noted.

R. McKenzie Daniel,
DVM, DABVP

IMAGING PERFORMED BY

Crystal Hill

HOSPITAL NAME

Governors Road
Animal Hospital

REFERRING VET

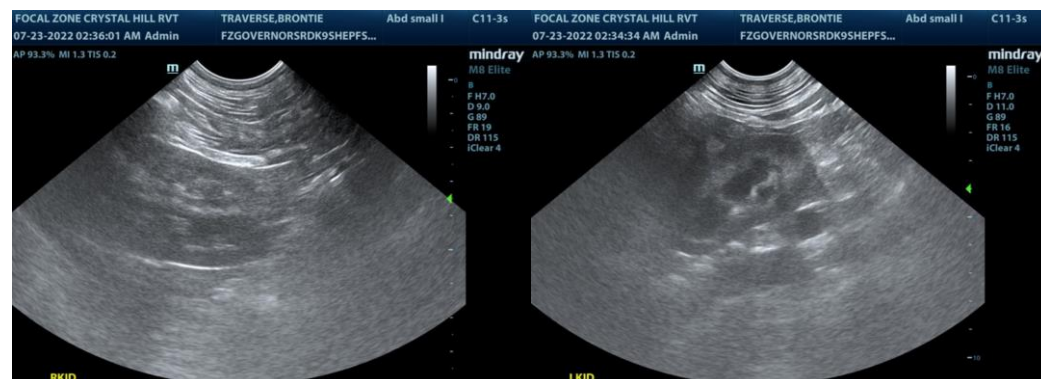
Dr. Dogar

INVOICE

14365

DATE

7/22/22





PATIENT

Brontie Traverse

SPECIES

Canine

BREED

German Shep

SEX

FS

AGE

1.5 yr

WEIGHT

36.2 kg

INTERPRETED BY

R. McKenzie Daniel,
DVM, DABVP

**IMAGING
PERFORMED BY**

Crystal Hill

HOSPITAL NAME

Governors Road
Animal Hospital

REFERRING VET

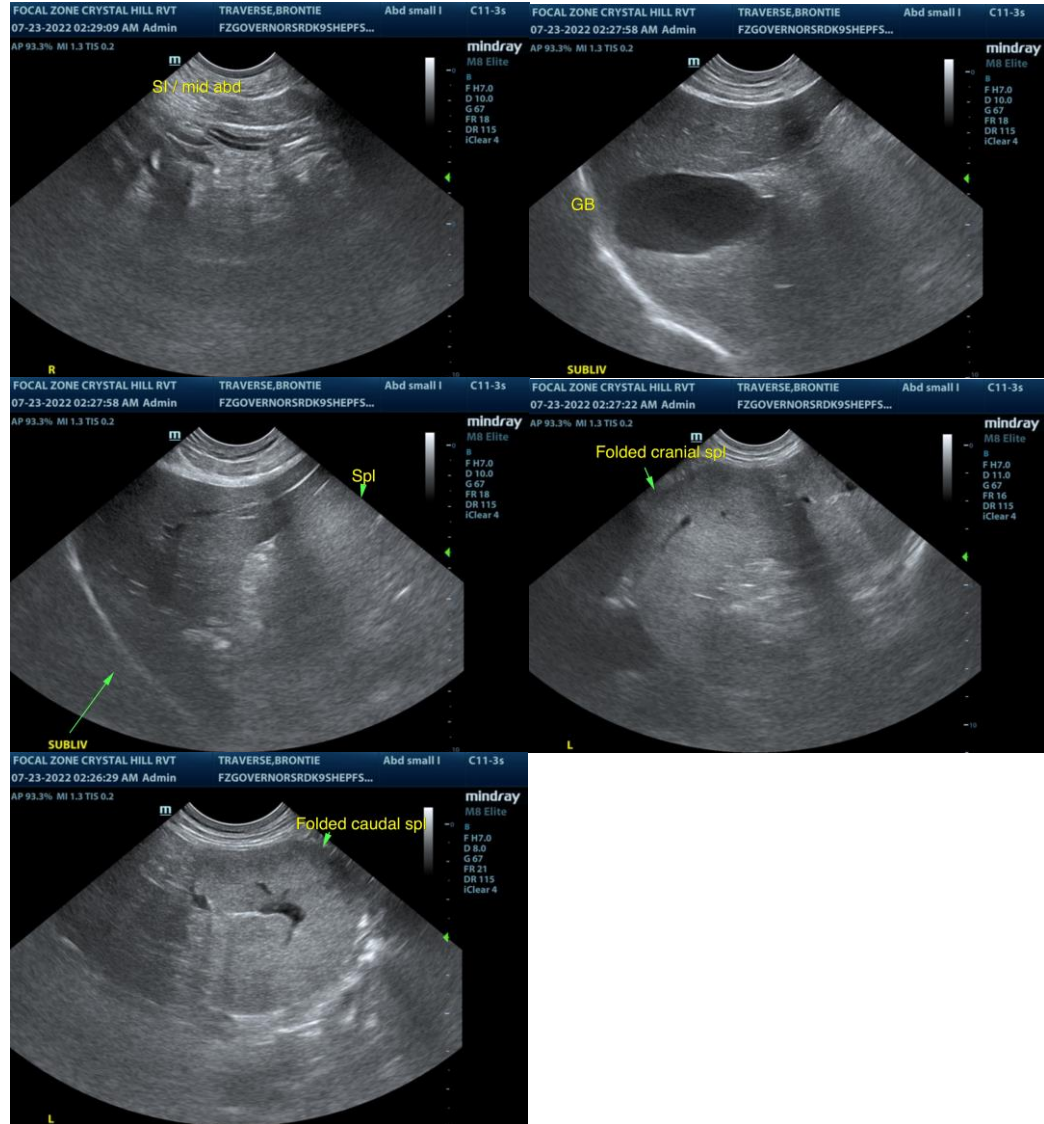
Dr. Dogar

INVOICE

14365

DATE

7/22/22



The information and recommendations provided are based on the images presented by the referring veterinarian/sonographer. No evaluation can be communicated regarding pathology that was not visible in the image/video clips provided.

Thank you for this referral. If the clinical or image interpretation does not parallel your findings or if I can be of any further assistance please contact me.

R. McKenzie Daniel, DVM, DABVP (Canine / Feline Practice)
info@SonoPath.com