



PATIENT PRESENTING CLINICAL SIGNS

Sophie Amin PLE, GB mucocele removed surgically, MR Pimobendan 1.87 BID, Visbiome, Prednisone 2.5 EOD, Cosequin, RCVD lowfat/l/d

SPECIES ALP 208, Albumin 1.9, Precision PSL 590, WBC 18.7 with mild neutrophilia and monocytosis, B12 834, Folate >24
Canine

BREED ULTRASONOGRAPHIC EXAMINATION OF THE HEART & ABDOMEN

Poodle Mix

SEX

FS

AGE

2013

WEIGHT

15.2

INTERPRETED BY

R. McKenzie Daniel, DVM, DABVP (Canine and Feline)

IMAGING

PERFORMED BY
Rebekah Jakum, CVT
ARDMS/RVT

HOSPITAL NAME

New Britain VC

REFERRING VET

Dr. Bandekar

INVOICE

14353

DATE

7/21/22

CANINE	MR	TR	LA/AO	LA/AO	FS	EF	EPSS
CARDIAC PARAMETERS	VMAX (m/s)	VMAX (m/s)	(Boon method)	(Heart Base; Swe)	(%)	(%)	(cm)
NORMAL PARAMETER	4.5-5.5	<2.7	1.3	<1.3	28-40	40-100	<0.6
PATIENT	5.6	2.6		1.8	43	75	0.2
CANINE	HR	AV	PV	BODY WEIGHT	LA	LVIDd	LVIDs
CARDIAC PARAMETERS	(BPM)	VMAX (m/s)	MAX (m/s)	(kg)	2D short axis Base view (cm)	Avg; 2D and m-mode short axis (cm)	Avg; 2D and m-mode short axis (cm)
NORMAL PARAMETER	50-100	0.7-1.7	0.7-1.6				
PATIENT	161	1.9	1.3		3.6	2.9	

Cardiac Presentation

The echocardiogram in this patient demonstrated moderately enlarged **left atrial** size based on 3 different LA measurement methods. Deviation of the interatrial septum towards the right atrium consistent with increased left atrial pressure was present. The cranial and caudal **mitral** valve leaflets presented vegetative thickening consistent with endocardiosis. No evidence of valvular prolapse or chordae tendinea rupture was noted. Doppler indicated measurable moderate eccentric insufficiency. The **left ventricle** presented thicknesses with linear contour with increased left ventricle volume. The **myocardium** presented normal echogenicity without subjective evidence of significant fibrotic or ischemic disease. **Contractility** of the ventricular walls was adequate and in normal range for this patient evidenced by the fractional shortening measurement and subjective evaluation of the different regions of the myocardium. The **left ventricular outflow** tract demonstrated normal laminar flow and subjective structural integrity. The **right atrium** and auricle revealed normal size, structure and content. No evidence of masses was noted or chamber overload. **Tricuspid** valvular assessment demonstrated concurrent thickening with mild TR on doppler. The **right ventricle** was of normal size (1/3 diameter of LV), chordae structure, myocardial echogenicity and thickness. **Pulmonic** tract assessment revealed normal valve structure, laminar flow, and diameter (approx. 1:1 pa/ao ratio). No visible **pericardial** or free pleura fluid was noted. No echographically detectable evidence of



PATIENT

infiltrative disease was visible. The cranial **mediastinum and pericardial regions** were free of masses in the visible window.

Sophie Amin

Urinary System

SPECIES

The urinary bladder, trigone, cystourethral junction, and visible pelvic urethra to a depth of 3.0 cm exhibited normal thickness and tone. Anechoic urine was present in the lumen with no uroliths or sediment. The ureteral papillae were normal. The ureters were not visible which is normal. No evidence of inflammatory or neoplastic changes was noted.

Canine

BREED

The area of the aortic trifurcation was free of pathology.

Poodle Mix

SEX

Normal size and margination were present in the kidneys. A normal 1:3 cortex / medulla ratio and normal corticomedullary definition were maintained. The echogenicity of the cortex was similar to or slightly less than normal liver parenchyma while the medulla echogenicity was hypoechoic to the cortex with no evidence of pelvic dilation. The left kidney measured 4.7 cm in length. The right kidney measured 5.2 cm in length.

FS

AGE

Adrenal Glands

2013

The left adrenal gland was uniform in size and contour with a uniformly hypoechoic parenchyma. The left adrenal gland measured 2.0 cm length x 0.55 cm width at the caudal pole. The right adrenal gland was uniform in size and contour with a uniformly hypoechoic parenchyma. The right adrenal gland measured 1.7 cm length x 0.36 cm width at the caudal pole.

WEIGHT

15.2

Spleen

INTERPRETED BY

The spleen exhibited primarily finely textured and homogenous parenchyma which was hyperechoic to the liver and renal cortical parenchyma. Intermittent, small, hyperechogenic nodules were present primarily in the medial parenchyma and adjacent to the hilus. The capsule was smooth and regular without apparent expansion. The splenic vasculature at the hilus was normal in volume with no evidence of congestion or thrombosis. Acute to chronic inflammatory or neoplastic changes were not noted. The echogenic nodules tend to trend benign and are most consistent with benign hyperplasia or myelolipomas.

R. McKenzie Daniel,
 DVM, DABVP
 (Canine and Feline)

IMAGING PERFORMED BY

Rebekah Jakum, CVT
 ARDMS/RVT

Liver/ Gallbladder

HOSPITAL NAME

The liver presented enlarged in size. The parenchyma of the liver was subjectively normal in echogenicity compared to the spleen and renal cortices. The liver parenchyma was uniform with a mildly coarse echotexture. The capsule of the liver was symmetrically rounded to mildly swollen in margination. The hepatic and portal vasculature were normal in appearance without signs of congestion. The gallbladder was not visualized owing to previously cholecystectomy. No overt pathology was noted in the area of the previous gallbladder. Potential minor nonobstructive residual common bile duct dilation was noted.

New Britain VC

REFERRING VET

Dr. Bandekar

INVOICE

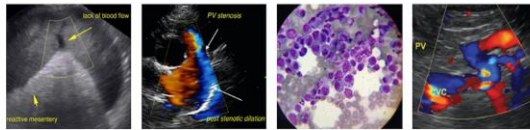
Gastrointestinal

14353

The stomach presented intact wall layering with a normal wall layer ratio. The lumen of the stomach was empty with no signs of ileus, obstruction, or foreign material.

DATE

7/21/22



PATIENT

Sophie Amin

SPECIES

Canine

BREED

Poodle Mix

SEX

FS

AGE

2013

WEIGHT

15.2

INTERPRETED BY

R. McKenzie Daniel,
 DVM, DABVP
 (Canine and Feline)

IMAGING PERFORMED BY

Rebekah Jakum, CVT
 ARDMS/RVT

HOSPITAL NAME

New Britain VC

REFERRING VET

Dr. Bandekar

INVOICE

14353

DATE

7/21/22

Generalized increased intestinal mucosa echogenicity with diffuse mucosa speckling to echogenic mucosal striations were present. Intestinal wall layering was maintained with mild altered 1:3 muscularis / mucosa ratio. There was no evidence of an obstructive pattern or foreign material. The appearance of the small intestine is most consistent with protein-losing enteropathy or lymphangiectasia. There was no evidence of infiltrative or neoplastic intestinal disease which is considered unlikely but cannot be ruled out without full thickness or endoscopic biopsies.

The colon walls presented intact yet prominent wall layering with mild thickened to echogenic submucosa. The colon was primarily empty with mild semi-formed to soft matter present with lumen dilation. The distal descending colon wall width measured 0.25 cm.

Pancreas

The pancreas was normal in size and contour with isoechoic to heterogeneous parenchyma compared to adjacent omentum. No signs of active inflammation or neoplasia.

Free Abdomen

Mild peri intestinal hyperechoic mesentery was present. Intermittent subjectively benign / reactive mesenteric lymph nodes were noted. Very scant pockets of primarily peri intestinal free fluid were noted.

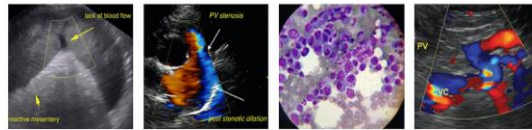
ULTRASONOGRAPHIC FINDINGS

- Chronic mitral valve disease (ACVIM B2, possible emerging stage C)
- TV Insufficiency - estimated pulmonary pressure gradient (approximately 27 mm Hg) suggestive of mild increased pulmonary pressure yet not consistent with clinical pulmonary hypertension
- Vacuolar hepatopathy pattern - benign, no evidence of residual pathology in the area of the previous gallbladder
- Benign splenic nodules - consistent with small myelolipomas or potential previous infarction
- Enteropathy - sonographically consistent with previously diagnosed protein-losing enteropathy
- Colitis
- Mild primarily peri intestinal reactive mesentery and small pockets of scant primarily peri intestinal free fluid

INTERPRETATION OF THE FINDINGS & FURTHER RECOMMENDATIONS

Continued therapy for protein-losing enteropathy with monitoring of albumin levels going forward would be reasonable. Potentially, If progressive hypoalbuminemia, colloids may be indicated. Some or all of the following protocol could be considered as-needed or If clinically Indicated.

Continued Pimobendan at current dose is recommended. Given the degree of left atrium enlargement and if no current clinical signs of decompensation, i.e., pulmonary edema, a weak diuretic such as Spironolactone 1.0-2.0 kg/kg PO BID with baseline monitoring of resting respiration rate could



PATIENT

Sophie Amin

be considered. Serial echocardiographic monitoring of the heart is recommended going forward. Recheck echocardiogram is recommended in 6 months, sooner if clinical signs consistent with left-sided heart disease or decompensation are noted.

SPECIES

Canine

Part or all of this protocol may be considered based on your clinical impression of the patient:

BREED

Poodle Mix

OBJECTIVE: keep albumin levels > 2 g/dl, avoid thromboembolism and cavitory effusions, monitor concurrent PLN (Wheaton Terrier PLE/PLN) and liver disease:

Plasma 10 mL / kilogram IV over 4 hours

Or **Human albumin** 2 ml/kg/h over 10 hours. Total daily volume 20.l/kg/day

And Colloids/Hetastarch

10 to 20 mL per kilogram per day and dogs

SEX

FS

10 to 15 mL per kilogram per day cats
(Can bolus first 1/3 of dose over 15 minutes)

& maintain on LRS maintenance otherwise.

AGE

2013

Metronidazole (10-20 mg/kg po bid)

Famotidine 1 mg/kg lv 1m po dc Sid /bid

Sucralfate 0.5-1 g po tid dogs, 0.5 g bid cats in slurry Or **Misoprostol** 1-5 ug/kg po tid

Diet: Highly digestible high quality protein, low fiber, low fat diet (< 15% of dry matter). Hydrolyzed protein or novel protein. Purina HA or Royal Canine HP or similar.

Prednisone or prednisolone 2 mg/kg bid x 3-5 days then 2 mg/kg sid. **Chlorambucil** in refractive severe IBD/alimentary lymphoma cases (monitor cbc for rare bone marrow suppression) 4 mg/m² Q 24-48 hours.

WEIGHT

15.2

Cobalamine (B12) 250-1500 ug/dog weekly x 6 weeks.

Calcium supplementation if necessary.

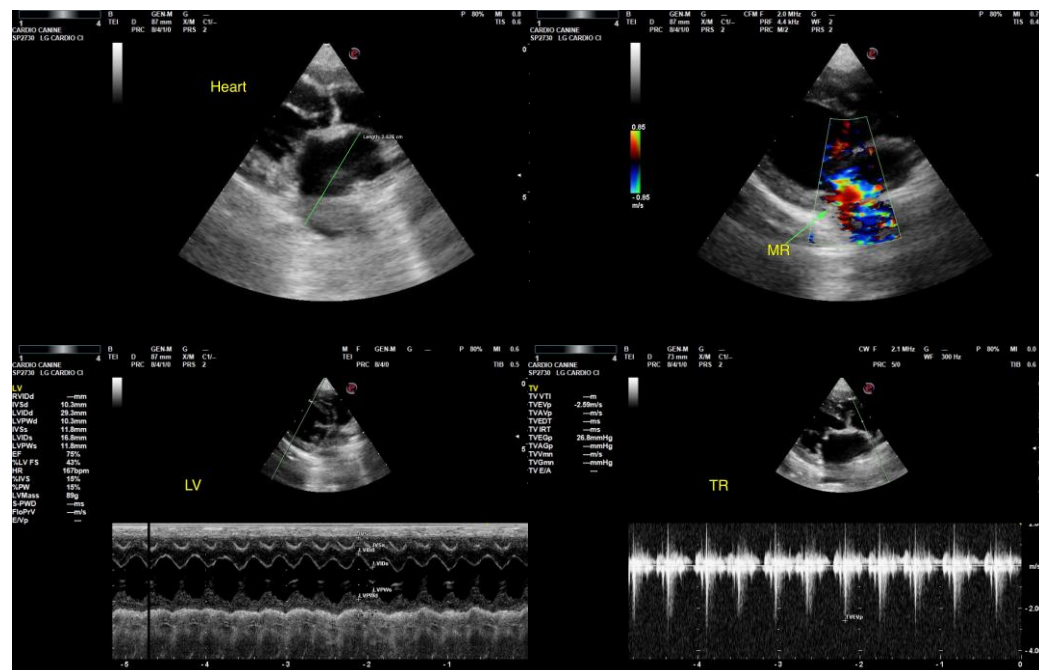
INTERPRETED BY

R. McKenzie Daniel,
DVM, DABVP
(Canine and Feline)

Aspirin 0.5-1 mg/kg/day or **Clopidrel** (Plavix) 1-5 mg/kg/day.

IMAGING PERFORMED BY

Rebekah Jakum, CVT
ARDMS/RVT



HOSPITAL NAME

New Britain VC

REFERRING VET

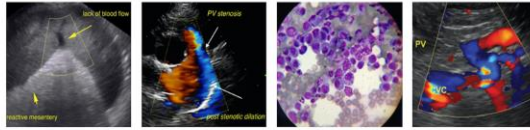
Dr. Bandekar

INVOICE

14353

DATE

7/21/22



PATIENT

Sophie Amin

SPECIES

Canine

BREED

Poodle Mix

SEX

FS

AGE

2013

WEIGHT

15.2

INTERPRETED BY

R. McKenzie Daniel,
DVM, DABVP
(Canine and Feline)

IMAGING PERFORMED BY

Rebekah Jakum, CVT
ARDMS/RVT

HOSPITAL NAME

New Britain VC

REFERRING VET

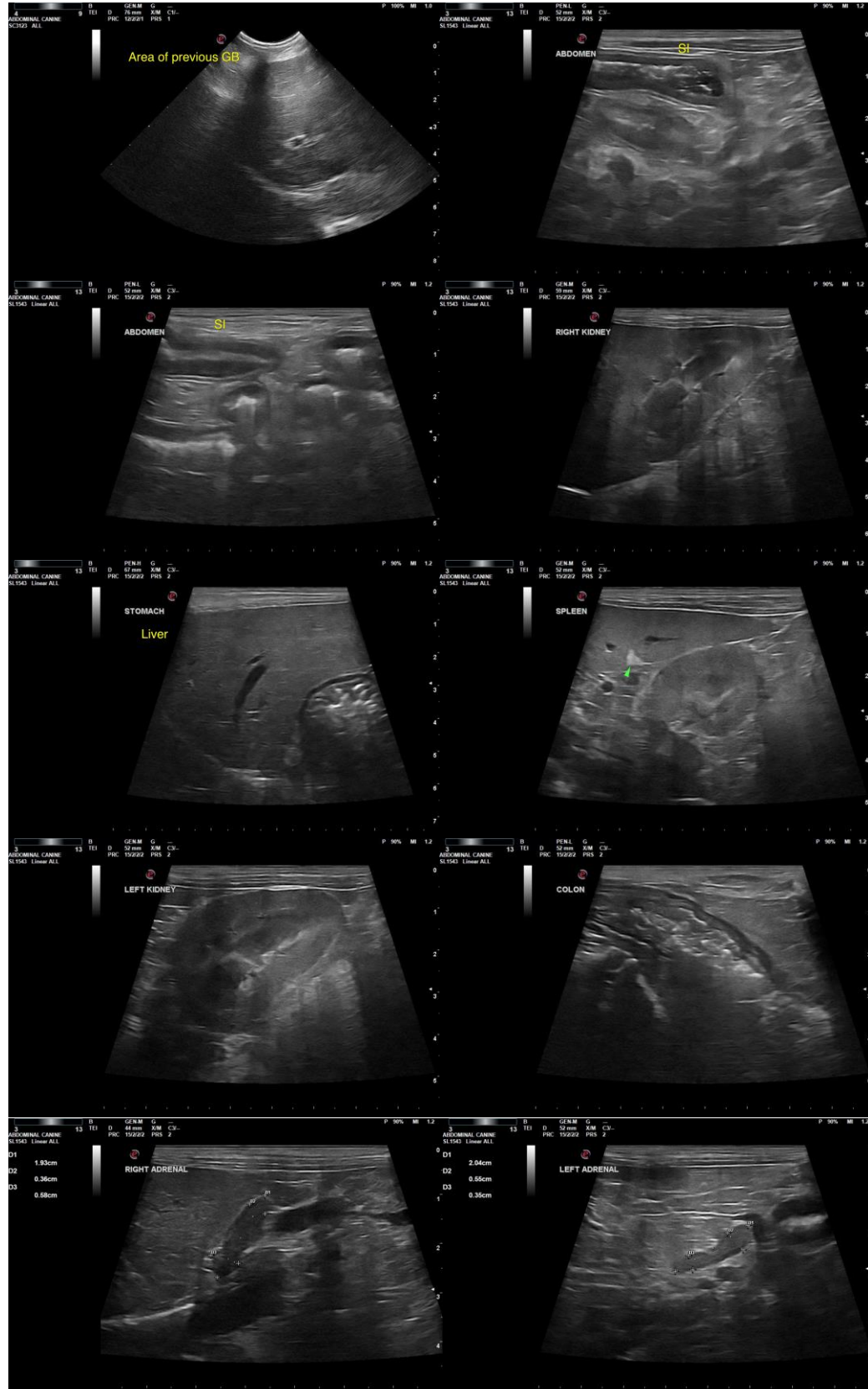Dr. Bandekar

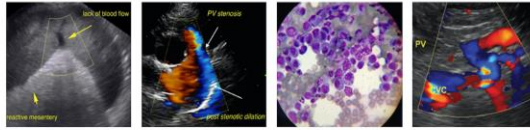
INVOICE

14353

DATE

7/21/22





PATIENT

Sophie Amin

SPECIES

Canine

BREED

Poodle Mix

SEX

FS

AGE

2013

WEIGHT

15.2

INTERPRETED BY

R. McKenzie Daniel,
DVM, DABVP
(Canine and Feline)

**IMAGING
PERFORMED BY**

Rebekah Jakum, CVT
ARDMS/RVT

HOSPITAL NAME

New Britain VC

REFERRING VET

Dr. Bandekar

INVOICE

14353

DATE

7/21/22

The information and recommendations provided are based on the images presented by the referring veterinarian/sonographer. No evaluation can be communicated regarding pathology that was not visible in the image/video clips provided.

Thank you for this referral. If the clinical or image interpretation does not parallel your findings or if I can be of any further assistance, please contact me.

R. McKenzie Daniel, DVM, DABVP (Canine/Feline Practice)
mac.daniel@sonopath.com