



PATIENT

Aegis Shetty

SPECIES

Feline

BREED

Siberian

SEX

Male/Neutered

AGE

1

WEIGHT

11.1

INTERPRETED BY

R. McKenzie Daniel,
DVM, DABVP
(Canine and Feline)

IMAGING PERFORMED BY

Dr. Sharkaway

HOSPITAL NAME

Kew Gardens AH

REFERRING VET

Dr. Sharkaway

INVOICE

17307

DATE

7/19/23

PRESENTING CLINICAL SIGNS

Anorexia vomiting for 2 days Matted hair

Abnormal PE/Chem/CBC/UA Results: VHS 8.26 FIV/FelLV–negative Heart murmur grade 2 out of 6
Blood work–within normal limits

ULTRASONOGRAPHIC EXAMINATION OF THE HEART

FELINE CARDIAC PARAMETERS	BODY WEIGHT (kg)	HR (BPM)	IVSd (cm)	LVIDd (cm)	LVWd (cm)	FS (%)	EF (%)
NORMAL PARAMETER	-----	150-240	0.3-0.6	1.0-2.1	0.25-0.6	35-67	80-100
PATIENT		NM	0.45	1.3	0.50	50	85
FELINE CARDIAC PARAMETERS	LA/AO (Boon)	LA/AO HEART BASE (Sisson)	LA 2D 4-chamber long axis AS to FW (Sisson) (cm)	LVOT VEL. (m/s)	RVOT VEL. (m/s)	IVRT (m/)	
NORMAL PARAMETER	<1.5	0.88-1.79	0.7-1.7	<1.6	<1.3	40-60	
PATIENT		1.2	1.2	NM	1.7	NM	
Adapted from June Boon, Veterinary Echocardiography, 1998 Sisson D et al. JVIM 1991; 5: 232, Jacobs et al. Am J Vet Res 1985; 46:1705							

Cardiac Presentation

The echocardiogram in this patient demonstrated normal **left atrial** size based on 3 separate LA measurements. The cranial and caudal **mitral** valve leaflets presented normal linear structure and kinetics. The **left ventricle** presented normal thicknesses with linear contour and was not dilated nor restricted. The **myocardium** presented normal echogenicity without subjective evidence of significant fibrotic or ischemic disease. **Contractility** of the ventricular walls was adequate and in normal range for this patient evidenced by the fractional shortening measurement and subjective evaluation of the different regions and angles of the myocardium. The **left ventricular outflow** tract demonstrated normal laminar flow and subjective structural integrity. The **right atrium** and auricle revealed normal size, structure and content. No evidence of masses was noted or chamber overload. **Tricuspid** valvular assessment demonstrated adequate linear morphology and kinetics. The **right ventricle** was of normal size (1/3 diameter of LV), chordae structure, myocardial echogenicity and thickness. **Pulmonic** tract assessment revealed normal valve structure, laminar flow, and diameter (approx.1:1 pa/ao ratio). Borderline increased measured RVOT velocity was noted. No visible **pericardial** or free pleura fluid was noted or extra cardiac pathology in the visible planes. The cranial **mediastinum and pericardial regions** were free of masses in the visible window.



PATIENT

Aegis Shetty

SPECIES

Feline

BREED

Siberian

SEX

Male/Neutered

AGE

1

WEIGHT

11.1

INTERPRETED BY

R. McKenzie Daniel,
DVM, DABVP
(Canine and Feline)

IMAGING PERFORMED BY

Dr. Sharkaway

HOSPITAL NAME

Kew Gardens AH

REFERRING VET

Dr. Sharkaway

INVOICE

17307

DATE

7/19/23

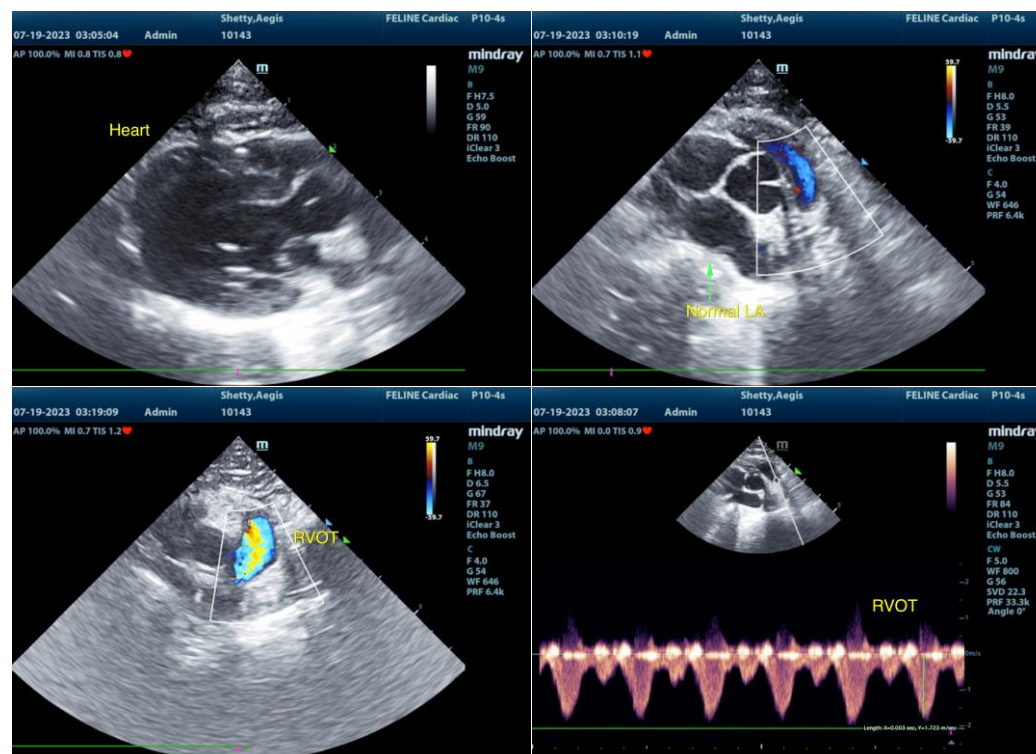
ULTRASONOGRAPHIC FINDINGS

- Normal echocardiogram

INTERPRETATION OF THE FINDINGS & FURTHER RECOMMENDATIONS

No sonographic evidence of structural or functional cardiomyopathy, including no clinical issues such as HCM criteria, LV systolic dysfunction, left or right heart chamber enlargement, significant valvular insufficiencies, or clinical pulmonary hypertension. A definitive cause of the murmur was not obvious. Potential murmur associated with borderline increased measured RVOT velocity is possible, which is essentially a physiologic / flow murmur. Regardless, the hemodynamic effects of the murmur appear to be minimal, given no evidence of left or right heart chamber enlargement.

There is no indication for cardiac medications. Conservative monitoring of the murmur is recommended with recheck echocardiogram suggested in 8-12 months, sooner if clinical signs consistent with heart disease arise, or if murmur intensity increases.



The information and recommendations provided are based on the images presented by the referring veterinarian/sonographer. No evaluation can be communicated regarding pathology that was not visible in the image/video clips provided.

Thank you for this referral. If the clinical or image interpretation does not parallel your findings or if I can be of any further assistance, please contact me.

R. McKenzie Daniel, DVM, DABVP (Canine/Feline Practice)
info@sonopath.com