SonoPath
Clinical Sonography & Telecytology

EDUCATIONAL TELECONSULTATION SERVICES™

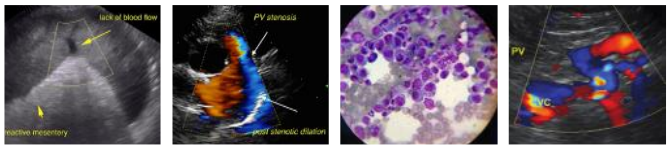

SonoPath.com
1-800-838-4268 info@sonopath.com

PATIENT
Cooper Ditler

SPECIES
Canine

BREED
Labradoodle

SEX
M

AGE
6mo

WEIGHT
18.8kg

INTERPRETED BY
R. McKenzie Daniel, DVM, DABVP (Canine and Feline)

IMAGING PERFORMED BY
Anna Wepprich

HOSPITAL NAME
Wilvet Salem

REFERRING VET
Anna Wepprich

INVOICE
14380ag

DATE
07/18/2023

PRESENTING CLINICAL SIGNS

vomiting this morning, could not keep anything down. Radiographs at rDVM had possible foreign material in pylorus. History of eating toys and defecating toy pieces a few days ago.

Abnormal PE/Chem/CBC/UA Results: ALT 196, ALB 4.0, rest nsf

ULTRASONOGRAPHIC EXAMINATION OF THE ABDOMEN

Urinary System

The urinary bladder, trigone, cystourethral junction, and visible pelvic urethra to a depth of 3 cm exhibited normal thickness and tone. Anechoic urine was present in the lumen with no uroliths or sediment. The ureteral papillae were normal. The ureters were not visible which is normal. No evidence of inflammatory or neoplastic changes were noted.

Normal size and margination were present in the kidneys. A normal 1:3 cortex / medulla ratio and normal corticomedullary definition were maintained. The echogenicity of the cortex was similar to or slightly less than normal liver parenchyma while the medulla echogenicity was hypoechoic to the cortex with no evidence of pelvic dilation. The left kidney measured 6.3 cm in length. The right kidney measured 6.5 cm in length.

The area of the aortic trifurcation was free of pathology.

Adrenal Glands

The left adrenal gland was uniform in size and contour with a uniformly hypoechoic parenchyma. The left adrenal gland measured 0.45 cm width at the caudal pole and 0.5 cm width at the cranial pole. The right adrenal gland was uniform in size and contour with a uniformly hypoechoic parenchyma. The right adrenal gland measured 0.54 cm width at the caudal pole and 0.60 cm width at the cranial pole.

Spleen

The spleen exhibited a finely textured and homogenous parenchyma which was hyperechoic to the liver and renal cortical parenchyma. The capsule was smooth and regular without apparent expansion. The splenic vasculature at the hilus was normal in volume with no evidence of congestion or thrombosis. Acute to chronic inflammatory, neoplastic, or benign parenchyma changes were not noted.

Liver/Gallbladder

The liver was subjectively normal in size, structure, and contour. The liver parenchyma was uniform and hypoechoic to the spleen with a mild coarse echotexture. Normal vascular volume. The hepatic and portal vasculature were normal in appearance without signs of congestion. The gallbladder was non-distended in size with thin walls and primarily anechoic luminal content. The cystic and common bile ducts were normal.

Gastrointestinal

The stomach presented intact mildly prominent wall layering with a normal wall layer ratio. The lumen of the stomach contained mild retained anechoic fluid with no signs of ileus, obstruction or foreign material.

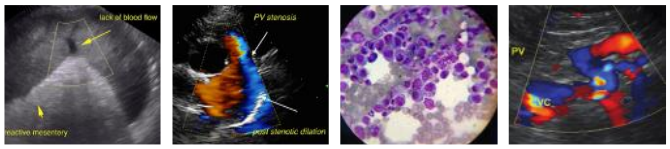

SonoPath.com
1-800-838-4268 info@sonopath.com

PATIENT
Cooper Ditler

SPECIES
Canine

BREED
Labradoodle

SEX
M

AGE
6mo

WEIGHT
18.8kg

INTERPRETED BY
R. McKenzie Daniel, DVM, DABVP (Canine and Feline)

IMAGING PERFORMED BY
Anna Wepprich

HOSPITAL NAME
Wilvet Salem

REFERRING VET
Anna Wepprich

INVOICE
14380ag

DATE
07/18/2023

The small intestine presented intact wall layering with 1:3 muscularis/mucosa ratio. The lumen of the small intestine was empty with mild upper to mid duodenal luminal fluid.

Normal visible colon wall layers were present with apparent formed feces in lumen.

Pancreas

The parenchyma of the left limb, body and right limb of the pancreas presented isoechoic to the adjacent omental fat. A normal curvilinear capsule contour of the pancreas was present. The visible pancreatic duct was normal. No signs of active inflammation or neoplastic disease was evident.

Free Abdomen

No omental masses, overt lymphadenopathy or peritoneal effusion was present.

ULTRASONOGRAPHIC FINDINGS

- Sonographically unremarkable GI tract with mild retained gastroduodenal fluid- no evidence of GI foreign body or mechanical obstruction.

INTERPRETATION OF THE FINDINGS & FURTHER RECOMMENDATIONS

The upper GI tract is suggestive of mild gastroduodenitis and mild metabolic/functional gastroduodenal stasis. No overt indication for immediate surgical intervention without evidence of mechanical obstruction or GI foreign material. Supportive care for gastroduodenitis should prove beneficial.

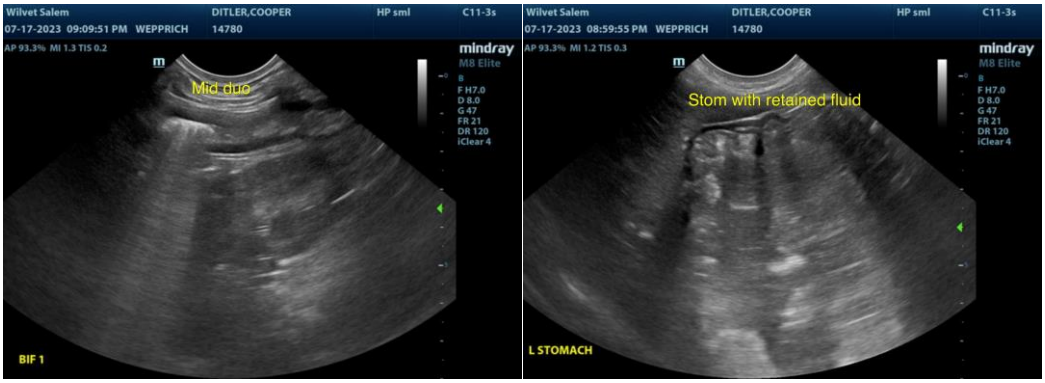

SonoPath

Clinical Sonography & Telecytology

EDUCATIONAL TELECONSULTATION SERVICES™

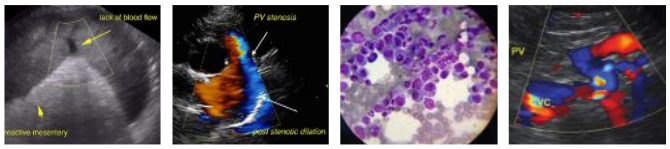

SonoPath.com™
1-800-838-4268 info@sonopath.com

PATIENT

Cooper Ditler

SPECIES

Canine

BREED

Labradoodle

SEX

M

AGE

6mo

WEIGHT

18.8kg

INTERPRETED BY

R. McKenzie Daniel, DVM, DABVP (Canine and Feline)

IMAGING PERFORMED BY

Anna Wepprich

HOSPITAL NAME

Wilvet Salem

REFERRING VET

Anna Wepprich

INVOICE

14380ag

DATE

07/18/2023

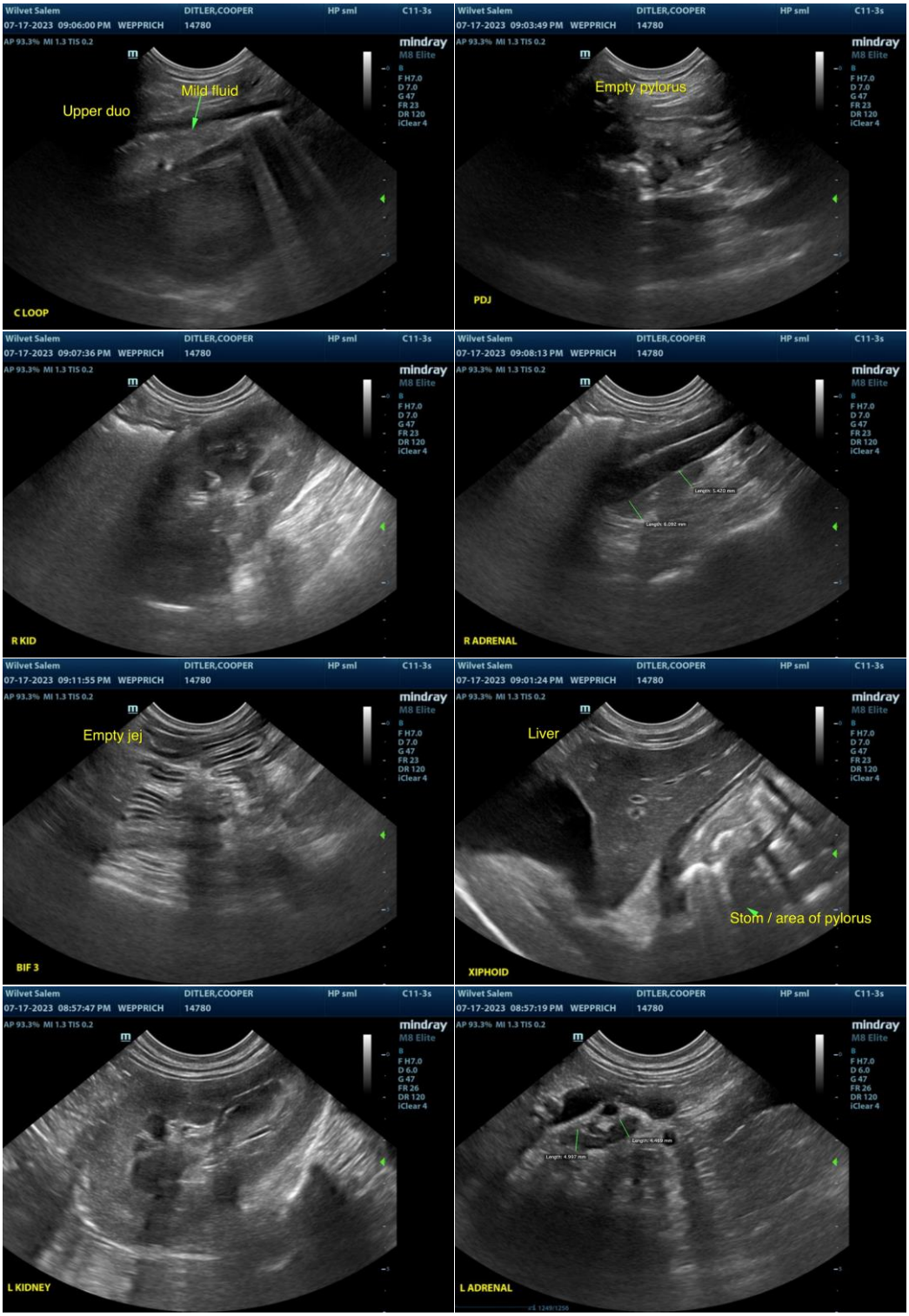

SonoPath
Clinical Sonography & Telecytology

EDUCATIONAL TELECONSULTATION SERVICES™

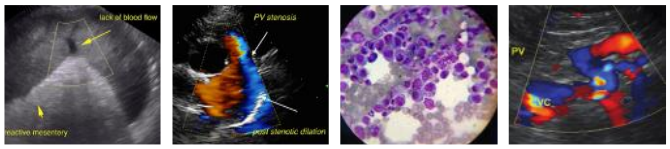

SonoPath.com
1-800-838-4268 info@sonopath.com

PATIENT

Cooper Ditler

SPECIES

Canine

BREED

Labradoodle

SEX

M

AGE

6mo

WEIGHT

18.8kg

INTERPRETED BY

R. McKenzie Daniel, DVM, DABVP (Canine and Feline)

IMAGING PERFORMED BY

Anna Wepprich

HOSPITAL NAME

Wilvet Salem

REFERRING VET

Anna Wepprich

INVOICE

14380ag

DATE

07/18/2023

The information and recommendations provided are based on the images presented by the referring veterinarian/sonographer. No evaluation can be communicated regarding pathology that was not visible in the image/video clips provided.

Thank you for this referral. If the clinical or image interpretation does not parallel your findings or if I can be of any further assistance, please contact me.

R. McKenzie Daniel, DVM, DABVP (Canine/Feline Practice)
info@sonopath.com