


PATIENT

Johnny Spearman

SPECIES

Feline

BREED

DSH

SEX

MN

AGE

10yr

WEIGHT

15.9lb

INTERPRETED BY

 R. McKenzie Daniel,
 DVM, DABVP
 (Canine and Feline)

IMAGING PERFORMED BY

Meredith Swart

HOSPITAL NAME

 Swart veterinary
 Imaging

REFERRING VET

Meredith Swart

INVOICE

14379ag

DATE

07/17/2023

PRESENTING CLINICAL SIGNS

Patient in need of dental surgery. No auscultated murmur. BNP slightly elevated.

Abnormal PE/Chem/CBC/UA Results: WNL other than BNP just slightly elevated

ULTRASONOGRAPHIC EXAMINATION OF THE HEART

FELINE CARDIAC PARAMETERS	BODY WEIGHT (kg)	HR (BPM)	IVSd (cm)	LVIDd (cm)	LVWd (cm)	FS (%)	EF (%)
NORMAL PARAMETER	-----	150-240	0.3-0.6	1.0-2.1	0.25-0.6	35-67	80-100
PATIENT		NM	0.54	1.2	0.51	59	86
FELINE CARDIAC PARAMETERS	LA/AO (Boon)	LA/AO HEART BASE (Sisson)	LA 2D 4-chamber long axis AS to FW (Sisson) (cm)	LVOT VEL. (m/s)	RVOT VEL. (m/s)	IVRT (m/)	
NORMAL PARAMETER	<1.5	0.88-1.79	0.7-1.7	<1.6	<1.3	40-60	
PATIENT	1.4	1.3	1.3	1.1	0.89		
Adapted from June Boon, Veterinary Echocardiography, 1998							
Sisson D et al. JVIM 1991; 5: 232, Jacobs et al. Am J Vet Res 1985; 46:1705							

Cardiac Presentation

The echocardiogram in this patient demonstrated normal left atrial size based on 3 separate LA measurements. The cranial and caudal mitral valve leaflets presented normal linear structure and kinetics. No overt MR present on Doppler. The left ventricle presented normal thicknesses with linear contour and was not dilated nor restricted. The myocardium presented normal echogenicity without subjective evidence of significant fibrotic or ischemic disease. The contractility of the ventricular walls was adequate and in normal range for this patient evidenced by the fractional shortening measurement and subjective evaluation of the different regions and angles of the myocardium. The left ventricular outflow tract demonstrated normal laminar flow and subjective structural integrity. Normal measured LVOT velocity was present. The right atrium and auricle revealed normal size, structure and content. No evidence of masses was noted or chamber overload. Tricuspid valvular assessment demonstrated adequate linear morphology and kinetics. No overt TR present on Doppler. The right ventricle was of normal size (1/3 diameter of LV), chordae structure, myocardial echogenicity and thickness. Pulmonic tract assessment revealed normal valve structure, laminar flow, and diameter (approx. 1:1 pa/ao ratio). Normal measured RVOT velocity was present. No visible pericardial or free pleura fluid was noted or extra cardiac pathology in the visible planes. The cranial mediastinum and pericardial regions were free of masses in the visible window.

ULTRASONOGRAPHIC FINDINGS

- Normal echocardiogram.



PATIENT

Johnny Spearman

SPECIES

Feline

BREED

DSH

SEX

MN

AGE

10yr

WEIGHT

15.9lb

INTERPRETED BY

R. McKenzie Daniel,
DVM, DABVP
(Canine and Feline)

IMAGING PERFORMED BY

Meredith Swart

HOSPITAL NAME

Swart veterinary
Imaging

REFERRING VET

Meredith Swart

INVOICE

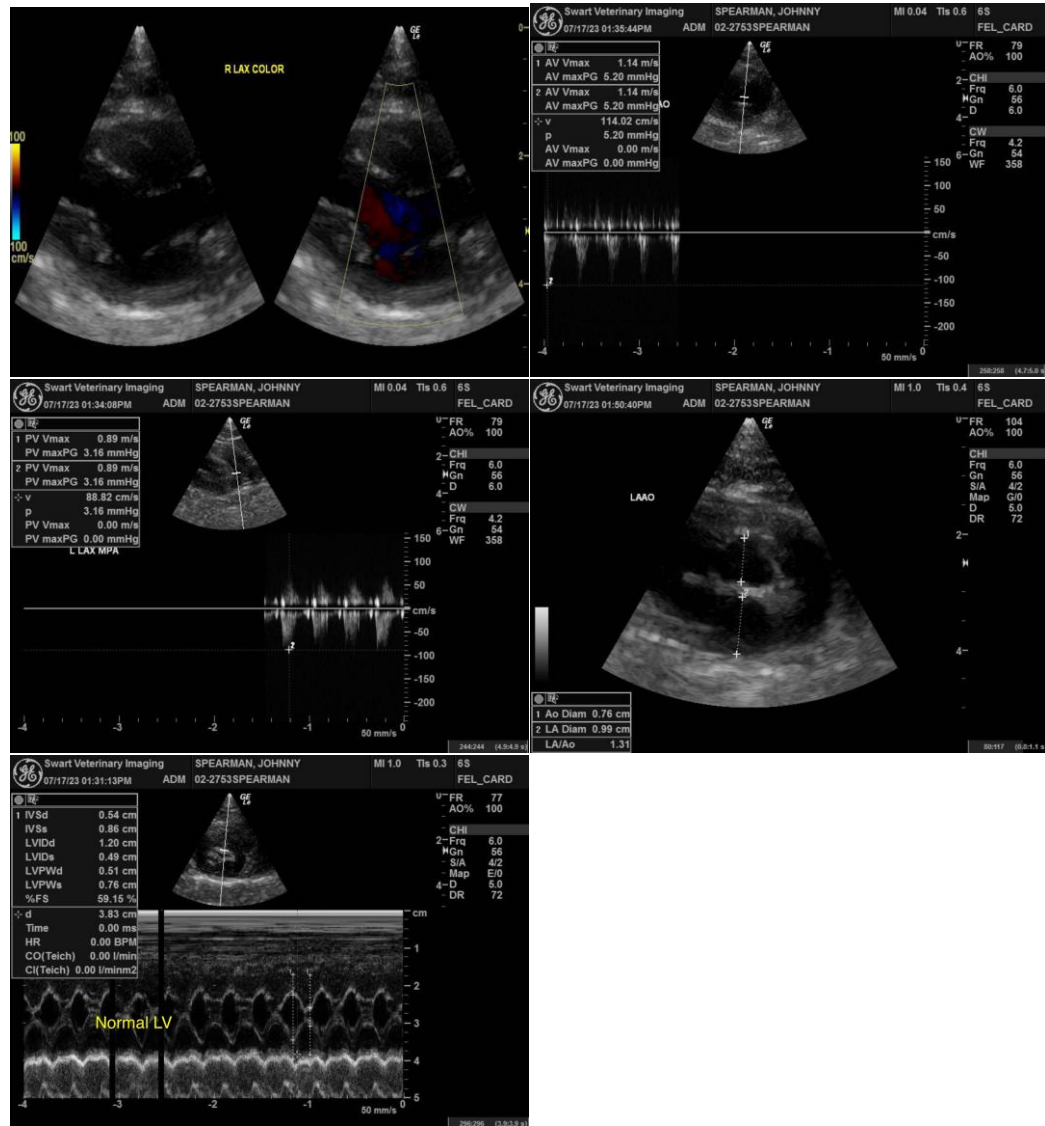
14379ag

DATE

07/17/2023

INTERPRETATION OF THE FINDINGS & FURTHER RECOMMENDATIONS

No evidence of structural or functional cardiomyopathy was present in this study including no evidence of clinical issues such as LV systolic dysfunction, clinical pulmonary hypertension, significant valvular insufficiencies or stenotic disease. No anesthetic contraindications.



The information and recommendations provided are based on the images presented by the referring veterinarian/sonographer. No evaluation can be communicated regarding pathology that was not visible in the image/video clips provided.

Thank you for this referral. If the clinical or image interpretation does not parallel your findings or if I can be of any further assistance, please contact me.



PATIENT

Johnny Spearman

R. McKenzie Daniel, DVM, DABVP (Canine/Feline Practice)
info@sonopath.com

SPECIES

Feline

BREED

DSH

SEX

MN

AGE

10yr

WEIGHT

15.9lb

INTERPRETED BY

R. McKenzie Daniel,
DVM, DABVP
(Canine and Feline)

**IMAGING
PERFORMED BY**

Meredith Swart

HOSPITAL NAME

Swart veterinary
Imaging

REFERRING VET

Meredith Swart

INVOICE

14379ag

DATE

07/17/2023